

UDC 591.43:598.112.23

## MORPHOLOGICAL FEATURES OF THE DIGESTIVE TUBE IN SAND LIZARDS, *LACERTA AGILIS* (SAURIA, LACERTIDAE)

M. V. Skrypka<sup>1</sup>, I. I. Panikar<sup>1</sup>, B. P. Kyrychko<sup>2</sup>, O. I. Tul<sup>2</sup>

<sup>1</sup>Odesa State Agrarian University,  
Panteleimonivska st., 13, Odesa, 65012 Ukraine  
E-mail: marina.skripka.70@ukr.net

<sup>2</sup>Poltava State Agrarian Academy,  
G. Skovoroda st., 1/3, Poltava, 36003 Ukraine  
E-mail: oleksandratul@ukr.net

M. V. Skrypka (<https://orcid.org/0000-0002-9815-0562>)  
I. I. Panikar (<https://orcid.org/0000-0001-9071-3749>)  
B. P. Kyrychko (<https://orcid.org/0000-0003-1463-5501>)  
O. I. Tul (<https://orcid.org/0000-0002-2430-1575>)

**Morphological Features of the Digestive Tube in Sand Lizards, *Lacerta agilis* (Sauria, Lacertidae).** Skrypka, M. V., Panikar, I. I., Kyrychko, B. P., Tul, O. I. — The features of the sand lizard (*Lacerta agilis*) digestive tube morphology are presented in the article. It has been found that the sand lizard gastrointestinal tract includes oral cavity, esophagus, stomach, small intestine, large intestine and cloaca. The mucous membrane of the oral cavity is lined with non-keratinized stratified squamous epithelium. The esophagus is represented by an extensible canal; the distinction between the esophagus and the stomach is not expressed. The availability of a large number of ventricular fossae have stipulated a large area of the gastric mucosa and its cellular structure. The stomach is separated from the duodenum by a well-developed annular fold (pylorus). Villi of the duodenal mucosa are narrow, of different heights, covered with a single layer of columnar epithelium. The jejunum villi are of a more elongated shape, with more goblet cells and fewer crypts, the ileum villi are short. Small clumps of lymphoid cells are observed in the mucous membrane of the small intestine. The mucous membrane of the large intestine is lined with ordinary columnar epithelium containing goblet cells. Lymphoid aggregates are found in the wall of the large intestine. The cecum, as a distinct morphological section of the large intestine, is not presented. Key words: sand lizard, esophagus, stomach, villi, mucous membrane.

## Introduction

The Class Reptilia includes up to 7,500 different species, the most famous of which are turtles, crocodiles, lizards and snakes (Jacobson, 2007). Reptiles have successfully adapted to ecological niches and survived the competition from higher vertebrates such as birds and mammals. This evolution has led to differences in anatomy and physiology of different organ systems of various groups of reptiles. Of all the different systems, the greatest variation can be observed in the gastrointestinal tract (Mitchell, Diaz-Figueroa, 2005).

The reptile's gastrointestinal tract is relatively simple and very similar in structure to mammals. It includes the oral cavity, esophagus, stomach, liver with multiple lobes, gallbladder, pancreas, small intestine, large intestine, and cloaca (Wyneken, 2011). Reptiles have similar feeding responses to other animals commonly for experiments such as: mice, rats, rabbits, and pigs. Therefore, they are suitable models for the study of physiological regulation of the digestive process (Secor, Diamond, 1998).

The sand lizard, *Lacerta agilis* (Linnaeus, 1758) is one of the most common eurytopic species of vertebrates in Eurasian fauna (Shherbak, Ostashko, 1976). It is distributed from southern England, Eastern France and the Northern part of the Balkan Peninsula in the West to Eastern Siberia, northwestern Mongolia and Western China in the East. The Northern border of the range reaches up to 52–61° of the southern latitude. Within the Commonwealth of Independent States, the sand lizard is distributed from Moldova, Ukraine, Belarus, the Baltic States and Russia in the West to the Northern Baikal and southern Transbaikalian in the East, Kazakhstan and the mountains of Central Asia in the South. The whole territory of Ukraine is in the range (Bulakhov et al., 2007).

The works of such scientists as Shherbak, Ostashko, Bulakhov, Gasso, Pakhomov, Zavyalov, Tabachishin, Shlyakhtin, Zinenko, Galitsyn and others are devoted to the study of sand lizard's *L. agilis* distribution, their morphology and biological diversity.

At the same time, it should be noted that morphological features of the gastrointestinal tract in sand lizards *L. agilis* have been studied partially and require further research. There is a need to expand basic knowledge about the species, conduct a thorough anatomical study of its digestive organs for further physiological, pathological and phylogenetic studies.

## Material and methods

At the initial stage of the study, populations of the sand lizard (*Lacerta agilis*) were determined by route census in the territory of the village of Vakulentsy that is located in Podolsky District in the city of Poltava (Skrypka et al., 2016).

The study of morphological features of the sand lizard (*Lacerta agilis*) was carried out in accordance with conventional methods (Zon et al., 2010; Goralskiy et al., 2011). Selected materials were fixed in 10 % neutral buffered formalin with their subsequent washing, carried out specimens' dehydration in the ethanol of increasing concentration, soaked them in chloroform, embedded in paraffin and made paraffin blocks. Histological sections of 3–5 µm thick were made on a luge microtome MC-2. The microscopic structure of organs and tissues was investigated by staining with hematoxylin Karatsu and 0.1% aqueous solution of eosin. Histological sections were examined under a Micromed XS-5520 microscope. Photographs were taken with a Micromed 5.0 Mpx CCD camera.

The examined reptiles were treated in accordance with the Council of Europe Convention for the Protection of Vertebrate Animals used for Experimental and other Scientific Purposes (Strasbourg, 1986) and Directive 2010/63/EU of the European Parliament and of the Council of 22 September 2010.

## Results

As a result of counting the number of lizards by route census, 6 species were counted in the areas inhabited by humans (route length 3.2 km), 12 species were counted in the green belt (route length 4.5 km), and 9 species were counted on the coasts of the River Vorskla (route length 3.8 km). Thus, in the areas inhabited by humans, the density of lizard population was 75 species per 1 square kilometer, in the green belt — 106 species per 1 square kilometer, and on the coasts of the River Vorskla — 95 species. The sex ratio in the population of the given reptile species accounted for about 1 : 1.

The study of the features of the anatomical structure of the sand lizard revealed the largest length of  $177.3 \pm 31.8$  mm and weight of  $12.92 \pm 3.27$  g of individual species. A large mouth is located on the front of the head, slightly above the paired nostrils, behind them are the eyes that have the upper and lower eyelids and a blinking membrane. There are recesses on the lateral surface of the head, which are tightened by the tympanic septum and are part of the ear. There is a cresspool, which has the form of a transverse fissure, on the border between the trunk and tail. Male species have copulative organs that are located at

the base of the tail and are abundantly supplied with blood vessels. These organs protrude through the cloacal opening.

On the lower inner surface of the thighs, there are several large scutes with small yellow tubercles. These are femoral pores, which are better developed in male species.

The gastrointestinal tract of the sand lizard consists of: the oral cavity, esophagus, stomach, small and large intestines, and cloaca (fig. 1, A). Insects belonging to different orders were found in the lumen of the stomach. The oral cavity is noticeably separated from the pharynx, the lips are motionless, the mouth is large, and the secondary palate is not developed. There is a laryngeal fissure, which adjoins the opening of the choanae (internal nasal openings) with a closed mouth. It is located in the deep notch of the back of the tongue's base. The stomach is separated from the duodenum by a well-developed annular fold (pylorus).

The mucous membrane of the oral cavity is covered with stratified squamous non-keratinizing epithelium, into which the ducts of the oral glands (premaxillary, palatine, posterior, sublingual, lingual, maxillary and mandibular) flow into. The oral glands are covered with single-row epithelium. Cubic-shaped epithelial cells are dark and small, and have basally located nuclei and transparent cytoplasm.

Sharp, slightly bent and mostly single-edged teeth are located on the edges of the upper and lower jaws. There are no teeth roots and the teeth are located in one common groove (pleural type of dental system). Such teeth are only suitable for grasping and holding prey, but not for chewing food.

A sand lizard has a muscular and flat tongue, which tapers in front and has a deep notch at the end (fig. 1, B). It is very movable, can protrude quite far from the oral cavity and performs the function of touch. The tongue is covered with flat stratified epithelium. Mucous glands are surrounded by skeletal muscle fibers. The back of the pharynx is pigmented with melanin.

The esophagus opening begins in the back of the oral cavity. The esophagus is a growing tube that is located below the trachea and in front of the chest cavity gradually expanding towards the stomach. The wall of the esophagus, like other parts of the digestive tube, consists of the mucosa, muscle and serosa.

The structural features of the mucous membrane of the esophagus, namely its folding, are determined by the features of eating food, namely swallowing insects whole, almost without preliminary mechanical treatment in the oral cavity. Folds form all layers of the mucous membrane. In the cranial section, the esophagus is covered with a multilayer epithelium, which turns into a cubic one. It is represented by a prismatic epithelium in the

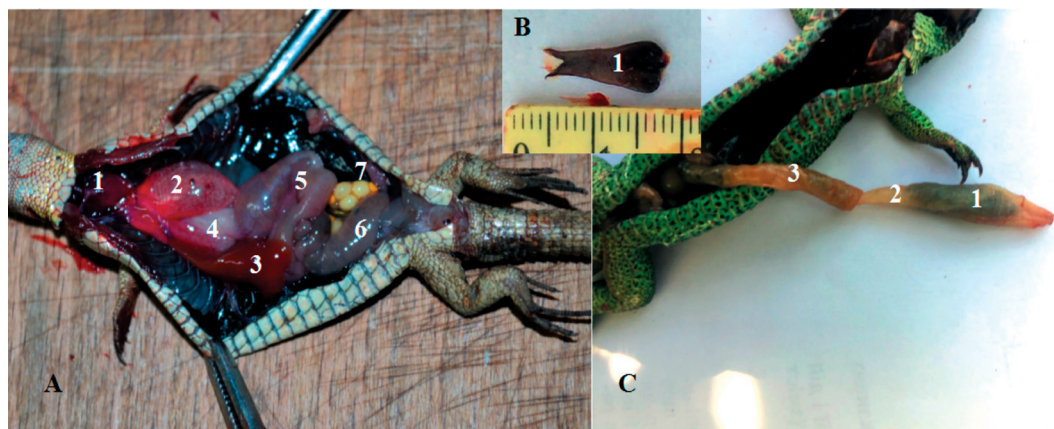


Fig. 1. The topography of internal organs of sand lizard: (A): 1 — heart; 2 — lung; 3 — liver; 4 — stomach; 5 — small intestine; 6 — large intestine; 7 — ovary; (B): 1 — tongue; (C): 1 — stomach; 2 — pylorus; 3 — small intestine.

middle and lower parts. The apical part of the epithelium is covered with a mucous mass, which contains a large amount of proteins and when histological specimens are stained with hematoxylin and eosin, they give a red stain. Secretory functions that are aimed at the production of mucus and, accordingly, the protection of the mucous membrane from mechanical and chemical damage, are performed by goblet cells, which are located between the epithelial cells in large numbers. The cytoplasm of ciliated epithelial cells has eosinophilic granular structure (it is stained with eosin in pink-red color). The nuclei are oval, located on the basal pole of the cell, and basophilic (they are stained with hematoxylin in blue color).

The submucosal base of the mucous membrane consists of connective tissue supplied with blood vessels. The muscular plate is represented by smooth muscle cells oriented along the organ.

The muscle layer of the esophagus wall consists of smooth muscle cells aggregated in bundles of muscle fibers. According to the location of the fibers, the muscle layer is divided into external longitudinal and internal circular layers. In the cervical part, the outer membrane of the esophagus wall is represented by adventitia (loose connective tissue), and in the abdominothoracic — by the serosa (loose connective tissue, externally covered with flat cells — mesothelium).

The stomach of a sand lizard has an elongated saccular shape. Its average weight is  $0.29 \pm 0.23$  g, and length is  $26.5 \pm 6.2$  mm. The organ has a bulge that is more pronounced on the left and a little curvature on the right. There is no clear differentiation into sections; a wide part of the stomach can be attributed to the fundus, and a narrow part — to the pyloric part. The stomach narrows to a thick muscular sphincter or pyloric valve. The cavity of the stomach is completely camerated by a whole system of large and small folds, but separation into sections, as such, was not found.

Wavy longitudinal folds represent the mucous membrane of the stomach. It is thicker than the mucous membrane of the wall of the esophagus due to the presence of gastric glands. The epithelium consists of simple columnar cells with pronounced polarity, the oval nucleus is located in the basal part, and the microvilli are located on the surface of the apical part. The nuclei are stained with hematoxylin in blue, and the cytoplasm with eosin in red.

A structural feature of the gastric mucosa is a large number of ventricular fossae, into which the gastric glands open. The glands are located directly in their own plate of the mucous membrane. As a consequence, the mucous membrane acquires a cellular structure. Within the wall of one gland, one can trace the transition of the cylindrical epithelium into the cubic one, and the cubic epithelium into the squamous epithelium, large “cells” are closer to the lumen of the stomach. When stained with hematoxylin and eosin, epithelial cells acquire a gray-blue cytoplasm (fig. 2). Smaller cells with a centrally located nucleus are also found in the gastric glands. A distinctive feature of such cells is eosinophilic stained granularity of the cytoplasm.

The submucosa is composed of loose connective tissue. A narrow submucosal base is followed by a muscle plate of the mucous membrane, which consists of two equally developed layers. The inner layer has a circular arrangement, and the outer one is longitudinal. The muscular membrane of the anterior third of the stomach is formed of external longitudinal and internal circular layers. The inner circular muscle layer of the stomach muscular system is thicker than in the esophagus. The serosa is covered with a single-row flat epithelium.

The stomach is separated from the duodenum by a well-developed annular fold (pylorus) (fig. 1, C). The pylorus is covered by a well-developed muscular sphincter, which is noticeably distinguished in the lumen of the duodenum.

On average, a sand lizard has the intestines that weigh  $0.56 \pm 0.36$  g and are  $89 \pm 9.66$  mm long. The small intestine looks like a narrow tube. The mucous membrane of the small intestine is pale pink, collected in parallel wavy folds. The serosa is lightly pink.

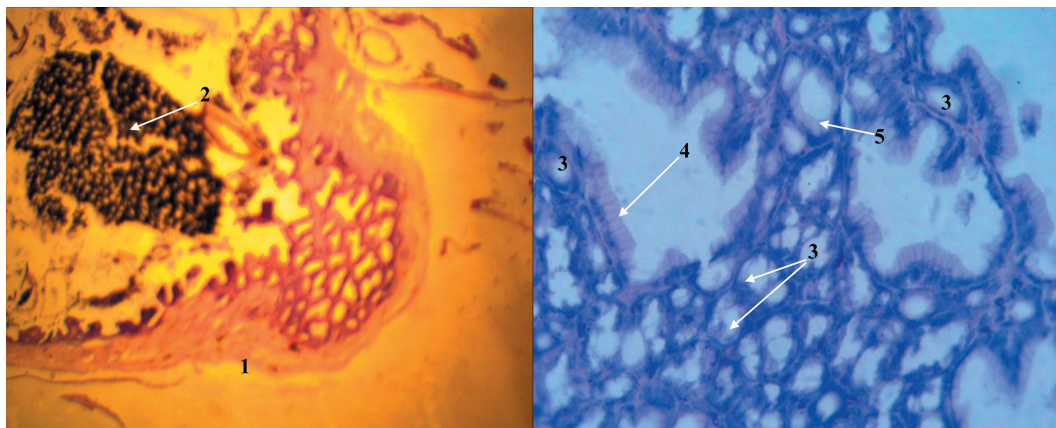


Fig. 2. Fragment of microscopic structure of stomach wall of sand lizard: 1 — stomach wall; 2 — stomach contents; 3 — gastric glands; 4 — columnar epithelium; 5 — cubic epithelium. Hematoxylin and eosin.  $\times 100$ ; 400.

The area behind the pyloric sphincter can be considered as the duodenum, into which the pancreas and common bile ducts enter. The ileum has less folds of the mucous membrane of the duodenum. The ileum opens into the colon with a narrow opening protected by a muscular sphincter that protrudes into the colon, called ileocolonic sphincter. Individual sections of the intestine are difficult to differentiate at the macroscopic level.

A short, wide thick-walled and C-shaped curved tube represents the large intestine. The mucous membrane of the colon has longitudinal, thick folds. The rectum is thin-walled and wide. It lies to the right of the midline in the back of the abdominal cavity, opens into the cloaca, which leads to the external cloacal opening. The cloaca opens outward with a narrow transverse gap that lies on the ventral side at the base of the tail.

The mucous membrane of the small intestine is covered with a single-layer cylindrical epithelium along its entire length. The cytoplasm of epithelial cells is eosinophilic, and the nuclei are basophilic. Numerous fossae of the epithelium (the so-called crypts) are formed in the mucous membrane into its own plate. The walls of the crypts are covered with columnar epithelial cells.

At the microscopic level, the structure of the villi of the mucous membrane of different parts of the small intestine has a number of differences. Thus, the villi of the duodenal mucosa are narrow, of different heights, and of curved cylindrical shapes (fig. 3). Epithelial

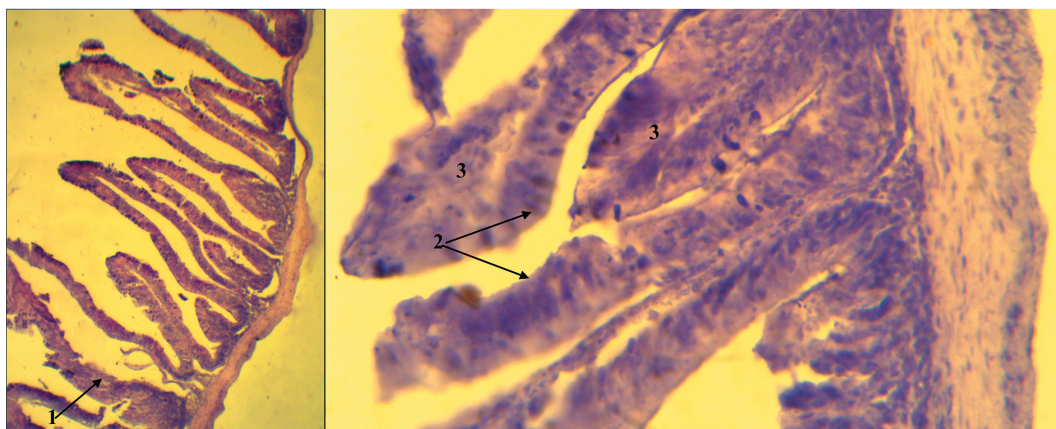


Fig. 3. Fragment of microscopic structure of duodenum of sand lizard: 1 — wall of villus; 2 — epithelial cells; 3 — stroma of villus. Hematoxylin and eosin.  $\times 100$ ; 400.

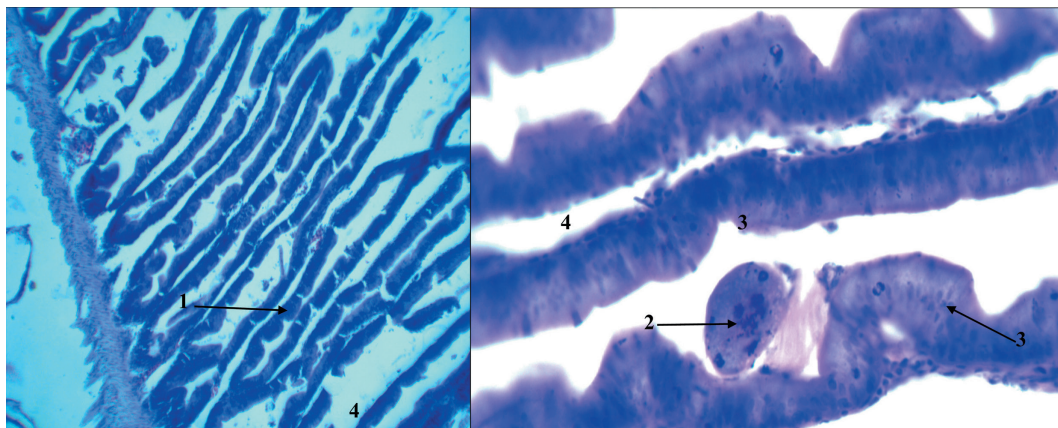


Fig. 4. Fragment of microscopic structure of jejunum of sand lizard: 1 — wall of villus; 2 — fragment of nutrition between two villi; 3 — epithelial cells; 4 — stroma of villus. Hematoxylin and eosin.  $\times 100$ ; 400.

cells are prismatic, nuclei are located on the apical part of the cells. Reddish brown inclusions are visible on the apical part of the villi in the cytoplasm.

In the jejunum, the villi are more elongated in comparison with the duodenal villi. There are more goblet cells and fewer crypts (fig. 4).

The muscular plate of the mucous membrane consists of two continuous and rather equal layers. The submucosa is narrow and formed by connective tissue, which is rich in blood vessels and lymph spaces.

The muscular membrane is formed from the external longitudinal and internal circular muscle layer throughout the intestine.

The jejunum passes into the ileum, where the villi are shorter, the epithelium is prismatic, and goblet cells are located between epithelial cells. Small concentrations of lymphoid cells can be observed in the mucous membrane of the small intestine.

The mucous membrane of the colon is covered with a simple columnar epithelium containing rounded goblet cells secreting mucin. An increase in the number of endocrine cells in the caudal direction is typical for the epithelium of the colon. Lymphoid aggregates are found in the wall of the colon and occupy the entire thickness of the mucous membrane in separate areas. The plate is well-developed between the fossae. The submucosa is abundantly supplied with blood vessels,  $ca1/3$  pillarries, the muscular membrane is less developed (fig. 5).

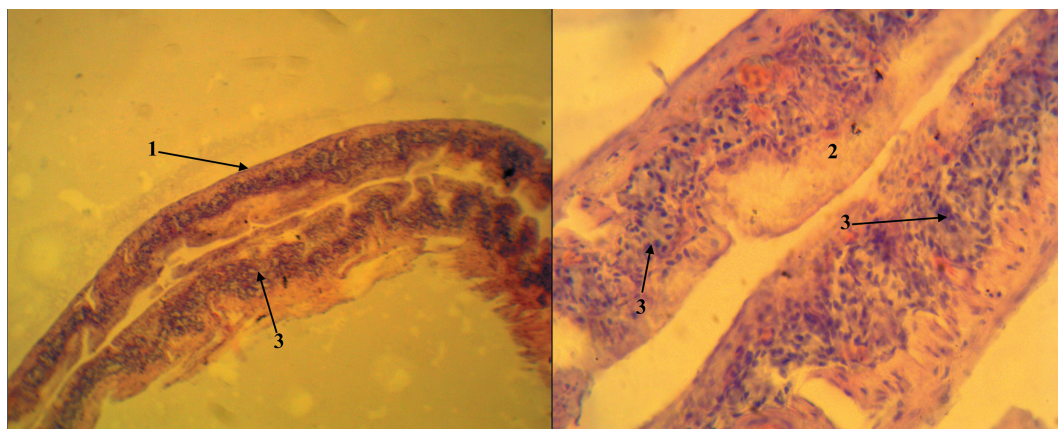


Fig. 5. Fragment of microscopic structure of large intestine of sand lizard: 1 — intestine wall; 2 — epithelial cells; 3 — lymphoid formations. Hematoxylin and eosin.  $\times 100$ ; 400.

Coprodaeum is the closest to cloaca, feces from the rectum enter it. Urodeum is the middle section of cloaca, the ureters, the bladder opening (urethra), the ducts of the sex glands (oviducts and semiducts) flow into it. Proctodeum is the final section of cloaca. Feces and urine, as well as products of the sex glands, are formed in it before excretion. Coprodaeum and urodeum are covered with simple cubic epithelium containing goblet cells. The proctodeum and anus are covered with non-keratinized stratified squamous epithelium. Glands are located in the cloaca.

## Discussion

A sand lizard, *Lacerta agilis* does not have an evident segregation between the esophagus and stomach. This morphological feature of the digestive tube in other species of carnivorous lizards and snakes is indicated by a number of scientists (Rodrigues Sartori et al., 2011; El-Bakry et al., 2012; Abdeen et al., 2013; Jegede et al., 2015; Srichairat et al., 2018). It is suggested that the absence of such a narrowing between the esophagus and stomach, as well as the presence of folds in the mucous membrane of the esophagus, facilitate the swallowing and ingestion of a large bolus of food (insects) without preliminary mechanical processing. It also facilitates the ingestion of mammals for larger representatives of reptiles (Lukina, 1976; Jacobson, 2007; Rodrigues Sartori et al., 2011; El-Bakry et al., 2012; Abdeen et al., 2013; Jegede et al., 2015; Srichairat et al., 2018).

It should be noted that sand lizards do not have the cecum as a distinct morphological section of the large intestine. Perhaps a carnivorous lizard, which includes the species under study, does not need the cecum, since it plays a role in the fermentation of food (fiber breakdown), and with *Lacerta agilis* nutrition type this process is unnecessary.

According to D. B. Vasil'ev, all herbivorous lizards have enlarged colon that is divided into chambers using lunate and circular septa. Circular septa have a sphincter and form a complete septum in the intestinal lumen, overlapping it by 61–97%. Semilunar septa do not have a sphincter and overlap the lumen by 9–70%. The main function of this modification is to slow down the peristaltic flow and create conditions for colonization by intestinal commensals (Vasil'ev, 2005).

At the same time, histochemical examination of the duodenum in 33 species of lizards (including the sand lizard) showed that there is no strong correlation between the nature of nutrition and the histostructure (Gabe, Girons, 1972).

Hence, this phenomenon requires a detailed study using histological, histochemical and colorimetric research methods.

## Conclusions

The structural features of the mucous membrane of the esophagus, namely its folding and the absence of the evident segregation between the esophagus and stomach, are determined by the features of eating food, namely swallowing insects whole, almost without preliminary mechanical treatment in the oral cavity. Secretory functions that are aimed at the production of mucus and, accordingly, the protection of the mucous membrane from mechanical and chemical damage, are performed by goblet cells.

A large number of ventricular fossae determines a large area of the mucous membrane and its cellular structure. Within the wall of one gland, one can trace the transition of the cylindrical epithelium into the cubic one, and the cubic epithelium into the squamous epithelium, large “cells” are closer to the lumen of the stomach. The stomach is separated from the duodenum by a well-developed annular fold (pylorus). The pylorus is covered by a well-developed muscular sphincter.

The mucous membrane of the small intestine is covered with a single-layer cylindrical epithelium along its entire length. Numerous crypts are formed in the mucous membrane. The villi of the duodenal mucosa are narrow, of different heights, and of curved cylindrical shapes.

In the jejunum, the villi are more elongated in comparison with the duodenal villi. There are more goblet cells and fewer crypts. The villi of the ileum are short. Small concentrations of lymphoid cells can be observed in the mucous membrane of the small intestine.

The mucous membrane of the colon is covered with a simple columnar epithelium containing rounded goblet cells secreting mucin. An increase in the number of endocrine cells in the caudal direction is typical for the epithelium of the colon. Lymphoid aggregates are found in the wall of the colon and occupy the entire thickness of the mucous membrane in separate areas. There is no cecum as a distinct morphological section of the large intestine.

## References

- Abdeen, A. M., Mostafa, N. A., Abo-Eleneen, R. E., Elsadany, D. A. 2013. Anatomical studies on the alimentary tract of the Egyptian typhlopoid snake *Rhamphotyphlops Braminus*. *Journal of American Science*, **9** (5), 504–517.
- Bulakhov, V. L., Gasso, V. Y., Pakhomov, A. Ye. 2007. *Biological diversity of Ukraine. The Dnipropetrovsk region. Amphibians and reptiles (Amphibia et Reptilia)*. Monography, Dnipropetr. Nat. Univ. Press, Dnipropetrovsk, 1–420 [In Ukrainian].
- El-Bakry, A. M., Abdeen, A. M., Abo-Eleneen, R. E. 2012. Anatomical and morphometrical study of the alimentary canal of the lizard *Scincus scincus* and the snake *Natrix tessellata*. *Life Science Journal*, **9** (4), 1010–1022.
- Gabe, M., Saint Girons, H. 1972. Relation between the systematic position of saurians and the histochemical characteristics of their duodenal calciform cells. *Bulletin biologique de la France et de la Belgique*, **106** (2), 81–90.
- Galitsyn, D. I. 2014. Sand lizard (*Lacerta agilis* L.) nutrition ecology in the Middle Urals populations. *Izvestia of Samara Scientific Center of the Russian Academy of Sciences*, **16**, 5 (1), 413–417 [In Russian].
- Goralskiy, L. P., Khomich, V. T., Kononskiy, O. I. 2011. *The basis of the histological technic and morphofunctional methods of dosage in the rate and under the pathology: study guide, publ. 2nd*. Polissya, Zhytomyr, 1–288 [In Ukrainian].
- Jacobson, E. R. 2007. Overview of reptile biology, anatomy, and histology. In: Jacobson, E. R. *Infectious diseases and pathology of reptiles: color atlas and text*. CRC Press Taylor & Francis Group, Boca Raton, FL., 1–12.
- Jegade, H. O., Sonfada, M. L., Salami, S. O. 2015. Anatomical studies of the gastrointestinal tract of the striped sand snake (*Psammophis Sibilans*). *Nigerian Veterinary Journal*, **36** (4), 1288–1298.
- Lukina, G. P. 1976. Ways of getting food. The size and characteristics of feed objects. In: Jablovok, A. V. *Sand lizard. Monographic description of the species*. Nauka, Moscow, 193–194 [In Russian].
- Mitchell, M. A., Diaz-Figueroa, O. 2005. Clinical reptile gastroenterology. *Veterinary Clinics: Exotic Animal Practice*, **8**, 277–298.
- Rodrigues Sartori, S. S., Nogueira, K. O. P. C., Rocha, A. S., Neves, C. A. 2011. Morphology of the stomach of the tropical house gecko *Hemidactylus mabouia* (Squamata: Gekkonidae). *Acta Zoologica* (Stockholm), **92**, 179–186.
- Secor, S. M., Diamond, J. 1998. A vertebrate model of extreme physiological regulation. *Nature*, **395**, 659–662.
- Shherbak, N. N., Ostashko, Ja. G. 1976. Range. In: Jablovok, A. V. *Sand lizard. Monographic description of the species*. Nauka, Moscow, 9–52 [In Russian].
- Skrypka, M. V., Panikar, I. I., Machuskiy, O. V., Tul, O. I. 2016. The results of microbiological screening of bacterial associations of sand lizard in the territory of Poltava city. *Problems of zooenvironmental and veterinary medicine: Collection of scientific papers Kharkiv state zooveterinary academy. Veterinary sciences*, **33** (2), 113–118 [In Ukrainian].
- Srichairat, N., Taksintum, W., Chumnanpuen, P. 2018. Gross morphological structure of digestive system in water monitor lizard *Varanus salvator* (Squamata: Varanidae). *Walailak Journal of Science and Technology*, **15** (3), 245–253.
- Vasil'ev, D. B. 2005. *Veterinary herpetology: lizards*. Project-F, Moscow, 1–480 [In Russian].
- Wyneken, J. 2011. Anatomy and physiology of the reptilian gastrointestinal tract. In: *Eighteenth Annual Conference Proceedings Association of Reptilian and Amphibian Veterinarians*. Seattle, Washington, 49–57.
- Zavyalov, E. V., Tabachishin, V. G., Shlyakhtin, G. V. 2000. Morphological characters and peculiarities of sand lizards (*Lacerta agilis exigua*) biology in the north of the lower Volga area. *Current Studies in Herpetology*, **1**, 6–14 [In Russian].
- Zinenko, O. I. 2006. *Reptiles of the forest-steppe zone of Left-bank Ukraine (distribution, morphology, taxonomy, biology, ecology)*. PhD thesis, Kyiv, 1–21 [In Ukrainian].
- Zon, H. A., Skrypka, M. V., Ivanovska, L. B. 2010. *Pathoanatomical dissection of animals: study guide*. Tarkus, Donetsk, 1–222 [In Ukrainian].

Received 30 April 2020

Accepted 26 October 2020