

Initial patterns of unilateral great saphenous vein reflux in women with telangiectasias and varicose veins

Carlos A. Engelhorn,^{1,2}

Ana Luiza D.V. Engelhorn,^{1,2}

Sergio X. Salles-Cunha,²

Patricia R. Terna,¹ Karine D. Kovalski,¹

Thaina V. Parizotto¹

¹Department of Angiology, School of Medicine, Pontifical Catholic University of Paraná; ²Angiolab Noninvasive Vascular Laboratory, Curitiba, PR, Brazil

Abstract

Telangiectasias and varicose veins have been linked to chronic venous valvular insufficiency causing great saphenous vein (GSV) reflux. GSV diameter-reflux correlations were determined in women C1 and/or C2 and unilateral GSV reflux. Subgroups were: i) bilateral C1/C1 (n=106) and ii) refluxing GSV C2/contralateral nonrefluxing C1 or C2 (n=50). GSV included saphenofemoral junction (SFJ), GSV, and major veins in and out of the saphenous compartment at knee and calf. Prevalence and diameters were compared by Chi-square and paired t-test. Reflux prevalence at junction, thigh and calf were 5%, 26% and 71% of 106 refluxing C1 extremities, and 18%, 44% and 72% of 50 refluxing C2 extremities (P=0.007, 0.03, 0.87). Significant diameter increase compared to contralateral non-refluxing segment (P<0.05) were at: C2 junction, 7.9±1.8 vs 6.6±1.5 mm, and C2 mid-thigh, junction refluxing or not, 4.8±1.1 vs 3.6±1.0 or 4.1±0.8 vs 3.6±0.7 mm. Calf GSV diameters averaged 2.5 to 2.7 mm if reflux was below-knee. Unilateral reflux occurred in calf veins without correlation to diameter. Enlarged diameters were noted in refluxing SFJ and thigh GSV of women with varicose veins.

Introduction

Telangiectasias and varicose veins have been linked to chronic venous insufficiency (CVI), or more specifically, to chronic venous valvular insufficiency (CVVI) and great saphenous vein (GSV) reflux.¹⁻³ This investigation focused specifically in women with early stages of CVVI characterized by C1, simple C2 and Pr classifications only. In particular, the great saphenous vein system

(GSV), comprised of the GSV in the proper compartment and major axial, parallel veins in and out of the saphenous compartment at the knee and calf levels, was evaluated.

Duplex ultrasonography has become the practical standard for diagnosis, pretreatment mapping, peri-treatment imaging, and patient follow-up of CVVI conditions. International consensus has described basic principles, related anatomy and follow-up protocols.⁴⁻⁶ Minimally invasive techniques have expanded the scope of treatment of affected veins, most commonly of superficial varicose veins, telangiectasias, and, in particular, of the refluxing GSV.⁷⁻¹⁴ GSV diameter measurements have become essential to complement evaluation of reflux and to help in treatment planning.¹⁴⁻¹⁷ Foam volume should depend on vein diameter, for example.¹⁴ Our initial report on GSV diameter and prediction of reflux was not based on an early disease, uniform, sample population.¹⁵ Our analyses for quality control of the vascular laboratory tried to improve precision in relation to female gender and clinical CEAP classes C1 and/or C2.^{2,3,18} This report centered on women with reflux in only one lower extremity. The objectives were to determine patterns of GSV reflux, to relate location of reflux and venous diameter, and to determine possible differences once the extremity developed varicose veins besides *spider veins* or telangiectasias.

Materials and Methods

Duplex ultrasound data came from examinations performed at an ISO 9001 certified Noninvasive Vascular Laboratory founded in Curitiba, state of Parana, south of Brazil, in 1991. Ultrasonography was performed by board certified physicians according to the rules set by vascular, cardiology and radiology Brazilian societies. The patients examined in this laboratory were predominantly of European descent, including ancestors of Portuguese, Italian, Polish, German, Ukrainian, and Slavic origins. This investigation conformed to the ethical guidelines of the 1975 Declaration of Helsinki and was approved by the Ethics committee of the Pontificia Universidade Católica do Paraná.

Inclusion criterion

Women with unilateral GSV reflux and CEAP clinical classification C1 and/or C2 entered the study. Men were excluded. Seven cases of extremities with non-severe edema but conditional swelling, and two cases with GSV reflux in the C1 extremity

Correspondence: Carlos A. Engelhorn, Angiolab Laboratório Vascular Não Invasivo, Rua da Paz, 195, Sala 2, Alto da XV, Curitiba, PR, Brazil, 80060-160.

E-mail: carlos.engelhorn@pucpr.br

Key words: Saphenous vein reflux; women; varicose veins; telangiectasias; Doppler ultrasound.

Contributions: CAE, ALDVE, design, data collection, quality control, manuscript reviewer, lab organization, data storage; SXSC, data analysis, manuscript writer; PRT, KDK, TVP: data collection.

Conflict of interest: the authors declare no potential conflict of interest

Received for publication: 18 April 2017.

Revision received: 13 June 2017.

Accepted for publication: 13 June 2017.

This work is licensed under a Creative Commons Attribution 4.0 License (by-nc 4.0).

©Copyright C.A. Engelhorn et al., 2017

Licensee PAGEPress, Italy

Veins and Lymphatics 2017; 6:6757

doi:10.4081/vl.2017.6757

but non-refluxing GSV in the contralateral C2 extremity were also excluded. Individual data were sequentially extracted from 353 archives automatically created according to standard laboratory protocol.

Sample patient population

Two subgroups were formed: i) C1 subgroup: actually, a C1/C1 subgroup, with 106 women who had telangiectasias in both legs but GSV reflux in only one. Average age of this subgroup was 42±13 years old, ranging from 23 to 79; ii) C2 subgroup: actually, a C2/C1-C2 subgroup with 50 women who had reflux in an extremity with varicose veins but no reflux in the other extremity with telangiectasias and/or varicose veins. Average age of this subgroup was higher, 49±12 years old, ranging from 21 to 79 (P=0.001).

Duplex Doppler ultrasonography

Duplex Doppler, color-flow ultrasonography was performed with Siemens Acuson Antares and Siemens Acuson X700 instruments and 7-10 MHz transducers. Patient was examined standing. The great saphenous vein (GSV) was scanned in its entire length, continuously. Reflux time greater than 0.5 sec and diameters were measured standing, even if an unsettled patient had to rest for a while to maintain the orthostatic position. Hand compression/decompression

maneuvers were standard; they provided versatility in studying virtually all venous segments in diverse calf and thigh positions. Long palm-finger compression, and fast decompression were the norm. Finger-tip compression was avoided. Valsalva maneuver was abandoned as nonproductive and cumbersome in patients with low probability of having saphenofemoral reflux. Laughing and talking could replace Valsalva maneuver as need. Source and drainage points of *GSV* reflux were marked. Practical experience recommended that *GSV* included the major, continuous, refluxing axial vein at the knee and calf level, even if the refluxing segment was not in the saphenous compartment for its entire length. Therefore, the *GSV* system included the saphenofemoral junction (SFJ), the *GSV* proper at the thigh, knee and calf, and/or the major collateral forming the major axis at the knee and calf levels (example: inclusion of the posterior accessory *arch* as part of the *GSV* system). Refluxing segments in and out of the great saphenous compartment were noted; such information was not provided for veins without reflux.

Patterns of reflux included: i) diffuse from SFJ to ankle; ii) proximal from SFJ to thigh, knee or calf; iii) segmental at the thigh, knee and/or calf levels but excluding SFJ; iv) multi segmental either including or not the SFJ; v) distal from thigh, knee or calf to ankle; and vi) perijunction as a non-femoral to *GSV* reflux. Detailed mappings were shown in Engelhorn *et al.*¹⁹ Diameters measured at the junction, proximal, mid and distal thigh, knee and proximal, mid and distal calf were reported. Statistical analysis focused on junction, thigh and calf representative measurements.

The final reported included a complete saphenous vein diagram with nonsaphenous veins additions as needed. Distances related to source, drainage and perforating vein positioning were indicated longitudinally and circumferentially. Such diagram was designed to minimize or shorten preoperative mapping. Past experience, however, indicated that mapping in the standing and operative or treatment positions may vary slightly but sometimes significantly for precise localization.²⁰

Figure 1 is a simplified example of a perforator to tributary *GSV* calf segment reflux. Although the figure shows a case with a perforating vein as source of reflux, our data analysis indicated that tributary veins were the most common source of saphenous vein reflux in C2 patients.²¹ Differences in type of reflux source were not part of this analysis.

Data analysis

Prevalence of reflux patterns was estimated. Prevalence was compared using Chi-square statistics. Descriptive statistics included mean, standard deviation, maximum and minimal diameters for each location. Average diameters from refluxing *versus* non-refluxing extremity were compared using paired t-test.

Results

Table 1 describes the prevalence of reflux patterns for the two subgroups. Subgroup C2 had significantly higher prevalence of SFJ and *GSV* thigh segment reflux than subgroup C1. The most common place of *GSV* reflux, however, was in the calf segment of both subgroups.

Table 2 documents diameters of the two subgroups with reflux in C1 and C2 extremities separately. Diameters of *GSV* with reflux in the calf segment of limbs with telangiectasias or with varicose veins were not significantly different than corresponding contralateral diameters in a non-refluxing *GSV*. Significant diameter differences

of about 0.3 mm were noted at the *GSV* thigh segment of C1 women with *GSV* reflux starting at the thigh level. Refluxing *GSV* mid-thigh to knee segment diameters dilated even more in the varicose vein limbs, the difference to the contralateral vein being about 0.5 to 0.8 mm.

Junction reflux prevalence was too small, particularly in the C1 subgroup. The differences in junction and thigh diameters in the C2 subgroup, however, were significant to warrant an observation. On average, refluxing veins were 1.3 to 1.1 mm larger in diameter than non-refluxing contralateral *GSVs* at and above the knee. These differences could be clearly noticed in ultrasonographic practice.

Discussion and Conclusions

A few significant concepts were emphasized with this investigation: i) *GSV* reflux in early CVVI of women with telangiectasias or with simple varicose veins was predominant in the calf segment; ii) saphenofemoral reflux had low prevalence, particularly in the subgroup with telangiect-

Table 1. Prevalence of great saphenous vein (GSV) patterns of reflux: unilateral GSV reflux.

Reflux pattern*	C1 group	C2 group	P
Diffuse from junction to ankle	0	0	
Multi segmental, from junction down	1	2	
Proximal, from junction to calf	2	3	
Proximal, from junction to knee	2	2	
Proximal, from junction to thigh	0	2	
Perijunction, excluding femorosaphenic	0	1	
<i>SF Junction reflux total</i>	5 (5%)	9 (18%)	0.007
Distal, from thigh to ankle	0	0	
Multi segmental, from thigh down	8	6	
Segmental, from thigh to calf	2	2	
Segmental, from thigh to knee	4	2	
Segmental, thigh only	9	2	
<i>Thigh segment reflux total</i>	28 (26%)	22 (44%)	0.03
Thigh segment and down only	23 (22%)	12 (24%)	-
Distal, from knee to ankle	1	1	
Segmental, from knee to calf	2	1	
Segmental, knee only	16	5	
<i>Knee segment reflux total</i>	38 (36%)	24 (48%)	0.15
<i>Knee segment and down only</i>	19 (18%)	7 (14%)	-
Distal, from calf to ankle	23	6	
Segmental, calf only	36	15	
<i>Calf segment reflux total</i>	75 (71%) ^o	36 (72%)	0.87
<i>Calf segment down only</i>	59 (56%)	21 (42%)	-

*C1 subgroup: C1 extremity with reflux, C1 extremity without reflux; C2 subgroup: C2 extremity with reflux, C2 or C1 extremity without reflux.

tasias; iii) GSV reflux in the calf failed to dilate such vein significantly when compared to the contralateral GSV; iv) diameter dilatations could be detected if reflux affected the thigh segment of the GSV, particularly in the limbs with varicose veins; and v) diameter dilatations could be easily documented if reflux affected the junction of limbs with varicose veins.

The total number of patients entered in this analysis represented 44% (156/353) of the reports surveyed for their selection. The percentage of normal extremities, 22%, was not that different from the prevalence of normal great saphenous evaluations reported previously for C2 (23%) subpopulation.³ It may represent a general estimate of normal examinations performed in this vascular laboratory. In contrast, the percentage of normal saphenous previously reported for C1 subpopulations was 56%.² A word of caution is needed to emphasize that these subpopulations prevalence data from a vascular laboratory does not represent disease prevalence per se. The women studied had ques-

tionable veins and complaints leading to an ultrasound examination. Relationships, or lack of them, between saphenous reflux and varicose veins or telangiectasias were not investigated. As a curiosity, however, we have already published a color doppler imaging sequence linking a new telangiectasia by history to thrombus inside a previously ablated saphenous vein (*confer*: Figure 3 in Salles-Cunha *et al.*²²) Furthermore, this analysis of saphenous vein reflux in C1 women was dictated by an international consensus classification indicating C1 as a subgroup not at the level of C2 to C6 classes. The primary intention was to study early stages of saphenous vein reflux.

The data reemphasized past reports that saphenofemoral junction reflux was relatively rare in this C1 and/or C2 subgroup studied. Prevalence of junction reflux at 5% and 18% respectively were comparable to 3% and 12% previously reported for C1 or C2 women.^{2,3} The subgroup in this analysis did not present what we named peri-junc-

tion reflux in the past, either a femoral to a non-great saphenous vein reflux with insufficient terminal valve, or a non-femoral to great saphenous reflux with normal terminal valve but refluxing preterminal valve.

A practical conclusion was that duplex ultrasonography of the superficial veins of the lower extremity should be considered even in women with telangiectasias. Another conclusion was that diameter measurements could still contribute to treatment type decision making since reflux may occur in either small or significantly dilated calf veins. Women studied herein may not have saphenous ablation; there is documentation that most common segmental reflux lose positioning to multisegment reflux as diseases progressed.¹⁸ Diameters could provide useful data related to the effects of clinical/stocking treatment, possible elimination of reflux by vasoconstriction medications, and dosage of foam or sclerotherapy saphenous injections, for example. Paired-t test statistics emphasizes existing differences that may be uneventful in nor-

Table 2. Great saphenous vein diameters: from saphenofemoral junction to distal calf.

Subgroup Type of reflux ^o	Average diameter (mm) ± standard deviation							
	SFJ	PT	MT	DT	K	PC	MC	DC
Junction starting reflux in extremities with varicose veins C2 n=9								
C2 SFJ reflux	7.9±1.8	5.7±1.0	4.8±1.1	4.4±1.0	4.5±1.3	3.2±1.0	2.6±0.5	2.6±0.7
C2 no reflux	6.6±1.5	4.5±1.2	3.6±1.0	3.3±1.1	3.2±0.9	2.9±0.9	2.5±0.6	2.7±0.8
Paired t-test	0.04	0.006	0.0002	0.01	0.0008	-	-	-
Junction starting reflux in extremities with telangiectasias C1 n=5								
C1 SFJ reflux	6.5±1.4	4.3±0.4	4.0±0.1	3.3±0.5	3.4±0.3	2.6±0.2	2.6±0.4	2.5±0.3
C1 no reflux	6.8±1.5	4.0±0.9	3.5±0.6	3.3±0.5	3.1±0.7	2.5±0.5	2.5±0.8	2.3±0.7
Paired t-test	No significant differences, small number of cases							
Thigh starting reflux in extremities with varicose veins C2 n=12								
C2 thigh reflux	6.8±1.3	4.3±1.0	4.1±0.8	4.1±1.0	4.1±1.3	3.1±0.9	2.6±0.4	2.7±0.4
C2 no reflux	7.5±1.4	4.6±1.0	3.6±0.7	3.4±0.8	3.3±0.8	2.8±0.7	2.4±0.5	2.6±0.5
Paired t-test	-	-	0.02	0.009	0.01	-	-	-
Thigh starting reflux in extremities with telangiectasias C1 n=23								
C1 thigh reflux	7.0±1.5	4.3±1.0	3.4±0.8	3.2±0.7	2.9±0.8	2.5±0.6	2.3±0.7	2.4±0.7
C1 no reflux	6.4±1.3	4.0±1.0	3.1±0.8	3.0±0.6	2.9±0.6	2.4±0.5	2.5±0.6	2.5±0.6
Paired t-test	0.004	0.047*	0.037*	0.056*	-	-	-	-
Calf reflux only in extremities with varicose veins C2 n=21								
C2 calf reflux	6.7±1.0	4.3±0.9	3.4±0.7	3.2±0.5	3.0±0.6	2.7±0.8	2.6±0.6	2.6±0.6
C2 no reflux	6.7±1.0	4.4±0.9	3.4±0.8	3.0±0.5	3.0±0.5	2.6±0.8	2.6±0.6	2.6±0.6
Paired t-test	No significant differences							
Calf reflux only in extremities with telangiectasias C1 n=59								
C1 calf reflux	6.7±1.4	4.2±0.9	3.5±0.8	3.3±0.7	3.2±0.8	2.6±0.7	2.5±0.6	2.6±0.6
C1 no reflux	6.5±1.4	4.2±0.9	3.4±0.8	3.2±0.7	3.1±0.8	2.6±0.6	2.4±0.6	2.5±0.6
Paired t-test	No significant differences							

^oSignificant differences detected only with one tail paired t-test. ^oReflux starting at the junction, thigh or limited to the calf segment. C1: extremities with telangiectasias; C2: extremities with varicose veins. SFJ, saphenofemoral junction; P, M, D: proximal, mid, distal; T: thigh; K: knee; C: calf.

mal clinical environment. The dilatations observed in the thigh segment of limbs with varicose veins, however, were notable and reportable rather easily in the duplex ultrasound examination performed by the most experienced sonographers. Actually, a small dilatation of the refluxing saphenous segment compared to the proximal normal saphenous segment can be useful to detect a location of reflux source associated with a tributary or a perforating vein (*confer. Figure 3* in reference Engelhorn *et al.*³).

Modern practice has accepted duplex ultrasonography to evaluate chronic venous valvular insufficiency in patients with varicose veins and nagging symptomatology. The GSV has demanded specific attention. Evaluation for superficial vein reflux in women with telangiectasias has had continued debates. We have demonstrated that GSV reflux has a significant prevalence in women with telangiectasias that search medical attention.² This investigation further emphasized the presence of GSV reflux in the calf of such patients.

Actual differentiation between GSV compartmental and non-compartmental calf segments has yet to be fully implemented in our own diagnostic duplex examinations. In or out compartment locations were described for refluxing segments but not for normal segments. Anatomic, secondarily non-functional details could confuse most referring physicians in our practice. Presence of dual channels and pre-operative mapping has demanded additional anatomic details. Differentiations between GSV proper (still anterior arch for some) *versus* posterior accessory saphenous (the posterior

arch eponym still acceptable) or other major tributaries were made if reflux were present; but again, details were abstained if these veins were not refluxing at the time of the examination. Nevertheless, peri-procedural mapping is recommendable.

The probability of detecting thigh or junction reflux was higher in legs with varicose veins than in legs with telangiectasias or reticular veins only. Such data presented herein suggested that simple varicose veins might represent a step forward in the deterioration of GSV in terms of reflux affecting the thigh and junction locations. Patient follow-up is recommended independent of the type of treatment. One objective would be to verify treatment efficacy or disease progression.¹⁸ Another objective would be to accompany the contralateral extremity that could develop a reflux disorder in the future.

The lack of relationship between GSV diameter in the calf and reflux indicated that valvular insufficiency could have many causes yet to be precisely identified on a patient per patient basis. One simple hypothesis is valvular damage. Another genetic type hypothesis is that the refluxing vein has no valves or has working valves in ineffective locations. Advanced ultrasonography could relate the difference between venous retrograde filling and actual reflux by determining the characteristics of the vein draining the reflux away from the main GSV channel. The hypothesis of reflux in a vein with valves that can work under venoconstriction but not under venodilatation could still be considered and it needs to be tested appropriately. Nevertheless, *normal*

extremities in the morning with reflux detected in the afternoon is a history that has been described often. This investigation made the hypothesis that the contralateral GSV was a standard for comparison, including venodilatation under the same conditions for both the non-refluxing and the refluxing vein. Duplex dual examinations in conditions of venoconstriction and venodilatation are still needed to follow the *precision* theory in investigative phlebology.

In summary, attention to GSV reflux in the calf and relative increases in GSV diameters at the thigh and junction is recommended when performing duplex ultrasonography in patients with early chronic venous valvular insufficiency represented by limbs with telangiectasias, reticular veins, or simple varicose veins (C1/C2) without edema, skin changes or ulcers (C3/C4/C5-6). This analysis further corroborates the hypotheses that saphenous reflux started at the weakest point of the vein, mostly in the leg, and that vein dilation could probably be associated with valvular insufficiency before valve damage. Further, specific research is needed to demonstrate the second statement.

References

1. Eklöf B, Rutherford RB, Bergan JJ, et al. Revision of the CEAP classification for chronic venous disorders: consensus statement. *J Vasc Surg* 2004;40:1248-52.
2. Engelhorn CA, Engelhorn AL, Cassou MF, Salles-Cunha S. Patterns of saphenous venous reflux in women presenting with lower extremity telangiectasias. *Dermatol Surg* 2007;33:282-8.
3. Engelhorn CA, Engelhorn AL, Cassou MF, Salles-Cunha SX. Patterns of saphenous reflux in women with primary varicose veins. *J Vasc Surg* 2005; 41:645-51.
4. Coleridge-Smith P, Labropoulos N, Partsch H, et al. Duplex ultrasound investigation of the veins in chronic venous disease of the lower limbs--UIP consensus document. Part I. Basic principles. *Eur J Vasc Endovasc Surg* 2006;31:83-92.
5. Cavezzi A, Labropoulos N, Partsch H, et al. Duplex ultrasound investigation of the veins in chronic venous disease of the lower limbs--UIP consensus document. Part II. Anatomy. *Eur J Vasc Endovasc Surg* 2006;31:288-99.
6. De Maeseneer M, Pichot O, Cavezzi A, et al. Duplex ultrasound investigation of the veins of the lower limbs after treat-

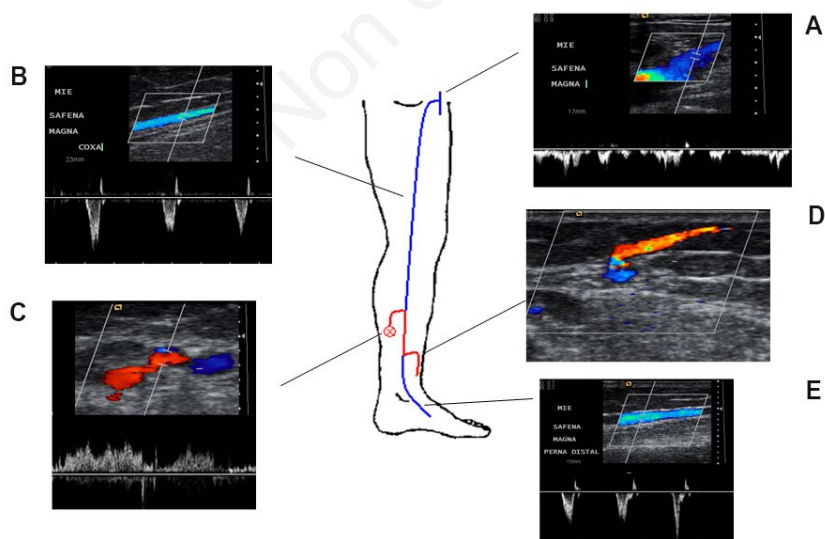


Figure 1. Calf great saphenous vein segmental reflux: A) no saphenofemoral junction reflux; B) no thigh segment reflux; C) reflux source: perforating vein at upper calf; D) reflux drainage: tributary vein at mid-distal calf; E) normal great saphenous vein distal segment.

- ment for varicose veins - UIP consensus document. *Eur J Vasc Endovasc Surg* 2011;42:89-102.
7. Balint R, Farics A, Parti K, et al. Which endovenous ablation method does offer a better long-term technical success in the treatment of the incompetent great saphenous vein? Review. *Vascular* 2016;24:649-57.
 8. Goodyear SJ, Nyamekye IK. Radiofrequency ablation of varicose veins: Best practice techniques and evidence. *Phlebology* 2015;30:9-17.
 9. Gianesini S, Menegatti E, Zuolo M. Laser-assisted strategy for reflux abolition in a modified CHIVA approach. *Veins and Lymphatics* 2015;4:5246.
 10. Salles-Cunha SX, Rajasinghe H, Dosick SM, et al. Fate of great saphenous vein after radio-frequency ablation: detailed ultrasound imaging. *Vasc Endovascular Surg* 2004;38:339-44.
 11. Cavezzi A, Mosti G, Di Paolo S, et al. Ultrasound-guided peri-saphenous tumescence infiltration improves the outcome of long catheter foam sclerotherapy of the varicose tributaries. *Veins and Lymphatics* 2015;4:4676.
 12. Ricci S, Moro L, Incalzi RA. Ultrasound assisted great saphenous vein ligation and division: an office procedure. *Veins and Lymphatics* 2014;3:4428.
 13. Morrison N, Neuhardt DL, Rogers CR, et al. Incidence of side effects using carbon dioxide-oxygen foam for chemical ablation of superficial veins of the lower extremity. *Eur J Vasc Endovasc Surg* 2010;40:407-13.
 14. Stücker M, Kobus S, Altmeyer P, Reich-Schupke S. Review of published information on foam sclerotherapy. *Dermatol Surg* 2010;36:983-92.
 15. Engelhorn C, Engelhorn A, Salles-Cunha S, et al. Relationship between diameter and great saphenous vein reflux. *J Vasc Technol* 1997;21:167-72.
 16. Ricci S. Comment to: Great saphenous vein diameter at the saphenofemoral junction and proximal thigh as parameters of venous disease class, by Mendoza E, Blättler W, Amsler F. *Eur J Vasc Endovasc Surg* 2013;45:76-83. *Veins and Lymphatics - BiblioLab* 2013: 1. Available from: <http://www.pagepressjournals.org/index.php/vl/article/view/ByiblioLab.2013.1>
 17. Mendoza E, Blattler W, Amsler F. Great saphenous vein diameter at the saphenofemoral junction and proximal thigh as parameters of venous disease class. *Eur J Vasc Endovasc Surg* 2013;45:76-83.
 18. Engelhorn CA, Manetti R, Baviera MM, et al. Progression of reflux patterns in saphenous veins of women with chronic venous valvular insufficiency.
 19. Engelhorn CA, Engelhorn AL, Cassou MF, et al. Patterns of reflux in saphenous veins based on color flow duplex ultrasound scanning. *Vascular Ultrasound Today* 2003;8. Available from: http://www.angiolab.com.br/publicacoes/Publication/18_lesson6.html
 20. Engelhorn C, Picheth F, Castro N Jr., et al. Color flow localization of insufficient communicating or perforating veins prior to surgical ligation. *J Vascular Technol* 1993;17:251-3.
 21. Engelhorn C, Engelhorn A, Casagrande C, Salles-Cunha SX. Sources and drainages of saphenous vein reflux in patients with primary varicose veins. Poster, final program of the American Venous Forum 11th Annual Meeting of the, Dana Point, CA, February 18-21, 1999, p. 96.
 22. Salles-Cunha SX, Commerota AJ, Tzilinis A, et al. Ultrasound findings after radiofrequency ablation of the great saphenous vein: Descriptive analysis. *J Vasc Surg* 2004;40:1166-73.