

A Modified Disposable Circumcision Suture Device with Application of Plastic Sheet to Avoid Severe Bleeding After Circumcision

Miao Li¹, Xiaojie Ang¹, Weiguo Chen¹, Nianxin Gai¹, Jiangnan Xu¹, Jiawei You^{1*}, Yuhua Huang^{1*},
Jianquan Hou^{1*}

Purpose: To evaluate the effectiveness of a modified disposable circumcision suture device (DCSD) with application of plastic sheet to avoid severe bleeding after circumcision and compare the surgical effects and other postoperative complications of two DCSDs.

Materials and Methods: A total of 943 excess foreskin patients from January 2018 to January 2020 who underwent circumcision using two different DCSDs were recruited. Preoperative characteristics (patient age, height and weight), main surgical outcomes (surgical time, intraoperative blood loss, incision healing time) and postoperative complications (postoperative hemorrhage and hematoma rate, edema rate, incision infection rate, residual staples rate) were collected and analyzed. Patients' "satisfaction" or "dissatisfaction" was also investigated.

Results: Preoperative characteristics showed no significant statistical difference. The modified DCSD group has a lower intraoperative bleeding, postoperative hemorrhage or hematoma rate and residual staples rate compared with the conventional group. Incision healing time and incision infection rate between the two groups were similar. Nevertheless, conventional group has a shorter surgical time, a lower edema rate and a higher satisfaction rate.

Conclusion: The modified DCSD with application of plastic sheet can avoid severe bleeding after circumcision effectively and can be served as a new choice for circumcision.

Keywords: circumcision; disposable circumcision suture device; excess foreskin; hemorrhage; modified

INTRODUCTION

Redundant prepuce and phimosis are common andrology diseases. It can cause inflammation of the glans, dysuria, carcinoma of penis, and premature ejaculation.⁽¹⁾ Circumcision is the most effective method for treatment of prepuce and phimosis. It's also an effective prevention of sexually transmitted diseases such as HIV and papillomavirus infection.^(2,3) Methods for circumcision have been developed rapidly, from conventional circumcision, sleeve circumcision, to Shang Ring circumcision, Ali's clamp technique.^(4,5) In recent years, a novel disposable circumcision suture device (DCSD) has been favored by numbers of urologists due to its advantages of shorter operation duration, less blood loss and better cosmetic appearance.⁽⁶⁾ However, some complications of DCSD have also been reported.⁽⁷⁾ Since the wound is sutured by staples, rather than traditional surgical suture, the most common and serious complication is postoperative hemorrhage and hematoma. Most of the time, patients need an urgent pressure dressing or require a surgical intervention for evacuation of hematoma and suture hemostasis. It makes a huge impact on patients, both physically and psychologically. Here, we introduce a modified disposable circumcision suture device with application of a plastic sheet and compare the surgical effects and postoperative complications of two DCSDs.

MATERIALS AND METHODS

Study population

Our study is approved by our Institutional Review Board (Clinical trial identifier: 323) and all the patients were given anonymity and informed consent. The data was collected from January 2018 to January 2020. Patients underwent circumcision with two different disposable circumcision suture devices. Type A (Langhe circumcision suture) is the conventional disposable circumcision suture device without plastic sheet (**Figure 1a, c, e**); Type B (Huang circumcision suture) has a modified plastic sheet before the staple reservoir and after triggering the device, the plastic sheet is fixed on the wound (**Figure 1b, d, f**). The choice of DCSD followed patients' preference and they were not informed of the advantages or disadvantages of the two DCSDs. Before the surgery, the informed consent was signed. In order to help the bell-like inner pole insert into the ostium praeputiale, phimosis patients need an incision of the foreskin, which affects the quantification of blood loss. So, phimosis patients were excluded. Patients with systemic hematological diseases were also excluded. For the patients suffering from infection of glans penis, circumcision must be performed after infection was controlled.

Operative procedures

All the surgeries were performed by the same surgeon.

¹Department of Urology, the First Affiliated Hospital of Soochow University, Suzhou, Jiangsu, China.

*Correspondence: Department of Urology, the First Affiliated Hospital of Soochow University, 188 Shizi Road, Suzhou 215006, People's Republic of China.

Tel: +8618906210606; E-mail: urologistlee@163.com;

Received August 2021 & Accepted January 2022

Table 1. Comparison of operative and postoperative characteristics between the two groups.

Circumcision group	Conventional group (N = 552)	Modified group (N = 391)	P-value
Age, years;	28.1 ± 11.4	26.9 ± 10.8	.095
BMI, kg/m ² ;	23.73 ± 1.37	23.56 ± 1.26	.052
Surgical time, min;	5.2 ± 1.0	7.7 ± 1.4	< .001*
Intraoperative bleeding, ml;	4.6 ± 0.9	2.3 ± 1.2	< .001*
Postoperative hemorrhage and hematoma rate	13/552 (2.4%)	2/391 (0.5%)	.026*
Incision healing time, day;	7.9 ± 1.2	8.1 ± 1.1	.062
Edema rate	247/552 (44.7%)	208/391 (53.2%)	.011*
Incision infection rate	93/552 (16.8%)	77/391 (19.7%)	.263
Residual staples rate	109/552 (19.7%)	17/391 (4.3%)	< .001*
Satisfaction rate	536/552 (97.1%)	344/391 (88.0%)	< .001*

Abbreviations: BMI, Body Mass Index; * Statistical difference. Values are mean ± SD.

First, the surgical area was fully disinfected and a local dorsal penile nerve block was performed. DCSD mainly consists of an outer pole, a bell-like inner rod, an adjusting knob and suture staple, (Figure 1a, b, c). The modified DCSD has a plastic sheet before the staple reservoir (Figure 1d). Devices of different sizes were designed to fit different penis sizes. Circumcision using DCSD approach was performed as Jingen Wang et al. described.⁽⁸⁾ Briefly, we inserted the bell-like inner rod into the ostium praeputiale at first. And then, we fixed the foreskin onto the rod, and inserted the end of the rod into the outer pole. After adjusting the cutting position, DCSD was triggered. The redundant foreskin was removed and the staples were sutured at the incision at the same time. The frenulum was retained when circumci-

sion was performed. Differently, Type A DCSD has no plastic sheet, and the staples were placed at the incision directly (Figure 1e). Type B DCSD has a modified plastic sheet, and the staples were placed at the plastic sheet before being fastened on the wound (Figure 1f). And this modified plastic sheet could apply pressure to prevent bleeding from the wound.

All patients in the two groups were dressed with a self-adhesive flexible bandage and prescribed oral antibiotics for 3 days. The pressure bandage should keep dry and clean, and it was removed 3 days after surgery. After that, the wound was cleaned every day until all the staples dropped out and the follow-up lasted 1 month at least until the incision was completely healing.

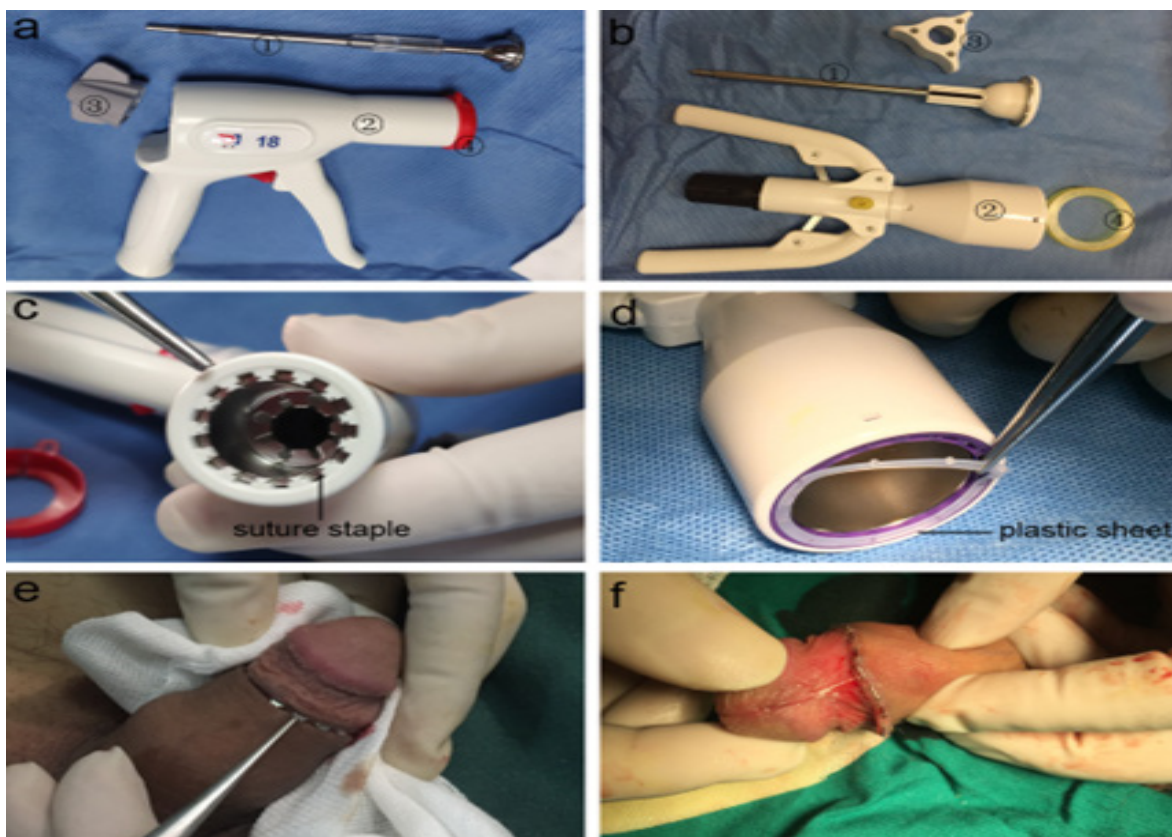


Figure 1. Structural composition and postoperative appearance of two DCSDs. a and b Structural composition of DCSD ① bell-like inner rod ② outer pole ③ adjusting knob ④ safety-cap. c Suture staple of the conventional DCSD. d Plastic sheet before the staple reservoir of the modified DCSD. e Postoperative appearance of the conventional DCSD. f Postoperative appearance of the modified DCSD

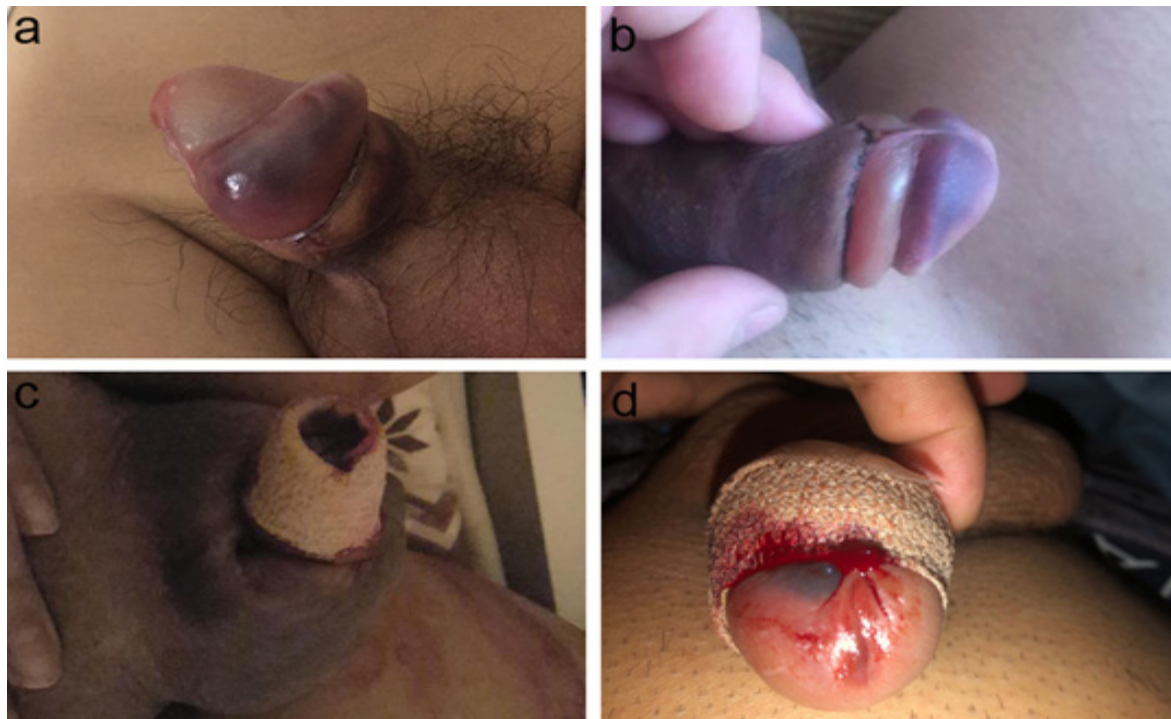

Figure 2. **a** Representative edema of the modified DCSD. **b** Representative edema of the conventional DCSD. **c** A postoperative hematoma case of the conventional DCSD. **d** A postoperative hemorrhage case of the conventional DCSD.

Evaluations

1. Preoperative characteristics of the patients were collected, including patient age, height and weight, and body mass index (BMI) was calculated.
2. Surgical time: It's the operation duration from the initiation to the end of operation.
3. Intraoperative bleeding: It's estimated by 5cm × 5cm gauzes which could suck 3.25mL blood.(9)
4. Postoperative hemorrhage and hematoma rate: Patients with active bleeding or progressively larger hematoma (Figure 2c.d).
5. Incision healing time: When the wound healed completely, healing time was recorded.
6. Edema rate: Patients developed edema when pressure bandage was removed (Figure 2a.b).
7. Incision infection rate: Incision with exudation or secretion of tissue fluid and would not heal.
8. Residual staples rate: Patients who come back to remove the residual staples 1 month after surgery.
9. Satisfaction rate: Patients' "satisfaction" or "dissatisfaction" with their cosmetic penis appearances and the whole recovery process.

Statistical analysis

SPSS version 20.0 was used for statistical analyses. Numerical data were presented as mean ± standard deviation (SD) and compared by independent *t* test. Normality and homogeneity of variance were assessed before independent *t* test. Wilcoxon rank sum test was used for data with non-normal distributions. Categorical data were presented as frequencies and percentages and compared by Chi-square test or Fisher's exact test. $P < .05$ was considered statistically significant.

RESULTS

There were total 943 patients with excess foreskin enrolled in our study. 552 patients chose Type A (Langhe circumcision suture) DCSD for circumcision, and here we defined it as the "conventional group". On the other hand, 391 patients chose Type B (Huang circumcision suture) DCSD, and we defined it as the "modified group". The patients' age and BMI between the two groups showed no significant statistical difference ($P = .095$ and $.052$ respectively). Surgical time in the conventional group was significantly shorter than that in the modified group ($P < .001$). However, intraoperative blood loss in the conventional group was higher than that in the modified group ($P < .001$).

At the follow-up, in modified group, postoperative hematoma occurred in only two patients. One patient's hematoma occurred after 3 days from the pressure bandage was removed. Another one occurred after strenuous exercise. In the conventional group, postoperative hemorrhage and hematoma occurred in 13 patients, which showed a significantly higher rate than modified group (2.4% versus 0.5%, $P = .026$). Figure 2c.d were representative postoperative hematoma and hemorrhage patients. Incision healing time and incision infection rate between the two groups showed no significant statistical difference ($P = .062$ and $P = .263$ respectively). After patients' pressure bandage was removed, edema rate was calculated. We found that in the modified group, edema rate was significantly higher than conventional group (53.2% versus 44.7%, $P = .011$). Figure 2a.b were representative edema patient in two groups. At 1-month visit, most patients experienced spontaneous removal of wound staples. Residual staples rate in conventional group and modified group were 19.7% and 4.3% ($P < .001$) respectively. Interestingly, satisfaction

rate in modified group was lower than conventional group (88.0% versus 97.1%, $P < .001$) despite its lower intraoperative bleeding, postoperative hemorrhage and hematoma rate. All the detailed data was shown in **Table 1**.

DISCUSSION

Although circumcision is an effective method in preventing sexually transmitted diseases and curing refractory balanitis, many people underwent circumcision just on account of religious obligation.^(10,11) Postoperative complications may be an important factor preventing people from circumcision. In some western countries, iatrogenic phimosis was reported as a common complication after circumcision with thermocautery.⁽¹²⁾ In South Africa, where HIV infection rates are high, voluntary medical male circumcision remains suboptimal, with safety concerns identified as a barrier to uptake.⁽¹³⁾ On account of this, new safe and efficient circumcision devices are urgently needed which might promote the prevalence of voluntary medical male circumcision.

In recent years, with the development of minimally invasive surgery and improvement of people's perception of circumcision's importance, acceptability for circumcision is gradually increasing in China. A novel type of DCSD was widely used by urologists in China these years.⁽¹⁴⁾ It has also been reported in the West and is loved by many doctors thanks to its advantages of shorter operation duration, less blood loss and better cosmetic appearance.⁽¹⁵⁾ However, some problems of DCSD were reported. For example, patients with severe phimosis need to cut the prepuce which undoubtedly increases the risk of intraoperative bleeding.⁽¹⁶⁾ There is a risk of hemorrhage for patients operated with DCSD, since the wound was stapled together instead of suture. Postoperative hemorrhage and hematoma may be the most common and serious complication.⁽¹⁷⁾ It makes huge impact on patients, both physically and psychologically. So, many urologists are searching for a modified method to reduce bleeding.⁽¹⁸⁾

In our department, another modified DCSD was used recently. This new DCSD has a modified plastic sheet. It can exert a pressure on the wound while the staples are used to fix the wound. In our study, we compared the surgical effects and postoperative complications of two DCSDs. The patients' age and BMI between the two groups showed no significant statistical difference, excluding the effects of age and BMI on this study. We found that the modified group had a lower intraoperative blood loss and postoperative hemorrhage or hematoma rate ($P < .001$ and $P = .026$ respectively), mainly thanks to the compression of the plastic sheet on the wound as mentioned before. On the contrary, conventional DCSD has no plastic sheet and the staples fix the incision wound directly. Occasionally, some vessels between the fixed staples might cause subsequent bleeding or hematoma. At the same time, incision healing time and incision infection rate between the two groups showed no significant statistical difference ($P = .062$ and $P = .263$ respectively), indicating that this plastic sheet wouldn't affect wound healing or lead to incision infection. However, patients undergoing circumcision with modified DCSD were characterized by a higher edema rate than conventional group ($P = .011$). It's attributed to that the compression of the plastic sheet on the wound can cause impairment of lymphatic reflux.

However, the edema can be controlled effectively when appropriate decongestant medications are used. We can also cut plastic sheet every two or three staples with scissors when the bandage is removed. And at that time, the wound is almost healed and postoperative hemorrhage or hematoma would scarcely occur. At 1-month visit, we compared the residual staples rate between the two groups. We found that the conventional group's residual staples rate was significantly higher than that of the modified group. We believe that the staples were sutured at the incision directly in the conventional group and some staples were embedded tightly in tissue or scar. It's difficult for these staples to drop out spontaneously and patients had to come back to hospital to remove the residual staples. At last, the patients' satisfaction rate was compared between two groups. Despite modified group's lower intraoperative bleeding, postoperative hemorrhage and hematoma rate, patients in conventional group seemed to be more satisfied with their cosmetic penis appearances and experience in the recovery process. Most unsatisfied patients in modified group complained about the edema, since the edema could be observed directly and it caused their discomfort and worry for a long time.

Nevertheless, there are several limitations within the present study. First, all the operations were performed on outpatients, and patients went back home after observation of 30-60min. Different nursing care in different families might affect the outcome of surgery. This provided a potential confounding bias of the present investigation. Second, though BMI between the two groups were comparable, difference in BMI between the patients with hemorrhage and the patients without hemorrhage was not investigated. In terms of this issue, we will carry out further research in future study.

CONCLUSIONS

Our study introduces a modified DCSD widely used in China recently with application of a plastic sheet. It has advantages of lower intraoperative bleeding, postoperative hemorrhage or hematoma rate and residual staples rate. Furthermore, it won't affect incision healing time and incision infection rate. Nevertheless, we should care about patients who used this modified DCSD, for its higher edema rate.

ACKNOWLEDGEMENT

The present study was supported by the National Natural Scientific Foundation of China Grants (Nos. 81772708).

CONFLICT OF INTEREST

The authors report no conflict of interest.

REFERENCES

1. Zhang SJ, Zhao YM, Zheng SG, Xiao HW, He YS. Correlation between premature ejaculation and redundant prepuce. *Zhonghua Nan Ke Xue*. 2006;12:225-7.
2. Sharma AL, Hokello J, Tyagi M. Circumcision as an Intervening Strategy against HIV Acquisition in the Male Genital Tract. *Pathogens*. 2021;10.
3. Smith JS, Backes DM, Hudgens MG, et al. Male Circumcision Reduces Penile HPV Incidence and Persistence: A Randomized

- Controlled Trial in Kenya. *Cancer Epidemiol Biomarkers Prev.* 2021;30:1139-48.
4. Mu J, Fan L, Liu D, Zhu D. A Comparative Study on the Efficacy of Four Types of Circumcision for Elderly Males with Redundant Prepuce. *Urol J.* 2020;17:301-5.
 5. Senel FM, Demirelli M, Oztek S. Minimally invasive circumcision with a novel plastic clamp technique: a review of 7,500 cases. *Pediatr Surg Int.* 2010;26:739-45.
 6. Huo ZC, Liu G, Li XY, et al. Use of a disposable circumcision suture device versus conventional circumcision: a systematic review and meta-analysis. *Asian J Androl.* 2017;19:362-7.
 7. Huang C, Song P, Xu C, Wang R, Wei L, Zhao X. Comparative efficacy and safety of different circumcisions for patients with redundant prepuce or phimosis: A network meta-analysis. *Int J Surg.* 2017;43:17-25.
 8. Wang J, Zhou Y, Xia S, et al. Safety and efficacy of a novel disposable circumcision device: a pilot randomized controlled clinical trial at 2 centers. *Med Sci Monit.* 2014;20:454-62.
 9. Hughes K, Chang YC, Sedrak J, Torres A. A clinically practical way to estimate surgical blood loss. *Dermatol Online J.* 2007;13:17.
 10. Gao Y, Yuan T, Zhan Y, et al. Association between medical male circumcision and HIV risk compensation among heterosexual men: a systematic review and meta-analysis. *Lancet Glob Health.* 2021;9:e932-e41.
 11. Dogan G. The Effect of Religious Beliefs on the Publication Productivity of Countries in Circumcision: A Comprehensive Bibliometric View. *J Relig Health.* 2020;59:1126-36.
 12. Akyuz O, Cam K. The Management of Phimosis Seen after Circumcision with Thermocautery. *Urol J.* 2020;17:50-4.
 13. Muchiri E, Charalambous S, Ginindza S, et al. Description of adverse events among adult men following voluntary medical male circumcision: Findings from a circumcision programme in two provinces of South Africa. *PLoS One.* 2021;16:e0253960.
 14. Rao JM, Huang H, Chen T, et al. Modified Circumcision Using the Disposable Circumcision Suture Device in Children: A Randomized Controlled Trial. *Urology.* 2020;143:206-11.
 15. Pozza D, Pozza C, Mosca A, Pozza M. Preputial circumcision performed with a new mechanical stapling tool. The "langhe disposable circumcision suture device". Preliminary experiences. *Arch Ital Urol Androl.* 2020;91:261-2.
 16. Su Q, Gao S, Chen J, et al. A Comparative Study on the Clinical Efficacy of Modified Circumcision and Two Other Types of Circumcision. *Urol J.* 2020;18:556-60.
 17. Hinkle LE, Toledo C, Grund JM, et al. Bleeding and Blood Disorders in Clients of Voluntary Medical Male Circumcision for HIV Prevention - Eastern and Southern Africa, 2015-2016. *MMWR Morb Mortal Wkly Rep.* 2018;67:337-9.
 18. Jiang W, Fu JL, Guo WL, et al. A Modified Pressure Dressing to Avoid Severe Bleeding After Circumcision With a Disposable Circumcision Suture Device and a Discussion on the Mechanism of Bleeding With the Disposable Circumcision Suture Device. *Sex Med.* 2021;9:100288.