

Primary Epidermoid Cyst of the Clitoris in Adult Female Population: Three Case Reports and Introducing a Safe Surgical Approach.

Nastaran Mahmoudnejad^{1*}, Peyman Mohammadi Torbati², Alireza Zadmehr³

Epidermoid cyst (EPC) of the clitoris is a very rare cause of non-hormonal acquired clitoromegaly. Clitoral EPCs are extremely uncommon without prior history of genital surgery, trauma, circumcision, or piercing. Surgical removal with special care to avoid compromising neurovascular bundle of the clitoris is the preferred treatment. To our best knowledge, only three cases of adult female clitoral EPC without history of genital surgery, female circumcision, or medications including oral or implantable contraceptives have been reported. Herein, we describe three cases of primary EPC of the clitoris, their management, unique histopathology report, safe surgical approach, and their follow up course.

Keywords: clitoromegaly; epidermoid cyst; spontaneous; clitoral cyst; case report; ciliated metaplasia

INTRODUCTION

Clitoromegaly can be classified into two distinct categories. It can be acquired or congenital. Acquired clitoromegaly may have hormonal or non-hormonal etiologies.⁽¹⁾ EPC of the clitoris is an infrequent cause of non-hormonal acquired clitoromegaly. These cysts are formed when the epidermis is traumatically transplanted, or idiopathically present in the dermis or the subcutis. EPCs are usually solitary, round, and elevated tumors commonly found on the back, chest, neck, face, or scalp. They often

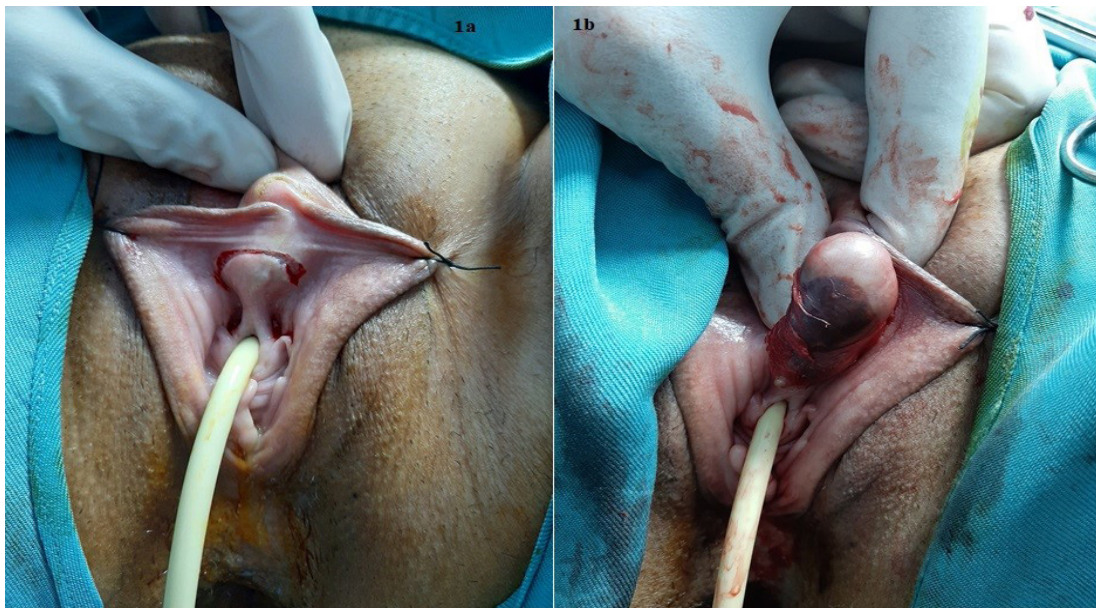


Figure 1. 1a: Supra meatal inverted-U incision. **1b:** Removal of the cyst with blunt and sharp dissection.

¹Assistant professor of urology, Fellowship of female urology, Shahid Labbafinejad Hospital, Urology and Nephrology Research Center (UNRC), Shahid Beheshti University of Medical Sciences, Tehran, Iran.

²Associate professor of pathology, Shahid Labbafinejad Hospital, Urology and Nephrology Research Center (UNRC), Shahid Beheshti University of Medical Sciences, Tehran, Iran.

³Resident of Urology, Shahid Labbafinejad Hospital, Urology and Nephrology Research Center (UNRC), Shahid Beheshti University of Medical Sciences, Tehran, Iran.

*Correspondence: Assistant professor of urology, Fellowship of female urology, Shahid Labbafinejad Hospital, Urology and Nephrology Research Center (UNRC), Shahid Beheshti University of Medical Sciences, Tehran, Iran. 9th Boustan St., Pasdaran Ave. Tehran, Iran. Postal code: 16666
Tel/Fax: +98-21-22588016. Email: nastaran.mahmoudnejad@gmail.com.

Received June 2020 & Accepted October 2020

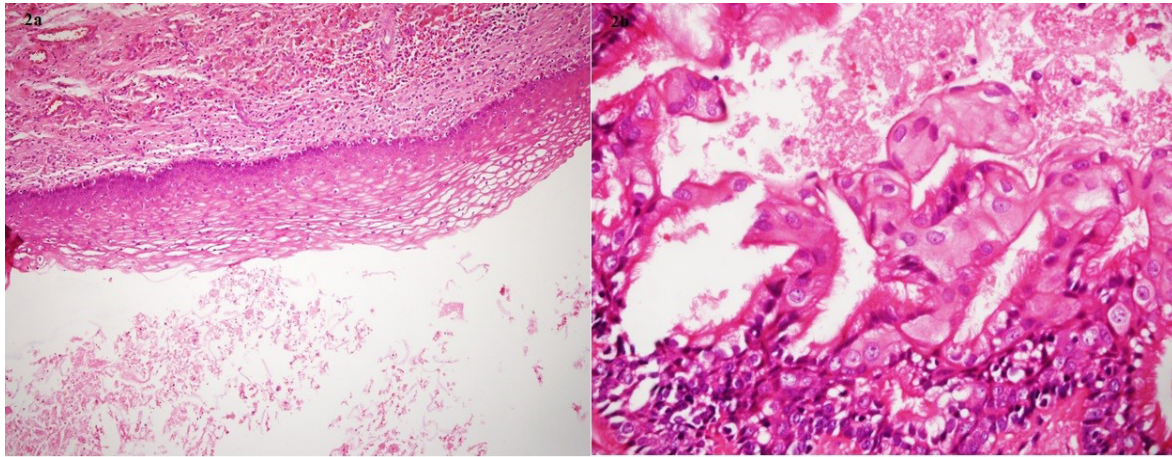


Figure 2. 2a: Stratified keratinizing squamous epithelium, keratin material in lumina and dense fibro-connective tissue of the cyst wall. ($\times 100$ H&E Staining) **2b:** Mixture of secretory cells, intercalated cells, and ciliated cells ($\times 400$ H&E Staining)

stop growing after reaching a size of 1-5 cm in diameter. External genitalia can also be involved with clitoral, labial, or scrotal implantation. The cyst is characterized by an outer wall of epidermis with a center filled with keratinaceous material arranged in laminated layers.^(2,3) Clitoral EPCs are extremely rare without prior anterior surgical excision, infibulation, circumcision, or genital piercing with epidermal clitoral inclusion involved.⁽⁴⁾ Due to exclusive role of the clitoris in female orgasm and sexual activity, any kind of surgery at this site should be performed with special care. To our best knowledge, only three cases of adult female clitoral EPC without history of genital surgery, female circumcision, or medications including oral or implantable contraceptives have been reported. Three cases of primary EPC of the clitoris, their management, unique histopathology report, safe surgical approach, and their follow up course are described in this article.

CASE REPORT

Case one: A 45-year-old female presented with a six-month history of progressively painless enlarging clitoral mass. She did not have any history of genital surgery or genitourinary symptoms. Pelvic examination revealed a mobile, non-tender, soft, well defined clitoral mass measuring approximately 5 \times 2 cm. General physical examination was normal and there was no sign of hyperandrogenism.

Routine lab tests were within normal limits. The patient was scheduled for surgical exploration and excision of the mass. Under a spinal anesthesia, a Foley urethral catheter was inserted and a supra-meatal inverted-U incision was made. (**Figure 1a**) The cyst was removed with combination of sharp and blunt dissection (**Figure 1b**). Special care was given to avoid compromising the neurovascular bundle of the clitoris. Hemostasis was achieved and the incision was repaired with interrupted

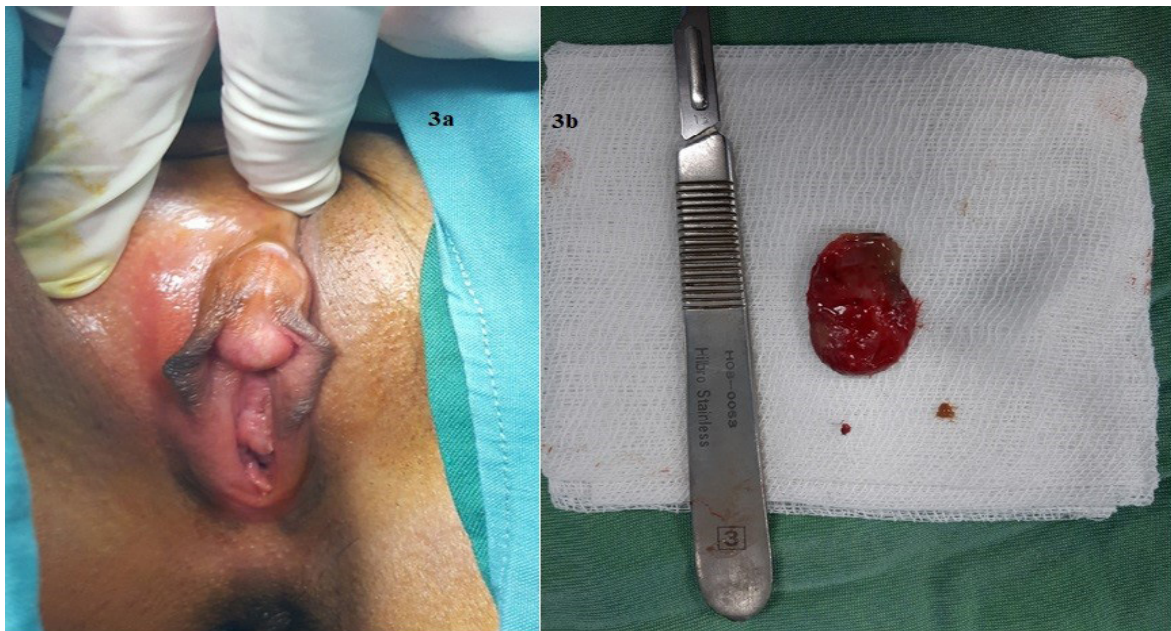


Figure 3. 3a: Gross appearance of the clitoral cyst. **3b:** Excised specimen of the cyst.

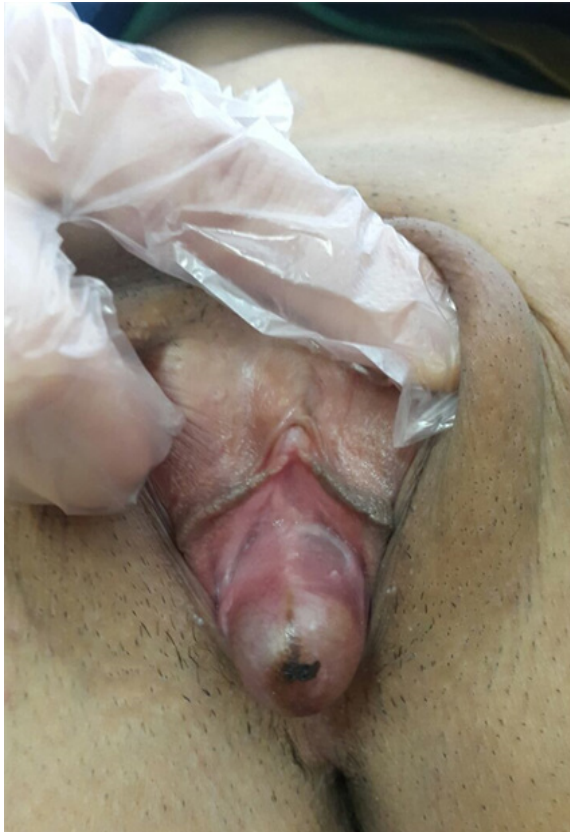

Figure 4. Clitoral cyst with surface ecchymosis.

3-0 absorbable sutures. The patient was discharged the same day and the post-operative period was uneventful. The histopathology report revealed a $5 \times 1.5 \times 0.5$ epidermoid cyst. The cystic structure in the majority of areas was lined with stratified keratinizing epithelium (**Figure 2a**), which was supported by chronically inflamed dense fibro-connective tissue. At one focus features of tubal metaplasia including ciliated cells (clear cytoplasm, abundant apical cilia), secretory cells (non-ciliated with eosinophilic apical cytoplasmic protrusions but not mucin vacuoles) and intercalated cells were identified. (**Figure 2 b**) No evidence of nuclear atypia and/or dysplasia was seen. At two-week office visit, the incision was healed completely with excellent cosmetic appearance. At six-month follow up visit, tactile and sexual sensation were preserved and there was no recurrence at the surgical site.

Case two: A 35-year-old female was consulted for a two-year history of non-tender clitoral mass. She complained about difficulty in voiding and also some degrees of dyspareunia, lately. Medical history was unremarkable. She didn't mention any history of genital trauma, piercing, or surgery. There was no sign of virilization. On local examination, a mobile, fluctuant, and firm cystic lesion was palpated at the clitoral site. (**Figure 3a**). Lab investigations were within normal limits. During the operation, the cyst was excised through a supra-meatal inverted-U incision. The ventral wall of the cyst was densely attached to the base of the clitoris. Some amount of sebaceous material leaked from the cyst during dissection. The cyst was removed without compromising the neurovascular bundle of the clitoris.

(**Figure 3b**) The incisional site was closed with separate 3-0 absorbable sutures and the patient was discharged at the same day. Histopathology report of the specimen confirmed a $3 \times 1.5 \times 1$ epidermoid cyst lined with stratified squamous epithelium containing keratinous debris. At one-month post-operative evaluation, genitourinary symptoms of the patient were all disappeared. Two-year follow up of the patient was satisfactory.

Case three: A 25-year-old virgin female patient presented with gradual swelling of the clitoral region since two years ago. She did not mention any history of genital trauma or hormonal treatment. She complained of urinary frequency and difficult voiding. In physical examination, we detected a 5×2 cm, round and slightly tender clitoral mass with surface ecchymosis. (**Figure 4**) There was no signs of hyperandrogenism. Routine blood tests seemed to be normal. Microscopic hematuria was found in urine analysis. Urine culture did not show urinary tract infection and urine cytology was negative for malignancy. Bladder and kidneys ultrasound study was normal. Under spinal anesthesia, the patient underwent cystourethroscopy which was normal. At the same session a supra-meatal inverted-U incision was made and the clitoral lesion excised completely. The histopathology report revealed a $5 \times 1.5 \times 1$ epidermoid cyst of the clitoris. Urinary symptoms of the patient were disappeared in one-month post-operative visit. Sensory content of the clitoral region was preserved and there was no visible scar tissue at the surgical incision site. In four years follow up course, there was no recurrence at the surgical area. The patient had sexual intercourse and she did not mention any problems.

DISCUSSION

Tumors of the clitoris are uncommon. They include a variety of benign, malignant, and rarely metastatic lesions.⁽⁵⁾ Female external genitalia may have a multitude of cysts. Such cysts can be vaginal (hymenal), para-urethral, or clitoral. Clitoral cysts are most infrequent of these. They are usually presented as painless, soft, and mobile mass in the absence of any virilization sign.⁽⁶⁾ EPCs of the clitoris are commonly seen after type I genital mutilation/female circumcision performed in some ethnic communities in Africa and West Asia.⁽⁷⁾ Pure adult spontaneous EPCs without infibulation, genital cutting, or piercing are extremely rare.⁽⁸⁾ Three cases of primary EPC of the clitoris following contraceptive implants or pills have been reported.^(1,8,9)

Only one case of pregnancy-associated clitoral epidermoid cyst has been described by Jing W. Hughes et al.⁽¹⁰⁾ To our best knowledge, three cases of primary EPC of the clitoris non-related to any medication, genital trauma, or pregnancy in adult females have been reported in the literature.^(6,7,11)

Pre-operative evaluation of the patients in the literature consisted of hormonal and chromosomal analysis, abdominopelvic or trans-vaginal ultrasonography, or even pelvic MRI.^(1,3,5,7,12) In our opinion, in the absence of hyperandrogenism signs, these types of lesions should be differentiated from clitoromegaly. Therefore, a detailed history and performing a complete physical examination before the surgical removal would be the only required course of action. Imaging studies will not add further essential information and should be restricted to complicated situations. Knowing the anatomy of the vulva and clitoris is critical prior to performing any

kind of surgery. The major goals of surgery involving the clitoris include preservation of sensory function for future sexual health and restoration of normal anatomy. Various surgical techniques in management of clitoromegaly have been described, previously.⁽¹²⁾ Cystectomy with total clitoridectomy was the surgical option as described by some authors.⁽⁴⁾ However, this resulted in significant sensory loss. We believe a supra-meatal inverted – U incision is a very safe approach toward the clitoral lesions. The clitoral body is substantial in length, mostly lying superficially under the clitoral hood and mons pubis. The dorsal nerves of the clitoris are large and superficial, terminating at or near the base of the clitoral glans.⁽¹³⁾ Regarding the superficial location of the terminal branches of the dorsal clitoral nerve, performing the surgical incision over the clitoral skin may harm these structures. Almost all reported cases made vertical, elliptical or inverted – V incision over the clitoral skin, clitoral hood, or the cyst itself.^(2,7,11,14) In supra-meatal approach, we can safely preserve the neurovascular bundle of the clitoris. There would be no need to trimming the skin, or reconstruction of labia minora or clitoris. Excellent cosmetic results, no scar formation, and preserving the tactile and sexual sensation are the advantages of this approach. Special care should be given to the urethra. Insertion of a urethral catheter and meticulous dissection should be considered. Complete surgical removal of the clitoral cysts is the ideal therapeutic approach and definite diagnosis is made by histopathology report. In case one a focal point of tubal metaplasia including ciliated cells was identified on microscopic examination. The origin of cysts lined by ciliated or mucinous epithelium, is debated, and they may be of Müllerian, Wolffian, or urogenital sinus origin, or may represent metaplasia or heterotopia.⁽¹⁵⁾ This is the first report of primary EPC of the clitoris with focal ciliated tubal metaplasia.

CONCLUSIONS

Even though the primary EPC of the clitoris in female adult population is very rare, it should be considered as one of the differential diagnosis of any soft, non-tender and mobile mass of the clitoris. In the absence of hyperandrogenism signs, a detailed medical history and careful physical examination facilitates the diagnosis and prevents unnecessary hormonal or chromosomal analysis. In most cases, imaging studies would not add further helpful information and should be performed only in complicated cases. Since the definitive diagnosis is made by histopathology, immediate surgical excision would be a complete diagnostic and therapeutic approach of these lesions. A supra-meatal inverted-U incision will provide a safe access to the clitoral masses without compromising the neurovascular bundle of the clitoris.

CONFLICT OF INTEREST STATEMENT

The authors declare that there is no conflict of interest.

REFERENCES

1. Fedele L, Fontana E, Bianchi S, Frontino G, Berlanda N. An unusual case of clitoromegaly. Letters to the Editor. Eur J Obstet Gynecol Reprod Biol. 2008; 140: 287-288.
2. Celik N, Yalcin S, Gucer S, Karnak I. Clitoral epidermoid cyst secondary to blunt trauma in a 9-year-old child. Turk J Pediatr. 2011; 53:108.
3. Anderson-Muellar BE, Laudenschlager MD, Hansen KA. Epidermoid cyst of clitoris: An unusual case of clitoromegaly in a patient without history of previous female circumcision. J Ped Adolesc Gynecol. 2009; 22: e130.
4. Al-Ojaimi EH, Abdulla MM. Giant epidermoid inclusion cyst of the clitoris mimicking clitoromegaly. J Low Genit Tract Dis. 2013;17:58-60
5. Schmidt A, Lang U, Kiess W. Epidermal cyst of the clitoris: a rare cause of clitorimegaly. Eur J Obstet Gynecol Reprod Biol. 1999; 87: 163-165.
6. Arun Nayak, Meenal Sarmalkar, Madhuri Mehendale, Shrutika Shah. Spontaneous nontraumatic epidermoid cyst of the clitoris: a rare case report. Int J Reprod Contracept Obstet Gynecol. 2015 Dec; 4:2081-2083.
7. Vandana Bhuria, Vani Malhotra, Smiti Nanda, Meenakshi Chauhan, Bhawana Goel. Epidermoid Cyst of the Clitoris: An Unusual Case. J Gynecol Surg. Volume 30, Number 1, 2014.
8. Lambert B. Epidermoid cyst of the clitoris: a case report. J Low Genit Tract Dis 2011; 15:161Y2.
9. Robin G. Marcelli F. Agberta N. Guerin Du Masgenet B. Goeusse P. Contribution of sonography to the diagnosis of non-hormonal acquired clitoromegalia: a case report. Ann Endocrinol (paris). 2006; 67:613-6.
10. Jing W. Hughes, Marsha K. Guess, Adam Hittelman, Sallis Yip, John Astle, Lubna Pal, Silvio E. Inzucchi, Antonette T. DulayClitor. Epidermoid Cyst Presenting as Pseudoclitoromegaly of Pregnancy. AJP Rep. 2013; 3: 57–62.
11. Linck D, Hayes MF. Clitoral cyst as a cause of ambiguous genitalia. Obstet Gynecol. 2002; 99: 963966.
12. Johnson LT, Lara-Torre E, Murchison A, Garcia EM. Large epidermal cyst of the clitoris: a novel diagnostic approach to assist in surgical removal. J Pediatr Adolesc Gynecol. 2013 Apr; 26: e33-5.
13. Joseph A Kelling, Cameron R Erickson, Jessica Pin, Paul G Pin. Anatomical Dissection of the Dorsal Nerve of the Clitoris. Aesthet Surg J. Volume 40, Issue 5, May 2020, Pages 541–547.
14. Cindy Wu, Lynn Damitz, Kimberly M. Karrat, Alice Mintz, Kalyani Avva, Dennis Zolnoun. Clitoral Epidermal Inclusion Cyst Resection with Intra-operative Sensory Nerve Mapping Technique. Female Pelvic Med Reconstr Surg. 2016; 22: e24–e26.
15. Heller, Debra. Benign Tumors and Tumor-like Lesions of the Vulva. Clin Obstet Gynecol. 2015; 58: 526-535.