

# Laparoscopic Distal Ureterectomy and Boari Flap Ureteroneocystostomy for a Low-Grade Distal Ureteral Tumor

Abbas Basiri,<sup>1</sup> Hossein Karami,<sup>1</sup> Sadrollah Mehrabi,<sup>2</sup> Ahmad Javaherforooshzadeh<sup>1</sup>

*Keywords: laparoscopy, ureteral neoplasms, reconstructive surgical procedures, surgical flaps*

*Urol J. 2008;5:120-2.  
www.uj.unrc.ir*

## INTRODUCTION

Boari flap construction and ureteroneocystostomy is an appropriate technique for repairing the injuries in the distal ureter that result in shortening of the ureter.<sup>(1)</sup> We report the use of laparoscopic distal ureterectomy consisting resection of the bladder cuff and Boari flap construction in a patient with low-grade transitional cell carcinoma of the distal ureter.

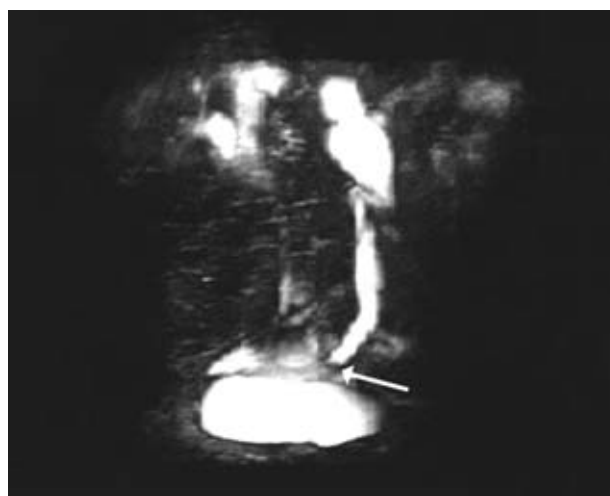
## CASE REPORT

A 52-year-old man was referred to our center with 4-month left flank pain and gross hematuria. Physical examination and urine and blood tests revealed no abnormality. On ultrasonography, left hydroureteronephrosis and a hyperechoic mass in the left distal ureter were detected. A solid mass was also seen on computed tomography and magnetic resonance urography (Figure 1). Urine cytology was reported positive for malignancy. Ureteroscopy revealed an obstructive nodular mass 3 cm

above the left ureteral orifice. Cold-cup biopsy was done and pathology examination showed a low-grade transitional cell carcinoma. Metastatic workup was also uneventful. Due to impossibility of endoscopic resection, the patient was selected for laparoscopic ureterectomy.

## TECHNIQUE

In the flank position, 4 ports (a 10-mm umbilical trocar, two 5-mm trocars, and one 10-mm working trocar) were inserted in a diamond-shaped area in the left lower quadrant. After releasing the ureter, 2 hemolocks were



**Figure 1.** Magnetic resonance urography showed marked narrowing of the distal segment of the left ureter due to tumor (arrow).

<sup>1</sup>Urology and Nephrology Research Center and Department of Urology, Shahid Labbafinejad Hospital, Shahid Beheshti University (MC), Tehran, Iran

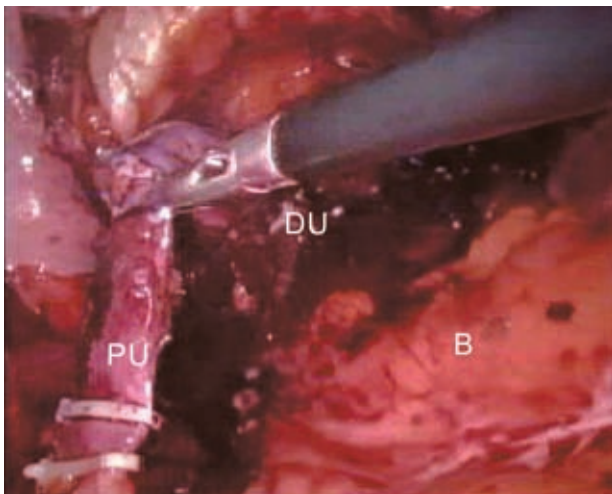
<sup>2</sup>Department of Urology, Yasuj University of Medical Sciences, Yasuj, Iran

Corresponding Author:  
Abbas Basiri, MD

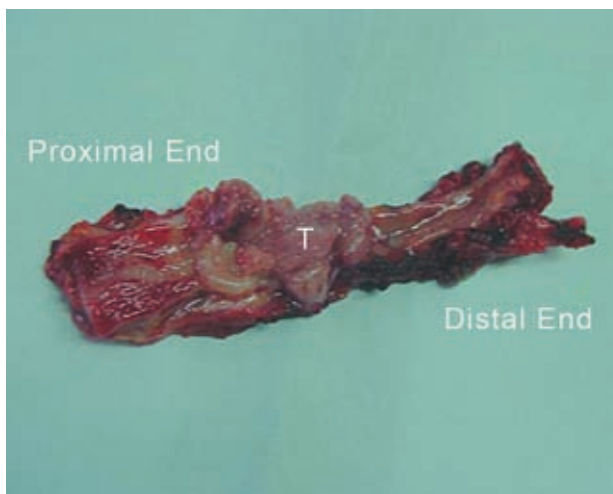
Urology and Nephrology Research Center, No 44, 9th Boustan, Pasdaran, Tehran 1666668111, Iran  
Tel: +98 21 2256 7222  
Fax: +98 21 2256 7282  
E-mail: basiri@unrc.ir

Received October 2007  
Accepted March 2008

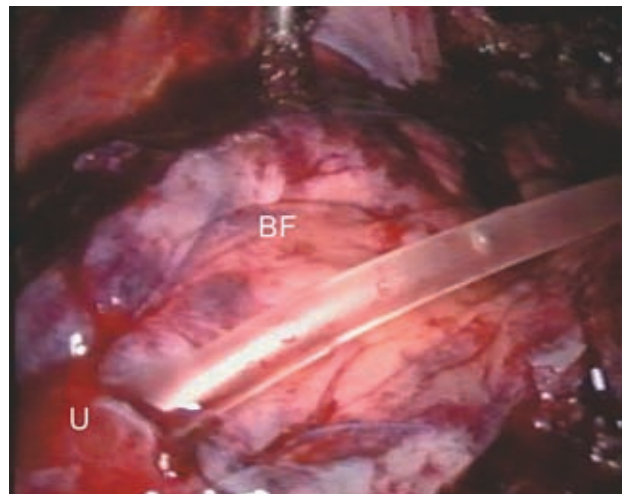
used in the proximal and 1 in the distal parts of the mass to prevent the spillage of the tumor (Figure 2). The ureteral defect was repaired by a Boari flap. The bladder was cut from the anterior surface towards the left orifice, and the ureter was separated from the bladder with 1-cm margins. The ureter was then cut from 2 cm above the proximal part of the tumor, and the sample containing a tumoral ureter and bladder cuff was removed (Figure 3). The flap was fixed to the ventral surface of the psoas muscle by a 2-0 vicryl suture. The frozen section was negative for tumor. The ureter was anastomosed end to end to the bladder flap using a 4-0 vicryl suture on a 10-F catheter (Figure 4). The bladder was also repaired



**Figure 2.** Intra-operative picture shows distal segment of the ureter containing tumor. PU, indicates proximal ureter; DU, distal ureter; and B, bladder.



**Figure 3.** Tumoral segment of the ureter. T indicates tumor.

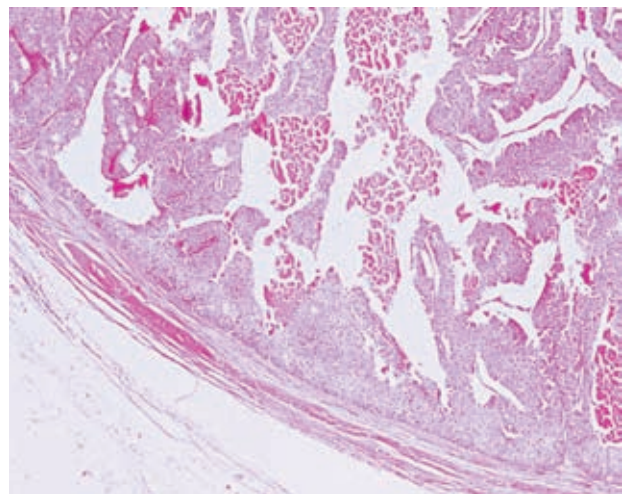


**Figure 4.** Intra-operative picture shows bladder flap with the anastomosed ureter and ureteral stent. U indicates ureter and BF, bladder flap.

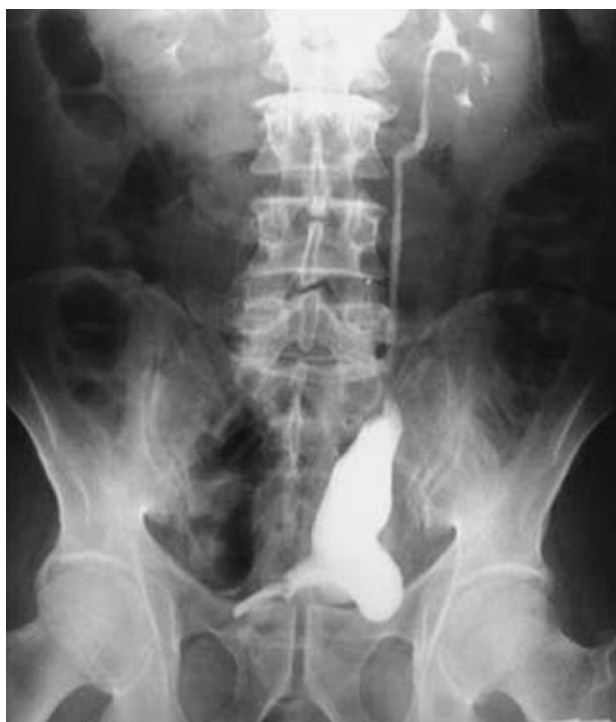by 2-0 vicryl suture. A drain was inserted and the operation was ended after 406 minutes without complications.

## RESULTS

The amount of bleeding was about 300 mL and the hospitalization period was 5 days. The pathology report showed a low-grade tumor with the staging of T1N<sub>x</sub>M<sub>x</sub> and tumor-free margins (Figure 5). Three months postoperatively, intravenous urography showed palliation of the hydronephrosis with negative urine cytology (Figure 6).



**Figure 5.** Low-grade and low-stage transitional cell carcinoma was reported (T1N<sub>x</sub>M<sub>x</sub>) on pathologic examination of the ureteral specimen (hematoxylin-eosin, × 10).



**Figure 6.** Intravenous urography 3 months after the operation.

## DISCUSSION

Minimally invasive methods have been properly used for treatment of tumors of the distal ureter. In patients with low-grade tumors, recurrence rates and disease-specific survival rates are 26% to 28% and 96% to 100%, respectively.<sup>(2)</sup> The use of laparoscopy has been reported by Gerber and colleagues as distal ureterectomy and ureteroneocystostomy.<sup>(3)</sup> Also there are some reports addressing laparoscopic Boari flap for treatment of benign ureteral lesions. In a retrospective study by Simmons and colleagues,<sup>(4)</sup> the results of laparoscopic and open ureterectomy, ureteroneocystostomy, and Boari flap reconstruction were compared between 12 laparoscopic and 34 open surgeries for ureteral stricture. Patients with open surgery

had greater operative blood loss (258 mL versus 86 mL) and longer hospital stay (mean, 5 days versus 3 days) compared with the laparoscopic group. The overall complication rate in the open and laparoscopic groups were 15% and 8%, respectively ( $P = 0.22$ ). Ureteral patency was successfully reestablished in all the 12 patients in the laparoscopic group compared to 96% in the open group at a mean follow-up of 23 months.<sup>(4)</sup> In our case, as Boari flap construction was planned preoperatively, we cut the bladder up to the ureteral orifice to make a flap; therefore this incision helped us to have excellent intravesical exposure for incising 1 cm of the bladder wall as a bladder cuff. To our best knowledge, laparoscopic ureterectomy and Boari flap construction has not been used for the treatment of ureteral tumors. According to our findings, laparoscopic ureterectomy and Boari flap construction promises ease in the operation, less morbidity, and enough exposure for cutting the distal ureter and bladder cuff.

## CONFLICT OF INTEREST

None declared.

## REFERENCES

1. Fergany A, Gill IS, Abdel-Samee A, Kaouk J, Meraney A, Sung G. Laparoscopic bladder flap ureteral reimplantation: survival porcine study. *J Urol.* 2001;166:1920-3.
2. Soderdahl DW, Fabrizio MD, Rahman NU, Jarrett TW, Bagley DH. Endoscopic treatment of upper tract transitional cell carcinoma. *Urol Oncol.* 2005;23:114-22.
3. Gerber E, Dinlenc CZ, Wagner JR. Laparoscopic distal ureterectomy for low grade transitional cell carcinoma. *J Urol.* 2003;169:2295.
4. Simmons MN, Gill IS, Fergany AF, Kaouk JH, Desai MM. Laparoscopic ureteral reconstruction for benign stricture disease. *Urology.* 2007; 69:280-4.