

Anterior Urethral Advancement as a Single-Stage Technique for Repair of Anterior Hypospadias: Our Experience

Venkat A. Gite, Jayant V. Nikose,* Sachin M. Bote, Saurabh R. Patil

Purpose: Many techniques have been described to correct anterior hypospadias with variable results. Anterior urethral advancement as one stage technique was first described by Ti Chang Shing in 1984. It was also used for the repair of strictures and urethrocutaneous fistulae involving distal urethra. We report our experience of using this technique with some modification for the repair of anterior hypospadias.

Materials and Methods: In the period between 2013-2015, 20 cases with anterior hypospadias including 2 cases of glanular, 3 cases of coronal, 12 cases of subcoronal and 3 cases of distal penile hypospadias were treated with anterior urethral advancement technique. Patients' age groups ranged from 18 months to 10 years. Postoperatively, patients were passing urine from tip of neomeatus with satisfactory stream during follow up period of 6 months to 2 years.

Results: There were no major complications in any of our patients except in one patient who developed meatal stenosis which was treated by periodic dilatation. Three fold urethral mobilization was sufficient in all cases.

Conclusion: Anterior urethral advancement technique is a single-stage procedure with good cosmetic results and least complications for anterior hypospadias repair in properly selected cases.

Keywords: advancement; anterior urethra; hypospadias; urethral mobilization; urethrocutaneous fistula.

INTRODUCTION

Most (65-70%) hypospadias cases occur in anterior while 30% are in posterior urethra.⁽¹⁾ Urethral reconstruction represents a great challenge in urologic surgeries.⁽²⁾ Many techniques have been demonstrated to treat anterior hypospadias. One of these is anterior urethral advancement, first described by Ti Chang Shing in 1984.⁽³⁾ Later on various experiences have been reported for urethral advancement as a treatment of hypospadias with some drawbacks.⁽¹⁾ The aim of this study was to modify this technique and assess the results with our modification.

MATERIALS AND METHODS

Study Population

A total of 20 patients of anterior hypospadias were treated during the period between June 2013 to December 2015 by anterior urethral advancement technique. Inclusion criteria: Cases who presented with varying degrees of anterior hypospadias.

Exclusion criteria: Patients with hypoplastic distal urethra, severe chordee, mid penile and proximal penile hypospadias were excluded from this study.

The preoperative meatal sites were glanular in 2 cases, coronal in 3 cases, subcoronal in 12 cases and distal penile in 3 cases. Commonest age group was 2-5 years in 10 cases (50%). Sixteen cases were non-circumcised and 4 were circumcised. All patients were subjected to history, general and local examination of genitalia and coagulation profile.

Surgical technique

All patients were operated under general anesthesia. A 6/0 traction suture was placed at the tip of glans penis. Feeding tube was introduced into urethra (**Figure 1**). Distance between hypospadiatic meatus and tip of glans was measured and recorded (**Figure 2**). Circumcising incision, 5mm proximal to coronal sulcus with 'U' shaped extension proximal to hypospadiatic meatus on ventral aspect was made. Degloving of skin down to penoscrotal junction was done to release cutaneous chordee. Dissection of urethra started in proximal area in avascular plane and was maintained above the tunica albuginea covering each corpus cavernosum medially till reaching beneath the corpus spongiosum upto the hypospadiatic meatus (**Figure 3**). After 2/3rd mobilization of urethra in spite of deep vertical or transverse glanular slit, we excised 1-2mm rim of ventral glanular mucosa in full depth along with strip of urethral plate (Our Modification) so that there was adequate space to accommodate the urethra. Trimming of distal urethra in oblique fashion about 2mm more on ventral aspect was done. Two Glanular wings were satisfactorily mobilized laterally. Tension free anastomosis was accomplished from urethra to glans with interrupted sutures. Two Glans wings were closed in two layers over the urethra (**Figure 4**). Intermittent fixation sutures were taken between tunica albuginea of corpus cavernosa and corpus spongiosum. Bayer's flap and closure of skin was done.

Urethral feeding tube was secured with glanular retention sutures (**Figure 5**). Dressing was applied. All

Department of Urology, Grant Govt. medical college and Sir J.J. group of hospitals, Mumbai, Maharashtra, India.

*Correspondence: Saikrupa, H-21, Tirupati Supreme Enclave, Jalan nagar, Aurangabad. 431005.

Phone- 90116546446. Email: balajigite@yahoo.com.

Received May 2016 & Accepted January 2017

Table 1. Demographic and operative data.

	Variables	No. of Patients
Distance between hypospadiatic meatus to tip of glans	< 0.5 cm	2
	0.5-1 cm	15
	1.1-2 cm	3
Site of hypospadiac meatus	Glanular	2
	Coronal	3
	Subcoronal	12
	Distal penile	3
Age Groups	1-1.9 Years	8
	2-4.9 years	10
	5-10 years	2
Complications	Meatal stenosis	1

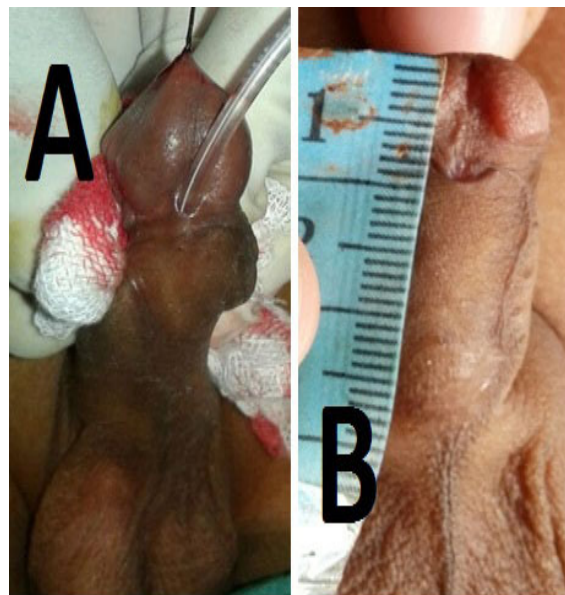

Figure 1. (a): Pre Op image with feeding tube; **(b):** Measurement of urethral plate.

patients received broad spectrum antibiotics and anti-inflammatory drugs for seven days. Proximal urinary diversion was not used in any of our cases. Feeding tube was removed on 10th postoperative day .

and good urinary stream).

RESULTS

All patients passed urine from the tip of the penis with good stream after removal of per urethral feeding tube. Three fold urethral mobilization (the distance between hypospadiatic meatus to tip of the glans penis) was sufficient to achieve tension free anastomosis in all cases (**Table 1**). The extent of advancement of urethra ranged from 0.5 to 2 cm. None of the patients had major complications like stricture, dehiscence or fistula, except one case which had meatal stenosis which occurred during our early experience (**Table 1**). The long term outcome was satisfactory with regards to functional and cosmetic aspect (Adequate sized meatus at tip of glans

DISCUSSION

For anterior hypospadias, the improvement in the cosmetic appearance of penis is the most important indication for surgery.⁽⁴⁾ Many techniques have been described to correct anterior hypospadias.⁽⁵⁾ The goal of hypospadias repair is to have functionally and cosmetically normal penis.⁽¹⁾ The preoperative meatal sites were glanular in 2 cases, coronal in 3 cases, subcoronal in 12 cases and distal penile in 3 cases (**Table 1**). Common age group was 2-5 years in 10 cases (**Table 1**). Sixteen cases were non-circumcised and 4 were circumcised. Various techniques used to treat anterior hypospadias have their own drawbacks like breakdown of repair due

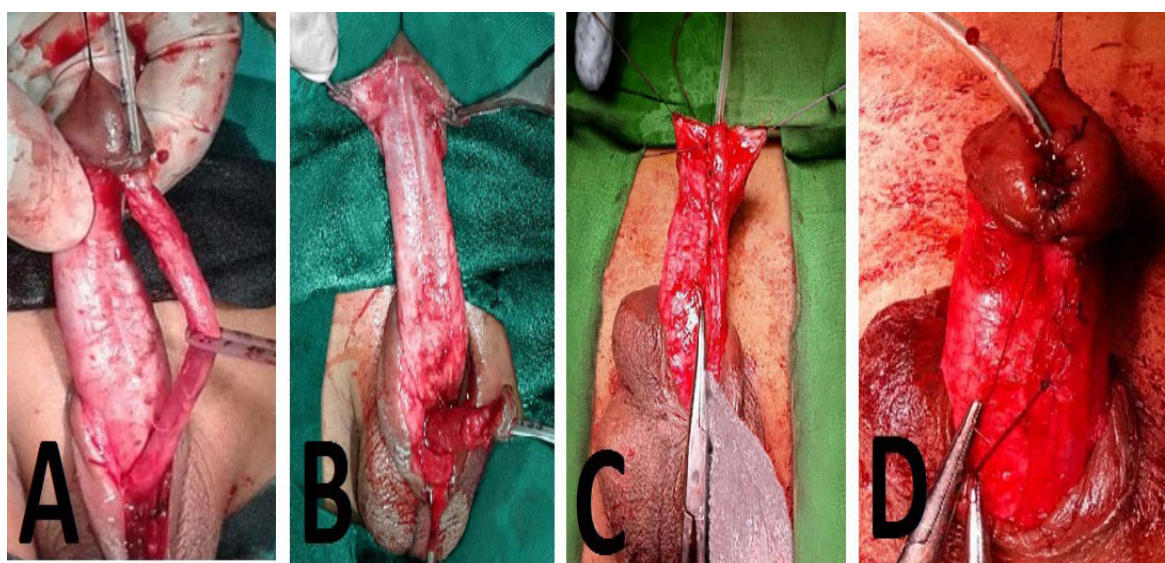


Figure 2. (a): Dissection of urethra in proximal area; **(b):** Excision of ventral glanular mucosa with urethral plate; **(c):** Intermittent fixation sutures between tunica and corpus cavernosa and spongiosa; **(d):** Glans wings closed in layers.

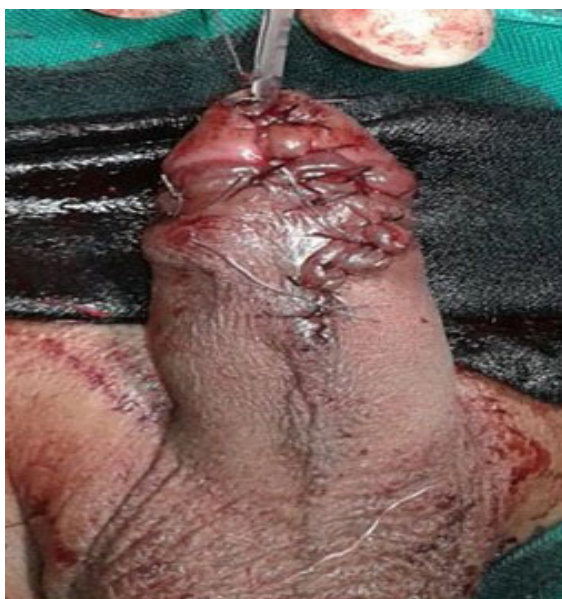

Figure 3. Postoperative image.

to precarious blood supply in Mathieu, meatal regression and stenosis in meatal advancement and glanuloplasty (MAGPI). Results of tubularised incised plate urethroplasty (TIPS) repair depend on various factors like characters of urethral plate, together with an incidence of disruption, fistula and meatal stenosis.⁽¹⁾

Urethral advancement is considered as a good single-stage technique for distal hypospadias repair,⁽²⁾ but the main drawback for this technique was meatal stenosis and need for high degree of expertise of the surgeon to dissect the urethra without causing any injury.⁽³⁾ Various methods used to decrease meatal stenosis are vertical and horizontal slitting of the glans, tunneling of the glans using hair transplant apparatus, and trimming of urethra in an oblique fashion about 1 to 2 mm more



Figure 4. Voiding photo with satisfactory stream at 6 months follow up.

on vertical aspect.⁽³⁾

In all our cases, the entire urethral plate was made free from corpora in glanular area by cutting 1 to 2 mm rim of ventral glanular mucosa in full depth with satisfactory lateral mobilization of glanular wings which is not described in other series, along with oblique spatulation of urethra. By this technique, in our series only one patient developed meatal stenosis which happened during early phase of our experience. This was resolved by twice weekly dilatation with feeding tube under local anesthesia for two weeks.

Urethral mobilization should be started proximally where urethra is surrounded by spongiosa all around and not distally where spongiosa tissue splayed laterally.⁽¹⁾ Threefold urethral mobilization can provide tension free urethral anastomosis in patients with anterior hypospadias as observed in our series,⁽⁵⁾ however Atala et al. described 4 to 5 fold urethral mobilization to provide tension free urethral anastomosis. This difference may be due to inclusion of mid shaft hypospadias cases in their series.⁽⁶⁾

The extent of urethral advancement in our series ranged from 0.5 to 2 cm, matching with other series where maximum urethral advancement was 1.5 cm,⁽⁷⁾ 2.1 cm,⁽¹⁾ and 2.5 cm.⁽⁸⁾ Average operative time to dissect urethra in our series was 40 minutes matching with 30 to 60 minutes described by Awad et al.⁽³⁾ We did not employ proximal diversion except per urethral feeding tube which was kept for 10 days. Stenting or urinary diversion is unnecessary after distal hypospadias surgery.⁽⁶⁾

Urethral advancement for distal hypospadias repair has variable incidence of fistula ranging from less than 1% to 16.7%.⁽²⁾ In our series postoperative fistula was not recorded as we had fixed the healthy distal end of urethra to the tip of glans penis after excision of unhealthy distal 2 mm of urethra, with meticulous dissection of urethra without injuring it. Absence anastomosis between urethra and the neo-urethra may also be the reason for absence of fistula.

In our series patients were followed up from 6 months to 2 years with respect to site and size of the meatus, caliber of urinary stream, presence of fistula and chordee. All patients had cosmetically and functionally normal penis with 100 % success rate in our series by this technique with our modification except one case who developed meatal stenosis which was resolved by meatal dilatation. In a series of Aawad et al., 3.9 % patients developed meatal stenosis which was resolved by dilatation.⁽³⁾

Anterior urethral advancement with our modification is easy to learn, rapid procedure and gives excellent results. However, limitation of our study is small number of cases and technique applied to a selected group of patients.

CONCLUSIONS

Anterior urethral Advancement technique is a single-stage procedure with best cosmetic results with least complications for anterior hypospadias in properly selected cases.

CONFLICT OF INTREST

None of the contributing authors have any conflict of intrest, including specific financial interests or relationships and affiliations relevant to the subject matter or

materials discussed in the manuscript.

REFERENCES

1. Alaa El-Din A.M. El- Moghazy, H.M. Hammouda, Y.S. Hassan, A.M. Abdelateef, M.A. Elgammal. Further Experience with Urethral Advancement for Anterior Hypospadias Repair. *Egypt J. Plast. Reconstr. Surg.* 2009; 33: 119-22.
2. M.M.El-Saadi, Adel M. Tolba, Abd- Eirahman Sarhan. Anterior Urethral Advancement in Repair of Hypospadias: A Modification of the Technique. *Annals of Paediatric Surgery.* 2010; 6: 18-21.
3. Mohamed M. S. Awad. Urethral Advancement Technique for Repair of Distal Penile Hypospadias: A Revisit. *Indian J Plast Surg.* 2006; 39: 34-8.
4. Yves Heloury, Earl Y. Cheng. Distal Hypospadias: Circumcision vs Preputial Reconstruction. *J Urol.* 2014; 191: 17-9.
5. Youssef Saleh Hassen, Atef Mohamed Abdelateef. New Concept in Urethral Advancement for Anterior Hypospadias. *Egypt J Plast Reconstr Surg.* 2008; 32: 223-7.
6. Atala A. Urethral Mobilization and advancement for mid shaft to distal hypospadias. *J Urol.* 2002; 168: 1738.
7. Haberlik A., Schmidt B., Uray E., Mayr J. Hypospadias repair using a modification of Beck's operation: Follow-up. *J Urol.* 1997; 157: 2308.
8. Koff S.A. Mobilization of the urethra in the surgical treatment of hypospadias. *J Urol.* 1981; 125: 394.