

## Adult Ureterocele Presenting with Ureteral Obstruction and Urosepsis during Pregnancy

Catherine R Harris,<sup>1</sup> Amjad Alwaal,<sup>1,2\*</sup> Glen Yang,<sup>1</sup> Michael L Eisenberg,<sup>1</sup> Benjamin N Breyer<sup>1</sup>

**Keywords:** pregnancy; ureterocele; adult; female; hydronephrosis; pathology.

### INTRODUCTION

Ureteroceles are cystic dilatations of the distal ureter that occur due to congenital ureteric wall weakness.<sup>(1)</sup> They can be orthotopic, occurring in normal ureteric locations and most commonly seen in adults. On the other hand, heterotopic ureteroceles are located in ectopic ureters or in ectopic duplex renal systems, and are more common in children.<sup>(2)</sup> Ureterocele causing obstruction in adults is less commonly reported. There are few case reports and small case series in the adult population that describe ureteral obstruction from ureteroceles,<sup>(3-5)</sup> and only one published report of a ureterocele presenting as prolapsed mass containing stones during pregnancy.<sup>(6)</sup> We describe a report of an adult presenting with an obstructing ureterocele and urosepsis during pregnancy. The ureterocele was successfully extirpated cystoscopically without radiation exposure to mother or fetus. We also review the varied presentations and management of obstructing ureteroceles in adults who have presented at our institution.

### CASE REPORT

A 35 year-old woman gravida 5 para 2 at 22 weeks gestation presented to the emergency room with fevers and right flank pain. She was febrile to 39.0°C, tachycardic at 120/min, with stable blood pressure. On physical examination she had right costovertebral angle tenderness. Laboratory results revealed a leukocytosis of  $19 \times 10^9/L$  and creatinine of 0.5 mg/dL. Her urinalysis with microscopy was positive for pyuria and bacteriuria. Renal-bladder ultrasound showed moderate right hydroureter (grade 3) proximal and distal to the gravid uterus as well as a ureterocele at the ureterovesical junction (**Figure 1**). The patient was otherwise healthy, with a history of a single urinary tract infection 2 years ago while not pregnant.

### Surgical Technique

The patient was taken emergently to the operating room for endoscopic ureteral decompression. Cystoscopy was performed which showed a 3 cm right ureterocele. A ureteral orifice was not apparent, and a guidewire was unable to be passed into the ureter. Urine efflux was not visualized. An attempt to puncture the thick walled ureterocele with the Bugbee electrode (Medline Industries, Mundelein, IL, USA) was unsuccessful. A Collins knife (STORZ, Tuttlingen, Germany) was then used to incise the ureterocele. After extirpation with the Collins knife, we were able to visualize what appeared to be a ureteral orifice at the lateral extend of the ureterocele (**Figure 2**). A guidewire and 5-French ureteral exchange catheter passed through the ureteral orifice easily. We placed then a temporary

**Table.** San Francisco general hospital experience with adult ureteroceles 1996-2015.

Age (years)	Sex	Presenting Symptom	Diagnostic Imaging	Laterality	Type of System	Associated Stone	Surgical Technique
35	F	Pyelonephritis	Ultrasound	Right	Single, orthotopic	No	Incision
61	M	Pyelonephritis	CT, IVP	Bilateral	Single, orthotopic	Yes	Excision, laser lithotripsy, stent
27	F	Flank pain	CT, DMSA	Left	Duplicated, ectopic	No	Heminephrectomy
26	F	Recurrent UTI	Ultrasound	Left	Single, orthotopic	No	Incision
68	F	Recurrent UTI	CT	Left	Single, orthotopic	No	Incision
22	M	Recurrent UTI	CT	Left	Single, orthotopic	No	Open excision, ureteral reimplantation

**Abbreviations:** M, male; F, female; CT, computed tomography; IVP, intravenous pyelography; DMSA, dimercaptosuccinic acid; UTI, urinary tract infection.

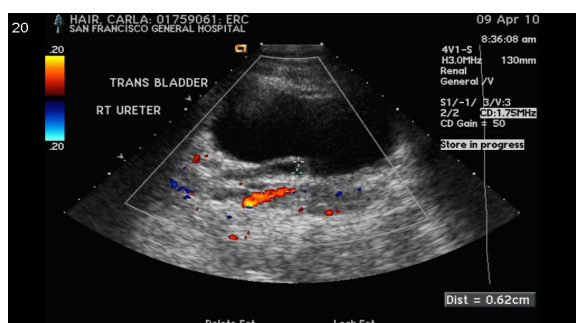
<sup>1</sup> Department of Urology, University of California, San Francisco, USA.

<sup>2</sup> Department of Urology, King Abdul Aziz University, Jeddah, Saudi Arabia.

\*Correspondence: 400 Parnassus Avenue A633, San Francisco, CA 94143-0738, USA.

Tel: +1 415 206 8805. Fax: +1 415 206 5153. E-mail: amjadwal@yahoo.com.

Received February 2015 & Accepted June 2015



**Figure 1.** Bladder ultrasound showing right ureterocele.

ureteral stent that was removed 4 weeks later.

### **Postoperative Course**

The patient defervesced and her pain resolved after the procedure. Her urine culture grew pansensitive *Escherichia coli*. She was discharged on post-operative day two with a two-week course of amoxicillin. One month after her procedure she had complete resolution of her symptoms and was afebrile with a white blood cell count of  $8 \times 10^9/L$ . Repeat ultrasound showed stable hydronephrosis and hydroureter bilaterally consistent with a 7-month pregnancy. Her creatinine was 0.4 mg/dL at baseline.

### **DISCUSSION**

Our experience with adult ureteroceles is extremely varied, as shown in **Table**. In the pediatric population, symptomatic ureterocele is related to a variety of complex congenital anomalies, such as duplex kidney, ectopic ureter and bladder outlet obstruction.<sup>(7)</sup> In contrast, adult ureteroceles are usually intravesical, small, and single system. Another difference between ureterocele according to age is the presence of calculi within the ureterocele. Calculi are commonly reported in adults, but are rare in children. It is likely that the formation of calculi over time from urinary stasis in an otherwise small asymptomatic ureterocele is the cause of delayed presentation of ureteroceles into adulthood. Increased estimated glomerular filtration rate and hydronephrosis from ureteral compression by the gravid uterus are well known physiologic and anatomic manifestations of pregnancy.<sup>(8)</sup> Physicians must therefore rely on clinical judgment to differentiate between physiologic and pathologic obstruction of the urinary system. The concern for fetal radiation also limits the use of more sensitive diagnostic imaging techniques such as computed tomography scan in determining the cause of obstruction. As this report demonstrates, it is important to carefully consider non-pregnancy related causes of obstruction in the pregnant population, such as ureterocele.

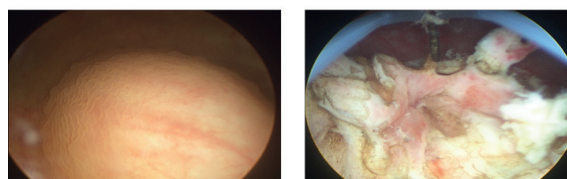
### **CONCLUSIONS**

In conclusion, this is the first report of an obstructing ureterocele in a pregnant woman. Therefore, ureterocele should be considered as a potential cause for obstruction in pregnant women.

### **CONFLICT OF INTEREST**

None declared.

### **REFERENCES**



**Figure 2.** Cystoscopy showing the ureterocele pre- and post-extermination.

1. Neufang KF MU, Beyer D. The roentgen diagnosis of ureterocele-with special reference to the simple orthotopic ureterocele in adults. *Rontgenblatter*. 1981;34:9-14.
2. Diard F CL, Bondonny JM, Elie G. Simple orthotopic ureteroceles in children. *J Radiol*. 1980;61:387-95.
3. Sinha RK, Singh S, Kumar P. Prolapsed ureterocele, with calculi within, causing urinary retention in adult female. *BMJ Case Reports*. 2014;2014.
4. Prakash J, Goel A, Kumar M, Sankhwar S. Stone in ureterocele peeping through ureteric orifice. *BMJ Case Reports*. 2013;2013.
5. Westesson K, Goldman H. Prolapse of a single-system ureterocele causing urinary retention in an adult woman. *Int Urogynecol J*. 2013;24:1761-3.
6. Scovell JM, Chan RC, Khavari R. Prolapse of a Single System Large Ureterocele Containing Multiple Stones in a Pregnant Woman. *Urology*. 2014;83:e3-e4.
7. Landi L EA, Adorisio O. Prolapsed vaginal ureterocele as a cause of urinary incontinence in a child. *Urol J*. 2015;12:1999-2000.
8. Hill CC, Pickinpaugh J. Physiologic Changes in Pregnancy. *Surgical Clinics of North America*. 2008;88:391-401.