

Case Reports

Endometriosis of the Urinary Tract: a Report of 3 Cases

SEYYED YOUSEF HOSSEINI, MOHAMMADREZA SAFARINEJAD*

Department of Urology, Shaheed Modarress Hospital, Shaheed Beheshti and Military Universities of Medical Sciences, Tehran, Iran

KEY WORDS: endometriosis, bladder, ureter, urinary tract, diagnosis

Introduction

Approximately 10% to 15% of premenopausal women are affected by endometriosis.⁽¹⁾ About 1% of women with endometriosis have urinary tract lesions, of which 84% involve the bladder.⁽²⁾ Because of insidious onset of endometriosis, this condition portends considerable morbidity, necessitating a high index of suspicion for both urologists and gynecologists.

We report 3 cases of endometriosis of the urinary tract with striking radiographic findings, and briefly review the literature on urinary tract endometriosis.

Case Report

Case 1

A 42-year-old woman presented with a 4-year history of dysuria, frequency, and urgency. She experienced exacerbation of dysuria and urinary frequency during her menses. Her past history was significant for 4 cesarean sections, latest of them was done 13 years ago. Several physicians had treated her for urinary tract infection, pelvic inflammatory disease, and cystitis. Serum and urine investigations were unremarkable. Excretory urogram (IVP) showed normal upper and lower urinary tracts. Ultrasonography was normal in non-menstruation days (fig. 1), but it revealed a 31 × 66 × 23 mm mass on the posterior bladder wall during menstruation (fig. 2). On cystoscopy in premenstrual days, a small nodule was seen. Punch biopsy from this lesion showed normal transitional cell epithelium

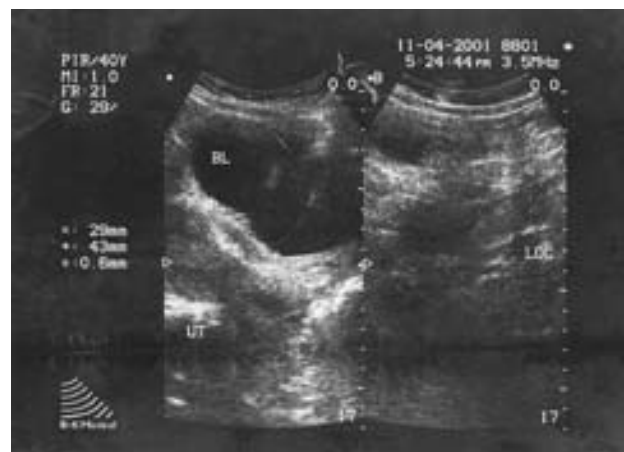

FIG. 1. Premenstrual transabdominal median longitudinal ultrasound scan of pelvis. The bladder has normal appearance.

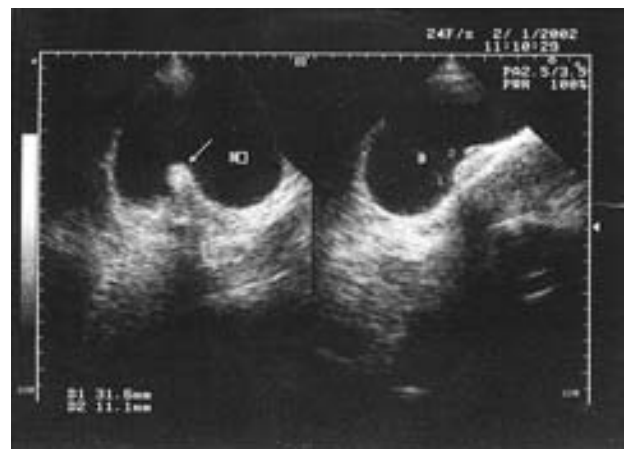


FIG. 2. Transabdominal median longitudinal ultrasound scan of pelvis during menstruation shows conical vegetation in posterior wall of the bladder (arrow).

with underlying vascular congestion of the submucosa. Cystoscopy during menstruation revealed a 3.0-cm pale pink nodular mass. On

Received December 2003

Accepted May 2004

*Corresponding author: P.O. Box: 19395-1849,

Tel: +98 912 109 5200, E-mail: safarinejad@unrc.ir

transurethral resection of this lesion, a chocolate-colored material was seen. The final pathologic report was bladder wall endometriosis.

Case 2

A 40-year-old woman presented with primary infertility. She complained of painful urination and suprapubic pressure. Prior urological evaluation at other centers included urine culture, pelvic and urinary tract ultrasound, and an office cystoscopic procedure. On cystoscopic inspection, a small submucosal bluish nodule had been reported. Punch biopsy from this nodule had showed severe nonspecific inflammation of bladder wall.

The patient underwent cystoscopy at our institute during her menses. A $0.5 \times 0.7 \times 1$ cm edematous, bluish, submucosal nodule covered with normal bladder mucosa was seen. Transurethral resection of the lesion revealed focal glandular formation within the muscular wall of the bladder. The glands were lined by flattened columnar epithelium and the pathologic diagnosis of that was bladder wall endometriosis.

Case 3

A 45-year-old lady presented with a history of left loin pain. The patient had a history of one cesarean section and one dilatation and curettage. Urine culture and cytology were negative.

Intravenous urography demonstrated severe left hydroureteronephrosis, but no evidence of urolithiasis (fig. 3). Retrograde ureterography confirmed the level and degree of obstruction (4 cm), but was not diagnostic. On cystoscopy in second day of her menses, a red polypoid mass protruding from the left ureteral orifice was seen. One year before, in an attempt for ureteral dilatation, this lesion had not been seen. The mass was resected. Histologic examination revealed ureteric endometriosis. Hysterectomy, bilateral oophorectomy, and left ureteroneocystostomy were performed. At 2 months, the patient was asymptomatic and both intravenous urography (fig. 4) and isotope renography confirmed complete resolution of the obstruction.

Discussion

Endometriosis of the urinary tract is rare, and the bladder is the most common site of involvement. Endometriosis usually occurs between menarche and menopause, because of the fluctuating levels of estrogen and progesterone

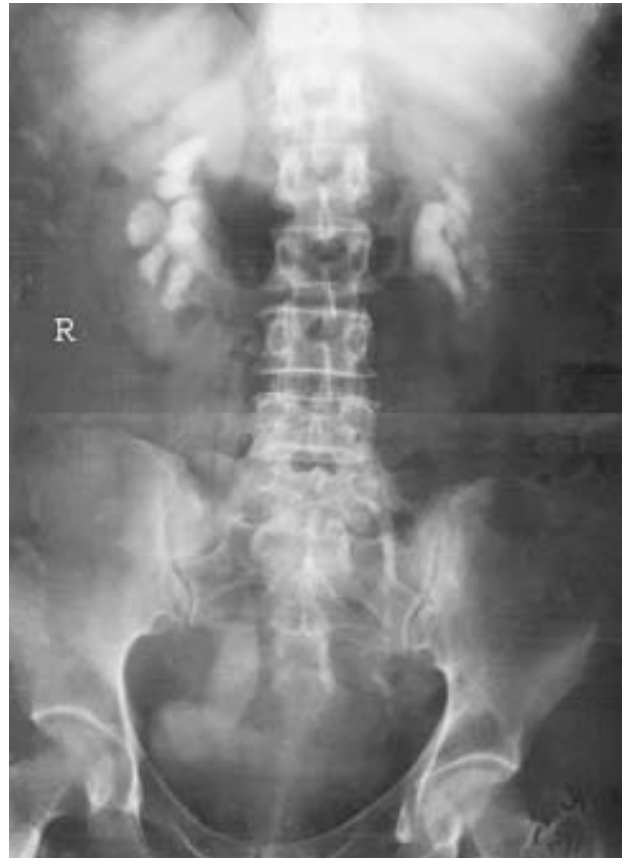

FIG. 3. Intravenous urogram demonstrating left severe hydroureteronephrosis with normal drainage of right system

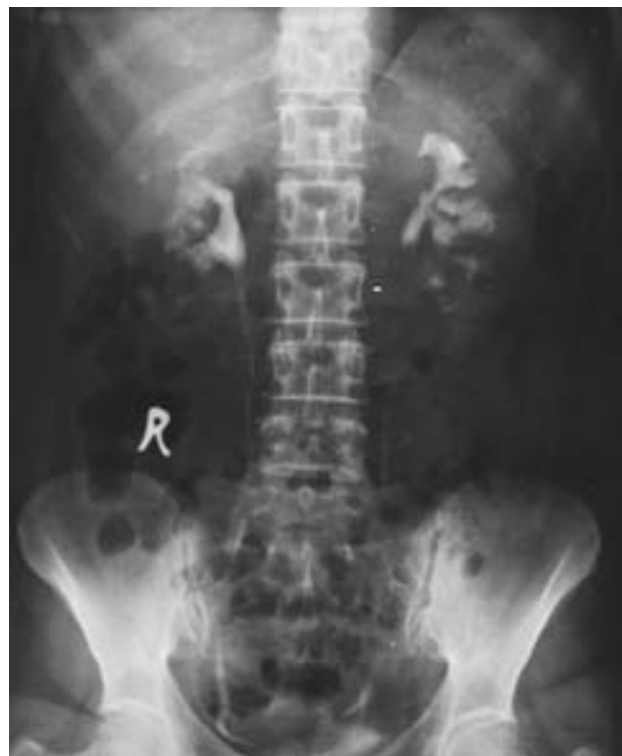

FIG. 4. Follow-up Intravenous urogram showing resolution of left upper tract dilatation after excision of the stricture and ureteroneocystostomy

required for stimulation and propagation of endometrial proliferation. Several theories have been proposed to explain the appearance of ectopic endometrium. Generally, these proposals regarding the origin of endometriosis are grouped as metaplastic, embryologic, and migratory. Most cases of endometriosis can be explained by the migratory theory developed by Sampson.⁽³⁾ Retrograde menstruation of viable endometrial tissue through the fallopian tubes during menstruation can allow endometrial glands to reach an ectopic position, e.g. bladder and ureter. Recently Jaques Donnez et al⁽⁴⁾ reported that primary bladder endometriosis must be considered as a retroperitoneal adenomyotic nodule, which is the consequence of metaplasia of müllerian rests.

Patients most commonly complain of suprapubic pressure and lower tract irritability with frequency and dysuria related to urination or bladder distention. Although cyclical gross hematuria is pathognomonic for vesical endometriosis, it is only present in 20% of patients.⁽⁵⁾ Patients with ureteric endometriosis can present with loin pain, symptoms of "cystitis", and pelvic discomfort.⁽⁶⁾ Early diagnosis and treatment of urinary tract endometriosis are necessary to avoid loss of kidney function.⁽⁷⁾ The incidence of silent loss of renal function resulting from ureteral endometriosis is reported to be as high as 25% to 43%.⁽⁸⁾

Urinalysis with cytologic examination, IVP, and computerized tomography are all non-specific for diagnosis of urinary tract endometriosis.⁽⁹⁾ Cystoscopy is the most valuable diagnostic procedure with vesical endometriosis.⁽¹⁰⁾ Bladder endometriosis varies both cystoscopically and histologically during the menstrual cycle and diagnosis can therefore be difficult.⁽¹⁰⁾ In our patients, cystoscopy was fortuitously performed during their menses. This made lesions more evident endoscopically. Premenstrually, there may be an increased elevation over the area of tumor surrounded by a congested, edematous mucosal membrane. As the endometrial tumor increases in size, during menstruation, the cystic areas develop an intensified bluish hue. The size of the mass or cysts and the color of the lesions increase prior to and during menstruation only to regress in mid-cycle. The final diagnosis is made by the pathologist, who can confirm endometrial glands and stroma in the specimen. A positive punch biopsy definitively documents

the presence of endometriosis, but a negative biopsy does not exclude it. Transurethral resection is usually diagnostic, but it is not recommended as a definite treatment, because any attempt at complete resection of the transmural involvement may result in bladder perforation.^(10,11)

Due to small and intramural nature of bladder endometriosis, it is better that imaging procedures such as ultrasound be performed during menstruation.

In an attempting to determine the appropriate therapy for vesical endometriosis, patient age, desire for reproduction, severity of symptoms, overall distribution of endometriosis, and size of the vesical lesion must be considered. Therapy for endometriosis includes bilateral oophorectomy, castration by radiation and drugs such as danazol or gonadotropin-releasing hormone agonists, as well as surgical resection of the lesion.⁽¹²⁾ For endometriosis of the urinary tract, treatment should be aimed primarily at elimination of the obstructive uropathy. Cases of diffuse endometriosis or large vesical lesions are more likely to require surgery for effective and definitive management. When the bladder lesion is small and the symptoms are not debilitating, it is appropriate to use hormone manipulation as a first time approach, especially in patients who have previously had children and desire some relief from symptoms before another pregnancy. However, such hormonal therapies do not recommend for obstructive uropathy because of the lack of response of fibrotic tissue to hormone suppression.⁽¹³⁾

Given the frequently prolonged diagnostic delay with related morbidity and erroneous treatments, we suggest a high index of suspicion of vesical endometriosis in all premenopausal women complaining of irritative urinary symptoms with negative urine cultures. Imaging and cystoscopy should be scheduled during or near a menstrual period to allow for the best chance of diagnosis. Punch biopsy usually does not provide appropriate tissue for definite diagnosis. Transurethral resection is usually diagnostic.

References

- 1- Hasson HM. Incidence of endometriosis in diagnostic laparoscopy. *J Reprod Med.* 1976;16:135-8.
- 2- Shook TE, Nyberg L M. Endometriosis of the urinary tract. *Urology.* 1988;31:1-6.
- 3- Ridley JH. The validity of Sampson's theory of

- endometriosis. *Am J Obstet Gynecol.* 1961;82: 777-82.
- 4- Donnez J, Spada F, Squifflet J, Nisolle M. Bladder endometriosis must be considered as bladder adenomyosis. *Fertil Steril.* 2000;74:1175-81.
 - 5- Batler RA, Kim SC, Nadler RB. Bladder endometriosis: pertinent clinical images. *Urology.* 2001;57:798-9.
 - 6- Patel A, Thorpe P, Ramsay JW, Shepherd JH, Kirby RS, Hendry WF. Endometriosis of the ureter. *Brit J Urol.* 1992;69:495-8.
 - 7- Nezhat C, Nezhat F, Nezhat CH, Nasserbakht F, Rosati M, Seidman DS. Urinary tract endometriosis treated by laparoscopy. *Fertil Steril.* 1996;66: 920-4.
 - 8- Stillwell TJ, Kramer SA, Lee RA. Endometriosis of the ureter. *Urology.* 1986;28:81-5.
 - 9- Schneider V, Smith MJ, Frable WJ. Urinary cytology in endometriosis of the bladder. *Acta Cytol.* 1980;24:30-3.
 - 10- Aldridge KW, Burns JR, Singh B. Vesical endometriosis: a review and two case reports. *J Urol.* 1985;134:539-41.
 - 12- Nezhat CR, Nezhat FR. Laparoscopic segmental bladder resection for endometriosis. *Obstet Gynecol.* 1993;81:882-4.
 - 13- Sampson JA. Peritoneal endometriosis due to the menstrual dissemination of the endometrial tissue into the peritoneal cavity. *Am J Obstet Gynecol.* 1927; 14:422-69.