

Percutaneous Nephrolithotomy in Horseshoe Kidney

Our 5-Year Experience

Masoud Etemadian,¹ Robab Maghsoudi,¹ Vafa Abdollahpour,¹ Mohsen Amjadi²

¹Hasheminejad Clinical Research Development Center (HCRDC), Iran University of Medical Sciences, Tehran, Iran
²Department of Urology, Tabriz University of Medical Sciences, Tabriz, Iran

Corresponding Author:

Robab Maghsoudi, MD
Department of Endourology, Hasheminejad Clinical Research Development Center (HCRDC), Valiasr Ave, Vanak Sq, Valinejad St, Tehran, Iran

Tel: +98 914 411 0966
Fax: +98 21 8864 4497
E-mail: rmaghsudy@yahoo.com

Received May 2012
Accepted October 2012

Purpose: To review our 5-year experience in percutaneous nephrolithotomy (PCNL) for horseshoe kidney with large stone burden or failed shockwave lithotripsy (SWL).

Materials and Methods: During 5 years (2006 to 2011), PCNL was performed on 21 patients with horseshoe kidney stone. We evaluated patients (age, gender), stones characteristics (size, number, side, and site), surgical technique, and outcomes.

Results: Sixteen (76.16%) subjects were man and 5 (23.80%) were women, with the mean age of 35 ± 12 years. Mean stone size was 37.2 ± 16.6 mm. Percutaneous nephrolithotomy was performed because of the stone size (over 20 mm) in 18 (85.68%) and failed SWL in 3 (14.28%). Stone numbers were more than one in 18 (85.68%) subjects, and were in the pelvis and at least one calyx. The most common access site was superior posterior calyx (66.64%). Stone-free rate with single session and rigid nephroscope was 71.40%. No major complication occurred during the surgery or in post surgical period. Postoperative minor complications occurred in 3 (14.28%) patients, including transfusion in one (4.76%), fever in one (4.76%), and ileus in one (4.76%) subject.

Conclusion: Percutaneous nephrolithotomy has acceptable results in horseshoe kidney stone and is feasible with rigid nephroscope. Safety and efficacy of PCNL was resembled to normal anatomy kidney in our study.

Keywords: kidney calculi, percutaneous nephrolithotomy, treatment outcome

INTRODUCTION

One of the most common renal fusion anomalies is horseshoe kidney that was first described by Berengario da Carpi in 1522,⁽¹⁾ with the prevalence of 0.25% in general population. Fusion of lower poles during embryogenesis prevents normal kidney ascent and consequently leads to anterior malrotation of the collecting system.⁽²⁾ Anatomical position of the pelvis and calyces and high insertion of the ureter in comparison with normal kidney cause more prevalence of complications in horseshoe kidney. The incidence of nephrolithiasis has been reported to be approximately 20%.⁽²⁾ Percutaneous nephrolithotomy (PCNL) is one of the recommended modalities for horseshoe kidney stone disease treatment. Fletcher and Kettlewell reported the first PCNL for horseshoe kidney stone in 1973.⁽³⁾ Percutaneous nephrolithotomy has been advised for stones larger than 20 mm or failed shockwave lithotripsy (SWL). It has been reported that performing PCNL in horseshoe kidney is not more difficult than normal kidneys; success and complications rates were both in the acceptable range.^(4,5)

Our center is a referral endourological center in Iran and approximately 130 PCNLs are being performed monthly since several years ago. Our center is a referral center for stone management as well; therefore, many complicated cases refer to us. Horseshoe kidney stone is one of the challenging

issues in endourology and multiple treatment modalities exist for its management. In this case series, we reviewed our 5-year experience in PCNL of horseshoe kidney in our center.

MATERIALS AND METHODS

Twenty-one patients with horseshoe kidney stone, who have undergone PCNL from April 2006 until April 2011 in our center, were enrolled in this case series study. Digital recording system was the source of patients' information in our center. Patients were visited in outpatient clinic and became candidate for PCNL if their stone size was greater than 20 mm or had history of failed SWL with smaller stone size.

The recorded variables were patients' age, gender, stone-related factors (side, size on kidney, ureter, and bladder x-ray or computed tomography, stone number and location, access site, and tract number), serum hemoglobin and creatinine level before and after procedure, duration of hospital stay, and complications during and after the operation. Preoperative intravenous urography had been obtained from all the patients (Figure 1), but computed tomography scan had been performed in 10 patients without any retrorenal colon (Figure 2). Percutaneous nephrolithotomy was performed in prone position with a subcostal access to the collecting system. In all the patients, only one tract was created. Access site was based on stone burden, stone location, and collecting system configuration. A 27F rigid nephroscope was

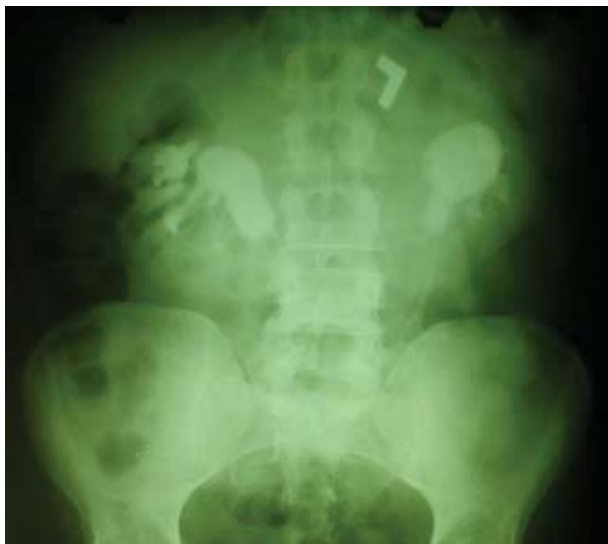

Figure 1. Intravenous urography in a horseshoe kidney with left renal stone.

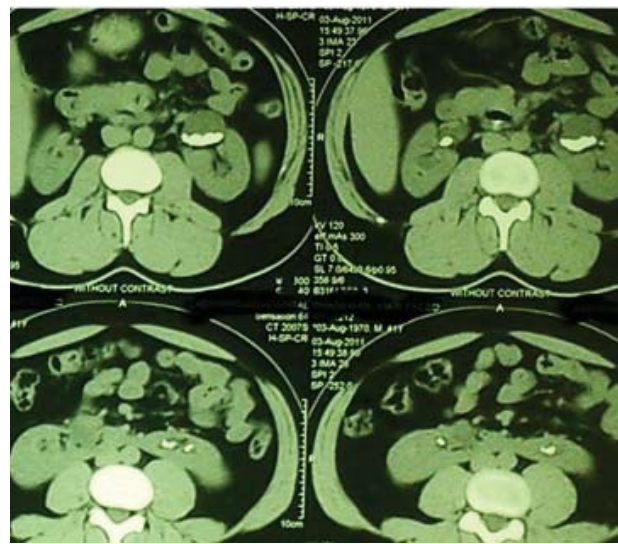


Figure 2. Computed tomography scan of horseshoe kidney with nephrolithiasis.

Table 1. Characteristics of patients with stone in horseshoe kidney.

Mean age (range), y	35 (15 to 63)
Mean stone size (range), mm	37.2 (15 to 90)
Location, n (%)	
Right side	52.36 (11)
Left side	47.60 (10)
Gender, n (%)	
Male	76.16 (16)
Female	23.80 (5)
Stone number, n (%)	
1	14.28 (3)
>1 (multiple or staghorn)	85.68 (18)
Indication of PCNL, n (%)	
Stone size	85.68 (18)
Failure of SWL	14.28 (3)

PCNL indicates percutaneous nephrolithotomy; and SWL, shockwave lithotripsy.

used, and lithotripsy was performed by pneumatic lithotripter alone or in combination with ultrasonic Swiss lithoclast master lithotripter. Large stone fragments (up to 10 mm) were extracted with grasping forceps. At the end of the procedure, nephrostomy tube, double-J (DJ) stent, or both were used if needed; and fluoroscopy was performed for all the patients. Fluoroscopy was not used for stone-free rate (SFR) evaluation because of low density of stones in some patients and low resolution of images, especially in the presence of extravasated contrast media. Stone-free rate was evaluated by kidney, ureter, and bladder x-ray or ultrasonography (in cases with non-opaque stones) 48 hours postoperatively. Routinely, patients were discharged on the 2nd postoperative day if they had clear urine, returned bowel habit, and no fever or urine leakage.

For each patient, the file was reviewed meticulously and recorded complications, such as blood transfusion, visceral injury during or after surgery, fever, urinary leakage, etc, were noticed. Follow-up visits were done at 2 weeks, 2 months, and 4 months postoperatively. Patients were evaluated with serum creatinine level and ultrasonography in each visit. Data were analyzed using SPSS software (the Statistical Package for the Social Sciences, Version 19.0, SPSS Inc, Chicago, Ill-

Table 2. Percutaneous nephrolithotomy results in horseshoe kidney.

Stone site, n (%)	
Lower calyx	14.28 (3)
Pelvis	19.04 (4)
Mixed	61.88 (13)
Lower calyx diverticulum	4.76 (1)
Access site, n (%)	
Superior calyx	66.64 (14)
Middle calyx	9.52 (2)
Lower calyx	19.04 (4)
Calyceal diverticulum	4.76 (1)
Double-J insertion, n (%)	4.76 (1)
Nephrostomy, n (%)	14.28 (3)
Complications, n (%)	
Urine leak	0 (0)
Fever	4.76 (1)
Transfusion	4.76 (1)
Stone-free rate, n (%)	71.40 (15)

inois, USA).

RESULTS

Stone >20 mm was seen in 18 (85.68%) patients and failed SWL in 3 (14.28%) patients. Dull persistent flank pain with fluctuation in severity was the chief complaint in all the subjects. Microscopic hematuria was detected in urinalysis of 17 (80.92%) patients. Three (14.28%) patients had a history of previous open stone surgery on the same kidney. Table 1 shows characteristics of the patients.

Mean stone size was 37.2 ± 16.67 mm in the largest dimension. Eighteen (85.68%) patients had more than one stone, of which 10 (47.60%) were staghorn stone with involvement of the pelvis and at least 2 calyces simultaneously and 13 (61.88%) had stone in the pelvis and one calyx simultaneously. In 7 (33.33%) subjects, stone was either in the calyx or in the pelvis alone.

Access site was subcostal in all the patients. In 14 (66.64%) subjects, access site was posterior superior calyx. Posterior middle and inferior calyx were the entrance site in 2 and 4 patients, respectively. In a patient with diverticulum-in stone, direct puncture of the diverticulum has been done. After

Table 3. Published comparative data on percutaneous management of calculi in horseshoe kidney.

First author	Number of patients	Complications (minor/major), %	Initial stone-free rate, %
Al-Otaibi ⁽⁴⁾	12	42 (42/0)	75
Jones ⁽⁶⁾	15	26 (20/6)	72.3
Lampel ⁽⁸⁾	4	25 (25/0)	75
El Ghoneimy ⁽¹¹⁾	17	19 (14/5)	87.5
Darabi Mahboub ⁽¹²⁾	9	11 (11/0)	66.7
Viola ⁽¹³⁾	44	20 (20/0)	75
Aghamir ⁽¹⁴⁾	30	7 (7/0)	83.3
Present series	21	14 (14/0)	71.4

stone extraction, the diverticular ostium has been dilated and a nephrostomy tube was inserted through the dilated ostium into the pelvis. In other two patients, a nephrostomy tube was used. Double-J stent was used in only one (4.76%) subject with previous open surgery and ureteropelvic junction severe edema. Percutaneous nephrolithotomy was tubeless in 17 (80.92%) patients.

In order to lower the costs, access was achieved only by an endourologist in the operating room with fluoroscopic guide in all the subjects. Furthermore, no patient was scheduled for second look operation; hence, a nephrostomy tube was used only for homeostasis or good drainage of pyelocalyceal system.

There was neither operation cessation (due to severe intraoperative bleeding) nor urinary leakage in our subjects. Transfusion was required in one (4.76%) patient. Mean hemoglobin level was 14.14 ± 1.72 g/dL and 12.84 ± 1.83 g/dL before and after the operation, respectively. Drop in postoperative hemoglobin level was statistically significant ($P < .001$). Mean serum creatinine level was 1.07 ± 0.25 mg/dL before the operation and 1.21 ± 0.26 mg/dL after the operation. Creatinine increase was also significant ($P < .007$).

No acute tubular necrosis occurred. Only one (4.76%) patient with a history of previous surgery on the same kidney and positive urine culture before the operation developed fever postoperatively, which was controlled by antibiotics. Mean hospital stay was 3.4 ± 0.7 days. Longer hospitalization in horseshoe kidney PCNL was due to delay in resolution of gross hematuria. No major intestinal complications occurred.

Ileus was detected only in one (4.76%) patient postoperatively, which was treated with conservative management. Because of subcostal access, no pulmonary complication occurred (Table 2).

Stone-free rate, stone residual fragments less than 4 mm, was 71.40%, which seems to be acceptable due to multiple stone numbers in 18 (85.68%) patients. Since our center is pioneer in stone management with lower cost and acceptable efficacy, flexible nephroscopy and laser lithotripter are not used commonly. Therefore, flexible nephroscope was not used in this study as well.

DISCUSSION

Stone management in horseshoe kidney is a challenge in endourology. Altered pyelocalyceal system anatomy and high ureteropelvic junction position lead to relatively poor results of SWL and retrograde intrarenal surgery. Percutaneous nephrolithotomy is the routine treatment of large renal stones in a kidney with normal anatomy. It has also been reported as a treatment modality for horseshoe kidney stone as well.⁽⁶⁻¹⁰⁾ In our study, acceptable results were achieved with respect to patients' number. With one session operation using one tract and without usage of flexible nephroscope, 71.40% SFR seems to be ideal and comparable with other studies (Table 3). Comparing our study with others, significance of our findings is better revealed. In El Ghoneimy and colleagues' study on 21 renal units, 52% had one pelvic stone and only 14% had staghorn calculi.⁽¹¹⁾ Lower stone burden in their study explains higher SFR (85.70%). Stone-free rate in Darabi Mahboub and associates' study on 9 patients with horseshoe kidney stone is lower than our study (66.70% versus 71.40%).⁽¹²⁾ Viola and colleagues reported 75% SFR.⁽¹³⁾ Aghamir and associates reported 83.3% SFR; however, mean stone size in their study was less than ours (25.4 mm versus 37.2 mm).⁽¹⁴⁾

No major complication occurred in our study; hence, no additional intervention or prolonged hospitalization was required. Minor complications in our patients included postoperative transfusion, fever that was controlled by antibiotics, and ileus, which was managed with conservative treatment. Colon perforation and pelvis rupture did not occur in our patients, while they have been reported by others.^(11,15) Major

complications reported by Raj and coworkers were 12.5%.⁽²⁾ In our study, computed tomography scan was only performed for patients with a history of previous surgery. We believe that it is not necessary to perform computed tomography routinely in all the patients with horseshoe kidney who are planned for PCNL unless they have a history of previous open renal stone surgery. We had 6 patients with stone residual fragments; in 3, stones were in the isthmus and were managed conservatively. Three other patients became stone-free with SWL in 4 months after PCNL.

In our study, mean stone size was larger than other studies. Our results confirm the safety and effectiveness of PCNL in horseshoe kidney stone with rigid nephroscope alone. It is not necessary to refer these subjects to a referral center anymore. Any endourology center with experienced surgeon can manage stone in this group of patients.

CONCLUSION

Percutaneous nephrolithotomy is a safe and effective treatment modality in horseshoe kidney stones with acceptable results. In skilled hands, PCNL complications in horseshoe kidney are similar to normal anatomy kidney. However, further studies with larger sample size are required to confirm this.

CONFLICT OF INTEREST

None declared.

REFERENCES

1. Benjamin JA, Schullian DM. Observations on fused kidneys with horseshoe configuration: the contribution of Leonardo Botallo (1564). *J Hist Med Allied Sci.* 1950;5:315-26.
2. Raj GV, Auge BK, Weizer AZ, et al. Percutaneous management of calculi within horseshoe kidneys. *J Urol.* 2003;170:48-51.
3. Fletcher EW, Kettlewell MG. Antegrade pyelography in a horseshoe kidney. *Am J Roentgenol Radium Ther Nucl Med.* 1973;119:720-2.
4. Al-Otaibi K, Hosking DH. Percutaneous stone removal in horseshoe kidneys. *J Urol.* 1999;162:674-7.
5. Janetschek G, Kunzel KH. Percutaneous nephrolithotomy in horseshoe kidneys. Applied anatomy and clinical experience. *Br J Urol.* 1988;62:117-22.

6. Jones DJ, Wickham JE, Kellett MJ. Percutaneous nephrolithotomy for calculi in horseshoe kidneys. *J Urol.* 1991;145:481-3.
7. Salas M, Gelet A, Martin X, Sanseverino R, Viguier JL, Dubernard JM. Horseshoe kidney: the impact of percutaneous surgery. *Eur Urol.* 1992;21:134-7.
8. Lampel A, Hohenfellner M, Schultz-Lampel D, Lazica M, Bohnen K, Thurof JW. Urolithiasis in horseshoe kidneys: therapeutic management. *Urology.* 1996;47:182-6.
9. Stening SG, Bourne S. Supracostal percutaneous nephrolithotomy for upper pole caliceal calculi. *J Endourol.* 1998;12:359-62.
10. Skolarikos A, Binbay M, Bisas A, et al. Percutaneous nephrolithotomy in horseshoe kidneys: factors affecting stone-free rate. *J Urol.* 2011;186:1894-8.
11. El Ghoneimy MN, Kodera AS, Emran AM, Orban TZ, Shaban AM, El Gammal MM. Percutaneous nephrolithotomy in horseshoe kidneys: is rigid nephroscopy sufficient tool for complete clearance? A case series study. *BMC Urol.* 2009;9:17.
12. Darabi Mahboub MR, Zolfaghari M, Ahanian A. Percutaneous nephrolithotomy of kidney calculi in horseshoe kidney. *Urol J.* 2007;4:147-50.
13. Viola D, Anagnostou T, Thompson TJ, Smith G, Moussa SA, Tolley DA. Sixteen years of experience with stone management in horseshoe kidneys. *Urol Int.* 2007;78:214-8.
14. Aghamir SM, Mohammadi A, Mosavibahar SH, Meysamie AP. Totally tubeless percutaneous nephrolithotomy in renal anomalies. *J Endourol.* 2008;22:2131-4.
15. Shokeir AA, El-Nahas AR, Shoma AM, et al. Percutaneous nephrolithotomy in treatment of large stones within horseshoe kidneys. *Urology.* 2004;64:426-9.