

Antenatal Diagnosis of Renal Duplication by Ultrasonography: Report on Four Cases at a Referral Center

Edward Enéas D. Queiroga Júnior,¹ Marília G. Martins,¹ Livia T. Rios,¹ Edward Araujo Júnior,² Ricardo V. Oliveira,¹ Luciano M. Nardozza,² Antonio F. Moron,²

¹Gynecology and Obstetrics Service,
Federal University of Maranhão
(UFMA), São Luiz, MA, Brazil.

²Department of Obstetrics, Federal
University of São Paulo (UNIFESP),
São Paulo, SP, Brazil.

Corresponding author:

Edward Araujo Júnior, PhD
Department of Obstetrics, Federal
University of São Paulo (UNIFESP),
Rua Carlos Weber, 956 apto. 113
Visage, Alto da Lapa, São Paulo-SP,
CEP 05303-000, Brazil.

Telephone / Fax: +55 11 3796 5944

E-mail: araujojred@terra.com.br

Received January 2013
Accepted June 2013

ABSTRACT

Duplication of the renal collecting system is the commonest major congenital malformation of the urinary tract, with an incidence of 1% among live births. Antenatal diagnosing of renal duplication and an associated ureterocele is infrequent. We report four cases of prenatally diagnosed unilateral duplication of the renal collecting system. In two of them, the renal duplication was associated with an ectopic ureterocele.

Keywords: fetal diseases; hydronephrosis; ultrasonography; ureteral obstruction; kidney; abnormalities.

INTRODUCTION

The urinary tract is the system that is third most commonly affected by congenital malformations, preceded by the central nervous system and the cardiovascular system. Congenital abnormalities of the urinary tract are found relatively frequently, in around 0.5% of all pregnancies.⁽¹⁾ The detection rate for urinary tract abnormalities in routine prenatal ultrasonography examinations is around 20 to 30% of the total number of malformations.⁽²⁾

Duplication of the upper urinary tract is the most common congenital malformation of the urinary tract.⁽³⁾ It is one of the commonest congenital obstructive urological diseases, occurring in around 1% of live births.⁽⁴⁾ Females are more affected than males, and this condition occurs unilaterally in 83% to 90% of the cases.⁽⁵⁾ The upper renal segment is involved in 85% of the cases and ureteroceles occur between 24 and 47% of the cases.⁽⁵⁾ Ureteroceles have been reported in up to 50% of renal duplications, with hydronephrosis of the upper pole.⁽⁶⁾ The diagnosis of pyeloureteral duplication can be made prenatally by means of ultrasonog-

raphy. The findings that lead to suspicion of pyeloureteral duplication are identification of two separate renal poles, dilatation or cystic areas in an upper or lower pole, a dilated ureter and an anechoic cystic structure projecting into the bladder that is suggestive of ureterocele.⁽⁷⁾

Because renal duplication occurs relatively frequently, is the largest malformation of the urinary tract identified prenatally and requires surgical treatment, the present case reports had the aim of describing the antenatal ultrasonographic findings that may lead to suspicion and early diagnosing of this condition, thereby easing the possible postnatal complications.

MATERIALS AND METHODS

This was a descriptive analysis on cases of fetal renal duplication diagnosed and followed up at the Obstetrics and Gynecology Service of the University Hospital, Federal University of Maranhão (UFMA) between January 2007 and May 2012. The cases were described and analyzed based on data gathered from the patients' medical files and ultrasonography reports and on evaluations on images stored in the database. This study only included fetuses with an antenatal diagnosis of renal duplication that was confirmed postnatally.

This study was approved by the Research Ethics Committee of UFMA. The identities of and data on all the patients involved in this study were kept confidential, thus ensuring these individuals' privacy. All the patients gave their signed consent for their cases to be published.

RESULTS

After surveying the data from obstetric examinations carried out over a six-year period (January 2007 to May 2012), our sample consisted of five cases with diagnostic suspicion of renal duplication, with antenatal and postnatal ultrasonographic examinations. One of the cases was excluded because there was no postnatal confirmation. All of the pregnant women were young, with ages ranging from 22 to 37 years, of whom four were primigravidae. All the pregnancies went to full term, with vaginal delivery, and all the

newborns were female with good vitality: Apgar indexes of 8 or 9 at the first and fifth minutes (Table 1).

In all of the cases with postnatal confirmation (Table 2), ultrasonography identified two separate renal poles with dilatation or cystic areas in an upper or lower pole and a dilated ureter. In only two cases was an anechoic cystic structure observed projecting into the bladder, and these were suggestive of an ureterocele. In only one patient (case 4) were other associated malformations encountered: type 1 pulmonary cystic adenomatoid malformation in the left hemithorax, a single umbilical artery and absence of the right kidney.

Case 1

The patient was a 27-year-old primigravida with a gestational age of 38 weeks and 4 days, who was referred to our service for ultrasonography to be performed because of unilateral hydronephrosis shown in a previous ultrasonographic examination. She did not have any relevant family history or personal antecedents. A new ultrasonographic examination was requested: in longitudinal renal slices, this showed a homogenous cystic structure at the upper pole that simulated a renal cyst. In additional coronal and transverse slices, this revealed that the kidney had a duplicated collecting system, with hydronephrosis of the upper unit associated with ureteral dilatation. A ureterocele was observed in the bladder, which suggested a diagnosis of complete renal duplication (Figure 1). The kidney affected was the right kidney and the fetus was female. No malformation was found in any other system. The diagnosis of duplication of the collecting system was confirmed after birth, by means of ultrasonography on the newborn's urinary tract.

Case 2

The patient was a 28-year-old primigravida, with a gestational age of 37 weeks and 1 day, who was referred to our service for ultrasonography to be performed in the third trimester because of unilateral hydronephrosis that had been shown in previous ultrasonography. She did not have any relevant family history or personal antecedents. A new ul-

Table 1. Distribution of maternal age, parity, fetal sex, gestational age at delivery and Apgar indices (1st and 5th minutes) of the cases with an antenatal diagnosis of renal duplication and postnatal confirmation.

Patient	Maternal age	Parity	Fetal sex	Gestational age at delivery	Apgar 1 st / 5 th
1	27	G1P0	Female	38w1d	9/9
2	28	G1P0	Female	39w4d	9/9
3	25	G1P0	Female	37w5d	8/9
4	37	G2P1	Female	37w3d	8/9

Keys: W, week; d, day.

Table 2. Ultrasonographic findings identified among the cases of antenatal diagnosis of renal duplication with postnatal confirmation.

Case	Gestational age at diagnosis	Fetal sex	Kidney with duplication	Two separate renal poles	Dilatation or cystic areas at upper or lower pole	Dilated ureter on the affected side	Ureterocele
1	38w4d	Female	Right	Yes	Yes	Yes	Yes
2	37w1d	Female	Right	Yes	Yes	Yes	Yes
3	31w3d	Female	Right	Yes	Yes	Yes	No
4	28w0d	Female	Left	Yes	Yes	Yes	No

Keys: W, week; d, day.

trasonographic examination was requested: in the region of the right kidney, this showed two collecting systems and two ureters, with dilatation of the upper unit and an ureterocele compatible with complete renal duplication. No malformation was found in any other system. The diagnosis of duplication of the collecting system was confirmed after birth, by means of ultrasonography on the newborn's urinary tract.

Case 3

The patient was a 25-year-old primigravida, with a gestational age of 31 weeks and 3 days, who was referred to our service for ultrasonography because of unilateral hydronephrosis that had been shown in previous ultrasonography. She did not have any relevant family history or personal antecedents. She did not have any relevant family history or personal antecedents. A new ultrasonographic examination was requested: this showed that the fetal right kidney presented signs of duplication of the collecting system, with moderate pyeloureteral dilatation of the upper unit, but without signs of ectasia or dilatation of the lower unit. There were no images suggestive of an ureterocele in the fetal bladder (Figure 2). No malformation was found in any other system. The diagnosis of duplication of the collecting

system was confirmed after birth, by means of ultrasonography on the newborn's urinary tract.

Case 4

The patient was a 37-year-old woman in her second pregnancy, with a gestational age of 28 weeks, who was referred to our service for ultrasonography because of abnormalities that had been shown in previous ultrasonography. She did not have any relevant family history or personal antecedents. A new ultrasonographic examination was requested, which showed a normal (non-ectopic) pregnancy of 28 weeks, with the following: amniotic fluid volume slightly above normal; type 1 pulmonary cystic adenomatoid malformation occupying the middle and lower thirds of the left lung; left renal duplication, with pyelectasis of the upper and lower units; renal pelvis measuring 0.6 cm in the upper unit and 0.7 cm in the lower unit; absence of image of the right kidney; displacement of the cervical spine (hemivertebra); and a single umbilical artery. An additional ultrasonography examination was performed in the 33rd week, which confirmed the findings described previously. The diagnosis of duplication of the collecting system was confirmed after birth, by means of ultrasonography on the newborn's urinary tract.

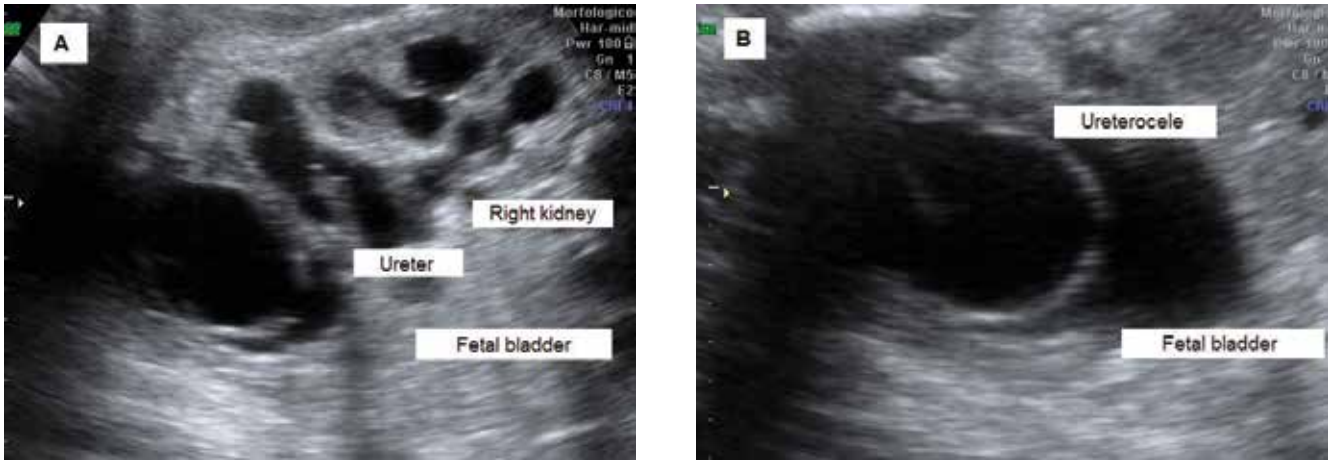


Figure 1. (A) Hydronephrosis in the upper unit of the right kidney, with dilated and tortuous ureter. (B) Fetal bladder showing ureterocele.

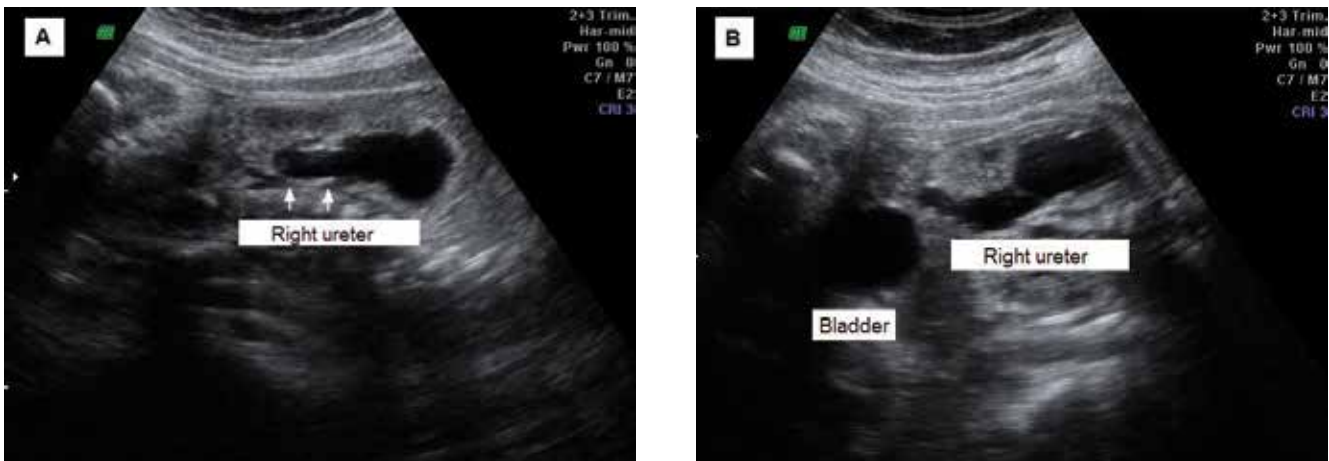


Figure 2. (A) Moderate pyeloureteral dilatation of the upper unit of the right kidney, without signs of ectasia or dilatation of the lower unit. (B) Bladder not showing ureterocele.

DISCUSSION

Duplication of the renal collecting system is the commonest major congenital malformation of the urinary tract, and females are affected more than males.^(4,6,8) This was also observed in the present series, in which all the cases were in females. This condition has been found to be unilateral in 83 to 90% of the cases,^(4,6,8) and this was seen in 100% of the cases in the present series. In the present series, an ureterocele was present in half of the cases. This narrowing gave rise to significant dilatation of the upper renal unit and the ureter that drained it, in 85% of the cases.⁽⁹⁾ In the cases reported here, there was dilatation of the upper unit and dilatation of the corresponding ureter.

The ureter that drains the upper unit commonly presents relative obstruction, thus leading to dysplasia of the upper renal pole. On the other hand, the ureter that drains the lower unit is inserted topically in the vesical trigone, and may present ureteral-vesical reflux.⁽⁸⁾ Dilatation of the upper unit of the collecting system may simulate a large renal cyst at the upper pole.⁽⁴⁾ In the cases reported here, there was moderate hydronephrosis of the upper units and there was no report of cysts at the upper renal pole.

To increase the renal duplication detection rate on antenatal ultrasonography, a systematized search for the following ultrasonographic findings is recommended: 1) length of the kidney in the sagittal plane (including the upper pole); 2)

cysts imaged at the upper pole surrounded by renal parenchyma; 3) kidney with two renal pelvises that are not in communication; 4) dilated ureter, which usually drains the upper pole; and 5) cysts imaged in the bladder (ureterocele).⁽⁶⁾ In all four cases described here, the findings comprised cysts imaged at the upper pole, two renal pelvises that were not in communication and a dilated ureter. An ureterocele was present in two cases.

The case numbers of fetal renal duplication was small. Despite our service to be a public referral hospital in the Maranhão state in the northeast of Brazil, the prenatal care is deficient and several pregnant women are referenced in advanced gestational age, damaging the prenatal diagnosis. Due of low quality of prenatal care in the public services in Brazil, our service has a protocol of investigation of several congenital infections in all pregnant women, mainly toxoplasmosis and syphilis. These infections have high incidence in the northeast of Brazil.

In summary, based on our series of four cases of fetal renal duplication, the condition was correctly identified in all cases, by using the ultrasonographic descriptions of Whitten and colleagues.⁽⁴⁾ With regard to antenatal classification of the likelihood that cases would really present renal duplication, the cases of the present study fitted into the category of high probability. Lastly, the importance of making an accurate antenatal diagnosis that allowed early introduction of prophylactic measures in order to diminish the potential risks of complications like infection, or of evolution to renal dysplasia with loss of renal function during the postnatal period, was highlighted.

CONCLUSION

The prenatal diagnosis of renal duplication is very important to counseling of parent and follow of these cases in reference services with multidisciplinary team. These actions can contribute to reduce the risk of complications in the postnatal period.

CONFLICT OF INTEREST

None declared.

REFERENCES

1. Elder JS. Antenatal hydronephrosis. Fetal and neonatal management. *Pediatr Clin North Am.* 1997;44:1299-321.
2. Pope JC 4th, Brock JW 3rd, Adams MC, Stephens FD, Ichikawa I. How they begin and how they end: classic and new theories for the development and deterioration of congenital anomalies of the kidney and urinary tract, CAKUT. *J Am Soc Nephrol.* 1999;10:2018-28.
3. Smith P, Dunn M. Duplication of the upper urinary tract. *Ann R Coll Surg Engl.* 1979;61:281-86.
4. Whitten SM, McHoney M, Wilcox DT, New S, Chitty LS. Accuracy of antenatal fetal ultrasound in the diagnosis of duplex kidneys. *Ultrasound Obstet Gynecol.* 2003;21:342-46.
5. Vergani P, Ceruti P, Locatelli A, et al. Accuracy of prenatal ultrasonographic diagnosis of duplex renal system. *J Ultrasound Med.* 1999;18:463-7.
6. Abuhamad AZ, Horton CE Jr, Horton SH, Evans AT. Renal duplication anomalies in the fetus: clues for prenatal diagnosis. *Ultrasound Obstet Gynecol.* 1996;7:174-7.
7. Adiego MB, Martinez P, Perez J, Illescas T, Barron E. Prenatal diagnosis of renal duplex systems. Ultrasonographic features and postnatal outcomes. *Ultrasound Obstet Gynecol.* 2010;36(Suppl 1):149.
8. Mackie GG, Stephens FD. Duplex kidneys: a correlation of renal dysplasia with position of the ureteral orifice. *J Urol.* 1975;114:274-80.
9. Mascarello VJ, Smith EH, Carrera GF, Berger M, Teele RL. Ultrasonic evaluation of the obstructed duplex kidney. *AJR Am J Roentgenol.* 1977;129:113-20.