

# Laparoscopic Management of Symptomatic Giant Adrenal Pseudocyst: A Case Report

Mohammad AsalZare,<sup>1</sup> Behnam Shakiba,<sup>2</sup> Amir Abbas Asadpour,<sup>1</sup> Alireza Ghoreifi<sup>2</sup>

<sup>1</sup> Department of Urology,  
Ghaem Hospital, Mashhad  
University of Medical Sciences,  
Mashhad, Iran.

<sup>2</sup> Department of Urology,  
Imam Reza Hospital, Mashhad  
University of Medical Sciences,  
Mashhad, Iran.

Corresponding Author:

Behnam Shakiba, MD  
Department of Urology, Imam Reza  
Hospital, Razi St., Mashhad, Iran.

Tel: +98 511 8022553  
E-mail: B\_shakiba@razi.tums.ac.ir

Received January 2013  
Accepted July 2013

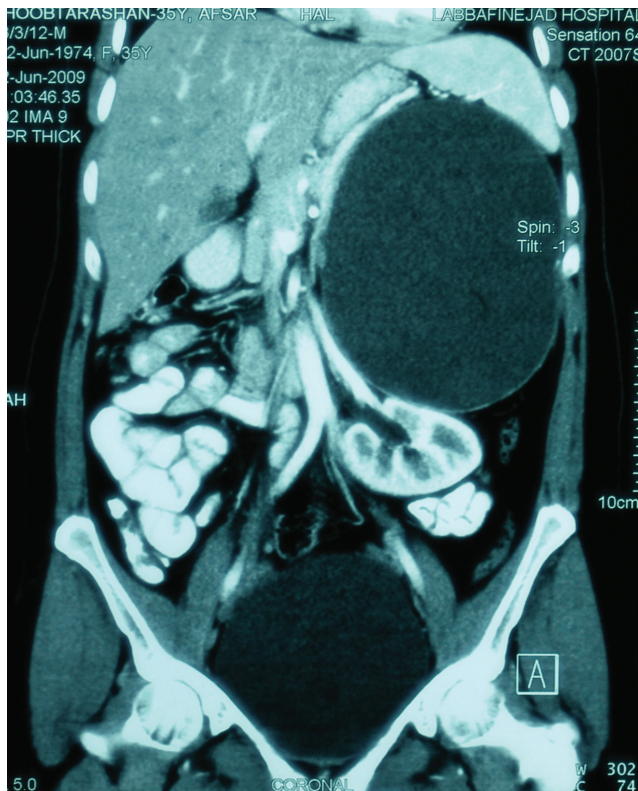
**Keywords:** adrenal gland diseases; cysts; laparoscopy; treatment outcome.

## INTRODUCTION

Cystic lesions of the adrenal gland are rare entities with an estimated incidence of 0.064-0.18% in autopsy series.<sup>(1)</sup> There are four categories of adrenal gland cyst: epithelial, endothelial, parasitic and pseudocyst.<sup>(2)</sup> Adrenal pseudocysts are fibrous surrounded cysts without any endothelial or epithelial lining, and are generally filled with fresh blood or clots due to hemorrhage into the cysts.<sup>(3)</sup> The majority of adrenal pseudocysts are asymptomatic and of limited clinical significance. These asymptomatic simple pseudocysts require no further evaluation. Treatment of adrenal pseudocysts usually indicated in large and complicated cysts.<sup>(4)</sup> We report a symptomatic huge adrenal pseudocyst measuring about 19 cm in largest diameter, which managed with laparoscopic excision.

## CASE REPORT

A 35 year-old woman was referred to our hospital with the chief complaint of pain and feeling of pressure in the left upper quadrant since six months earlier. Personal and Family history had not relevant information. On physical examination, the patient had normal blood pressure and



**Figure 1.** Abdominal computed tomography showed a 19 × 17 × 13 cm suprarenal well-defined cystic mass.

in the abdominal examination there was a palpable mass in the left flank and left upper quadrant without tenderness. The patient was admitted for further investigation. The results of laboratory studies including blood counts, blood chemistry and electrolytes were within normal limits. Abdominal ultrasonography demonstrated a 17 cm unilocular cystic mass occupying the left abdomen. Abdominal computed tomography (CT) scan showed a 19 × 17 × 13 cm suprarenal well-defined cystic mass (Figure 1). This cyst located between the spleen, left kidney, and pancreas and arising from the left adrenal gland. The left kidney was displaced downward to the left lower quadrant of the abdomen by the mass. There was no septation, calcification and contrast enhancement in the mass. Hormonal examination, including 24 hours urine catecholamines, 17-hydroxycorticosteroids, 17-ketosteroids, adrenocorticotrophic hormone, serum catecholamines, cortisol, aldosterone, 24-hour urinary excretion of metanephrines and vanillylmandelic acid and plasma renin activities were all within normal limits.

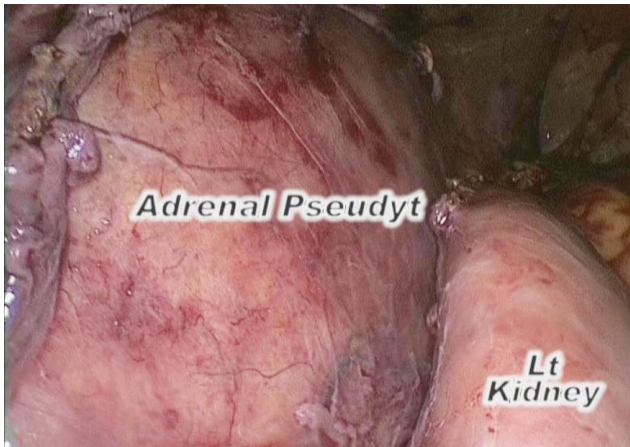
The clinical diagnosis of adrenal cyst was made based on symptoms, radiographic findings and non-functional status of the mass. A laparoscopic transperitoneal cyst excision with preservation of the remaining part of the gland was performed (Figure 2). The cyst was adherent to the underlying kidney and left adrenal gland. There were no adhesions between the cyst and the pancreatic tail and spleen. It was separated from the adjacent organs by monopolar electrocautery scissor without any difficulties. Occasionally, for dissection we used bipolar electrocautery scissor. Intra operatively, after separation of cyst from kidney and spleen, we performed percutaneous aspiration. After aspiration, the cyst was not collapsed; because it contained degenerated old clots. After separation the cyst from adjacent organs, it was removed with an open incision. The operative time was about two hours. The blood loss was minimal and there was no intraoperative complication.

Gross appearance showed a thin-walled, yellowish unilocular adrenal mass contained hemorrhagic fluid and degenerated old clots. Pathological examination revealed an “adrenal pseudocyst” without an epithelial or endothelial lining (Figure 3). There was no evidence of malignancy. Postoperatively, she recovered uneventfully and was discharged on the second postoperative day. The left abdominal pain and discomfort resolved after removal of the pseudocyst. At follow-up 28 months later, the patient was asymptomatic and without pathological findings.

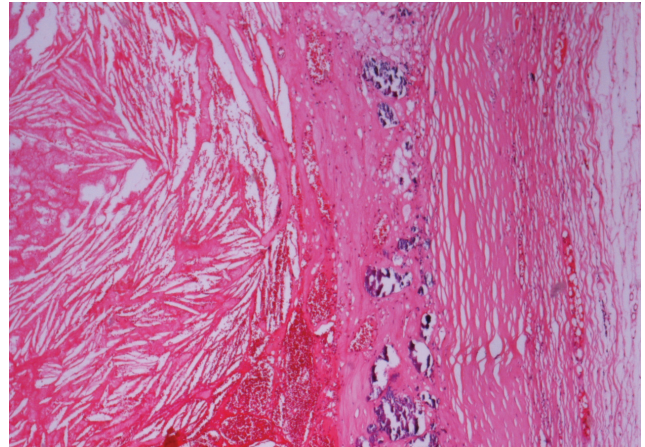
## DISCUSSION

Adrenal cysts originating within the adrenal cortex or medulla, was described first by the Viennese anatomist Greiselius in 1670.<sup>(5)</sup> There are four types of adrenal cysts: endothelial cysts, pseudocysts, epithelial cysts and parasitic cysts. Adrenal pseudocysts represent about 32-80% of adrenal cysts. The cause and mechanism of adrenal pseudocysts remains unknown. Possible etiologies include: degeneration of a primary adrenal neoplasm, degeneration of a vascular neoplasm, and hemorrhage within normal adrenal tissue or into an adrenal tumor.<sup>(4)</sup>

Although Adrenal pseudocysts can occur at any age, studies have showed that they are most commonly diagnosed in the fourth and fifth decades of life. Pseudocyst is more common



**Figure 2.** Laparoscopic transperitoneal cyst excision is shown. The cyst was adherent to the underlying kidney.



**Figure 3.** Pathological examination of surgical specimen revealed an "adrenal pseudocyst" without an epithelial or endothelial lining.

in women than men, with a ratio of approximately 2-3:1.<sup>(6)</sup> Most cases are asymptomatic; however, abdominal or flank pain, a fullness or mass in abdomen or flank are the most common presenting features of persons with symptomatic adrenal pseudocysts.<sup>(7,8)</sup> The differential diagnosis varies based on location, but commonly includes splenic cysts, hepatic cysts, renal cysts, mesenteric or retroperitoneal cysts, urachal cysts and solid adrenal tumors.<sup>(9)</sup>

A variety of radiologic modalities like ultrasonography (US), CT scan and magnetic resonance imaging (MRI) are used for diagnose of adrenal cysts. The US appearances of adrenal cysts are unilocular or multilocular cystic lesions similar to those seen elsewhere in the body.

CT scan is the imaging modality of choice for diagnosis of adrenal cysts. The sensitivity and diagnostic accuracy of preoperative CT for adrenal cyst are 96% and 62.5-96%, respectively.<sup>(6,10)</sup> Usually CT scan of pseudocysts demonstrates well-demarcated round or oval masses with low density. Internal hemorrhage may due to some atypical features in CT scan including, thick walls, internal septations and calcifications. Calcification may be present in the wall or septum.<sup>(2,9,11)</sup>

Histopathological examination of the specimen confirms the diagnosis of adrenal cysts. True adrenal cysts are lined with endothelial or epithelial cells, but adrenal pseudocysts are devoid of a recognizable layer of lining cells and enclosed by a fibrous tissue wall.<sup>(7)</sup>

The management of adrenal pseudocysts depends on some factors such as size, presence of symptoms, functional status and probability of malignancy. If the cysts are small (< 5-6 cm) with near-water density and have a thin (< 3 mm) wall, and are not causing symptoms, careful observation with periodic CT scans is often done. Surgical excision is indicated in the presence of symptoms, suspicious for malignancy, increase in size and detection of a functioning adrenal cyst. Surgical treatment includes open or laparoscopic approach. Some studies recommended that open resection is preferred technique in patients with large sized cysts (> 6 cm) and the laparoscopic approach may be a valuable treatment for cysts smaller than 6 cm.<sup>(4,11,12)</sup> Based on our knowledge, there are a few reports, that showed the feasibility of laparoscopic technique for large (> 6 cm) adrenal cysts and masses.<sup>(13-15)</sup>

## CONCLUSION

In present report, we used laparoscopic resection as an effective minimally invasive approach for a huge symptomatic adrenal pseudocyst measuring about 19 cm in largest diameter.

## CONFLICT OF INTEREST

None declared.

## REFERENCES

1. Rozenblit A, Morehouse HT, Amis ES Jr. Cystic adrenal lesions: CT features. *Radiology*. 1996;201(Suppl 2):541-8.

2. Ujam AB, Peters CJ, Tadrous PJ, Webster JJ, Steer K, Martinez-Isla A. Adrenal pseudocyst: Diagnosis and laparoscopic management - A case report. *Int J Surg Case Rep.* 2011;2:306-8.
3. Demir A, Tanidir Y, Kaya H, Turkeri LN. A giant adrenal pseudocyst: case report and review of the literature. *Int Urol Nephrol.* 2006;38:167-9.
4. Kim BS, Joo SH, Choi SI, Song JY. Laparoscopic resection of an adrenal pseudocyst mimicking a retroperitoneal mucinous cystic neoplasm. *World J Gastroenterol.* 2009;15:2923-6.
5. Doran AH. Cystic Tumour of the Suprarenal Body Successfully Removed by Operation, with Notes on Cases Previously Published. *Br Med J.* 1908;1:1558-63.
6. Salemis NS, Nisotakis K. Giant adrenal pseudocyst: laparoscopic management. *ANZ J Surg.* 2011;81:185-6.
7. Medeiros LJ, Lewandrowski KB, Vickery AL Jr. Adrenal pseudocyst: a clinical and pathologic study of eight cases. *Hum Pathol.* 1989;20:660-5.
8. Fan F, Pietrow P, Wilson LA, Romanas M, Tawfik OW. Adrenal pseudocyst: a unique case with adrenal renal fusion, mimicking a cystic renal mass. *Ann Diagn Pathol.* 2004;8:87-90.
9. Momiyama M, Matsuo K, Yoshida K, et al. A giant adrenal pseudocyst presenting with right hypochondralgia and fever: a case report. *J Med Case Rep.* 2011;5:135.
10. El-Hefnawy AS, El Garba M, Osman Y, Eraky I, El Mekresh M, Ibrahim el-H. Surgical management of adrenal cysts: single-institution experience. *BJU Int.* 2009;104:847-50.
11. Erbil Y, Salmaslioglu A, Barbaros U, et al. Clinical and radiological features of adrenal cysts. *Urol Int.* 2008;80:31-6.
12. Stimac G, Katusic J, Sucic M, Ledinsky M, Kruslin B, Trnski D. A giant hemorrhagic adrenal pseudocyst: case report. *Med Princ Pract.* 2008;17:419-21.
13. Ramacciato G, Mercantini P, La Torre M, et al. Is laparoscopic adrenalectomy safe and effective for adrenal masses larger than 7 cm? *Surg Endosc.* 2008;22:516-21.
14. Novitsky YW, Czerniach DR, Kercher KW, Perugini RA, Kelly JJ, Litwin DE. Feasibility of laparoscopic adrenalectomy for large adrenal masses. *Surg Laparosc Endosc Percutan Tech.* 2003;13:106-10.
15. Kar M, Pucci E, Brody F. Laparoscopic resection of an adrenal pseudocyst. *J Laparoendosc Adv Surg Tech A.* 2006;16:478-81.