

Urothelial Carcinoma of the Ureter in a Patient with Functional Single Kidney

Abbas Basiri, Mahmoudreza Nasiri, Mohammad Hossein Soltani

*Urology and Nephrology
Research Center, Shahid
Labbafinejad Medical
Center, Shahid Beheshti
University of Medical Sci-
ences, Tehran, Iran*

Corresponding Author:

*Abbas Basiri, MD
Urology and Nephrology
Research Center, No. 103,
9th Bostan St, Pasdaran
Ave, 1666677951, Tehran,
Iran*

*Tel: +98 21 2256 7222
Fax: +98 21 2256 7282*

E-mail: basiri@unrc.ir

BRIEF HISTORY

A 56-year-old man with a history of left radical nephrectomy due to clear cell renal carcinoma 5 years earlier presented with a non-specific right flank pain since 3 months ago without any other accompanying symptoms.

Physical examination and routine lab tests were within normal limits except for a serum creatinine level of 1.9 mg/dL. Ultrasonography and abdominopelvic computed tomography revealed right hydroureteronephrosis.

On ureteroscopy, a vegetative lesion was seen in the distal segment of the right ureter, 4 cm above the right ureteral orifice, measuring 3 cm. A selective right side urine sample was obtained for cytology, and cold cup biopsy was taken from the lesion. Cytology reported atypical cell and biopsy revealed low-grade transitional cell carcinoma.

QUIZ

According to the scenario, which procedure is justified for management of the patient?

Patient has undergone laparoscopic distal right ureterectomy and ureteroneocystostomy using Boari flap technique. Duration of the surgery was 390 minutes. Figure 1 illustrates the tumor pathology.

The post-operation period was uneventful and the patient was discharged from the hospital on the 10th postoperative day. Follow-up diethylenetriamine pentaacetic acid (DTPA) scan (Figure 2) revealed acceptable anastomotic continuity without obstruction 2 month post-operatively, and creatinine level was 1.9 mg/dL.

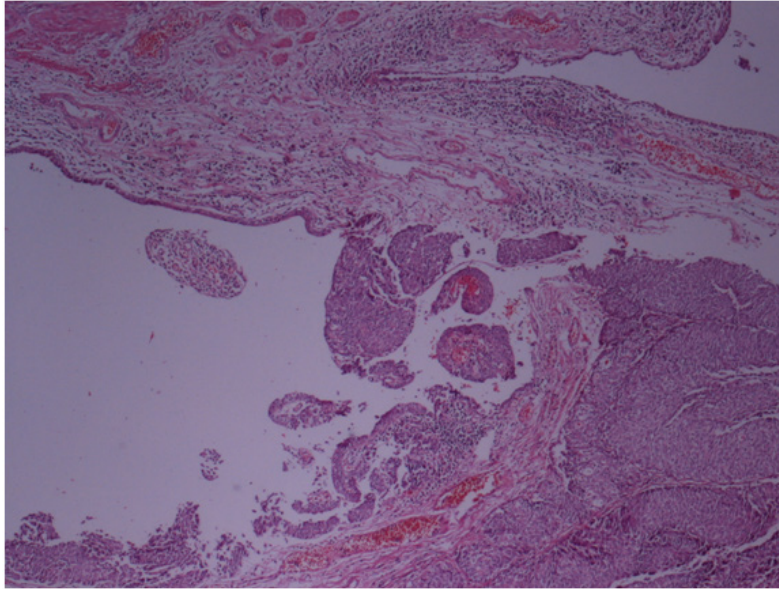


Figure 1. Low-grade papillary urothelial carcinoma of the distal ureter (PT1).

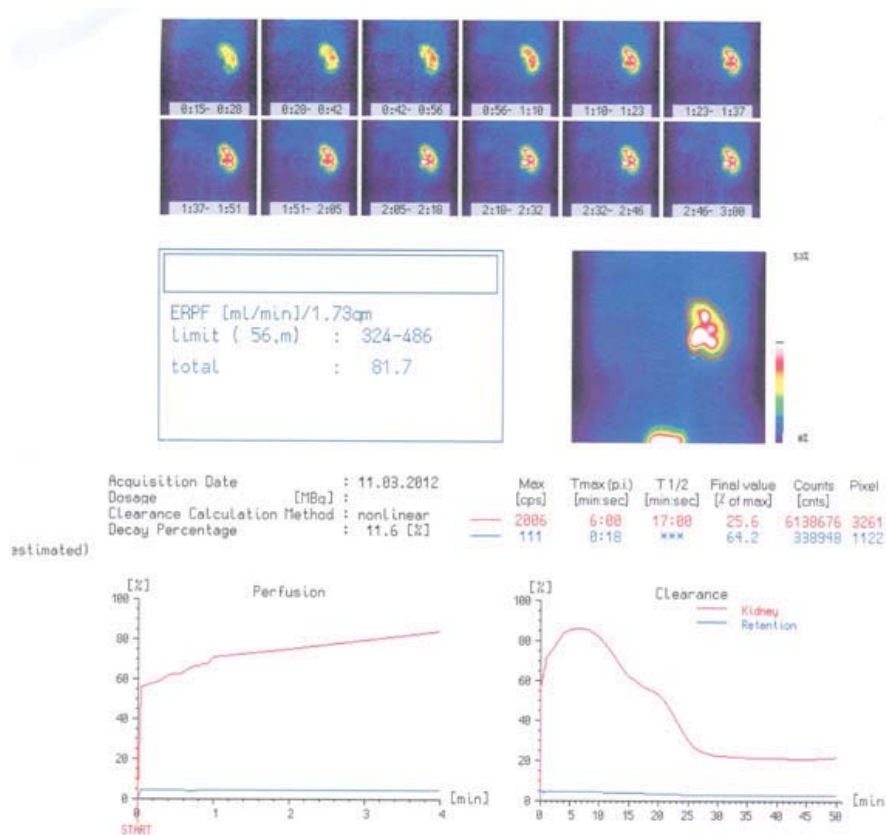


Figure 2. diethylenetriamine pentaacetic acid scan revealed acceptable anastomotic continuity without obstruction 2 month post-operatively.