

Lower Moiety Pelvi Ureteric Junction Obstruction Leading to Acute Renal Failure in an Ectopic Fused Kidney

Priyadarshi Ranjan, Ranjana Singh, Aneesh Srivastava

Keywords: Ureteral Obstruction; etiology; surgery; Kidney abnormalities; acute renal failure

INTRODUCTION

Uretero-Pelvic Junction Obstruction (UPJO) has many etiologies and remains a rare cause of renal failure. We present a rare case of fused kidney causing pelvi-ureteric junction obstruction and acute renal failure.

CASE REPORT

A 37 years old man presented to the emergency department with oliguric renal failure. At presentation his serum creatinine was 12 mg/dl and he was in septicemia. He had passed only 250 ml of urine in the past 24 hours. Abdominal sonography revealed right fused renal mass with hydronephrosis of both the upper and the lower moieties. An abdominal computed tomography (CT) scan revealed grossly destroyed parenchyma of the lower moiety with preserved parenchyma but gross hydronephrosis of the upper moiety (Figure 1). After stabilization bilateral percutaneous nephrostomies were placed in both the moieties. The upper moiety drained around 3 liters per day, while the lower moiety did not show urine produc-

Corresponding Author:

Priyadarshi Ranjan, MD
Consultant Urologist and Chief
Kidney Transplant Surgeon, Fortis
Hospital, Mohali, Punjab, India.

Tel: +91 800 440 0008
Email: priyadarshiranjan@sify.com

Received June 2011
Accepted September 2011

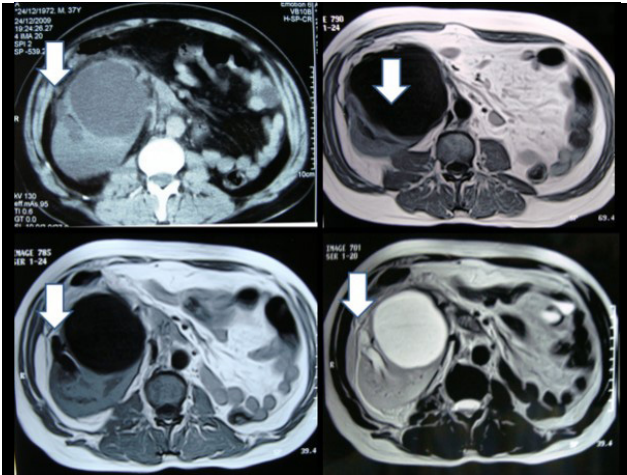


Figure 1. CT Scan and MRI demonstrating the grossly hydronephrotic parenchyma of the lower pole due to PUJ obstruction. The upper polar ureter emerging laterally marked with arrow can be seen getting compressed due to the compression by the lower moiety.

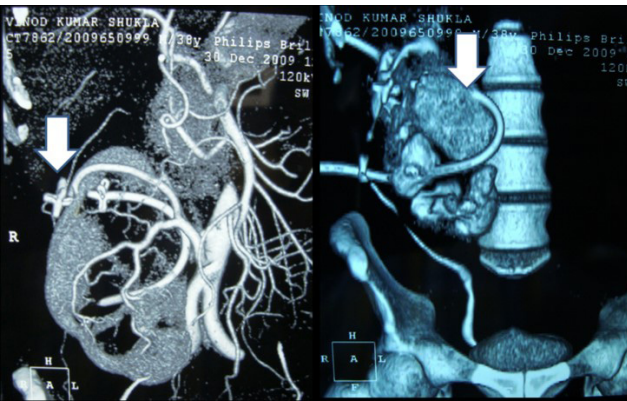


Figure 2. A triphasic CT reconstruction demonstrating both the upper and lower moiety nephrostomies and the normal ureter of the upper moiety marked with an arrow.

tion. Subsequent nephrostograms revealed pelvi ureteric junction (PUJ) obstruction in the lower moiety with normal drainage of the upper moiety. A review CT and Magnetic Resonance Imaging (MRI) revealed the cause of obstruction of the lower moiety at the level of the PUJ which subsequently lead to the concomitant obstruction of the upper moiety (Figure 2). In view of negligible renal function of the lower moiety, lower polar heminephrectomy was done.^(1,2) The upper moiety compression was relieved and did not require any intervention. The patient had uneventful recovery with normal renal function at discharge.

CONFLICT OF INTEREST

None declared.

REFERENCES

1. Ulchaker J, Ross J, Alexander F, Kay R. The spectrum of ureteropelvic junction obstructions occurring in duplicated collecting systems. *J Pediatr Surg.* 1996;3:1221-4.
2. Horst M, Smith GH. Pelvi-ureteric junction obstruction in duplex kidneys. *BJU Int.* 2008;101:1580-4.