

1 SUBMITTED 5 JAN 23  
2 REVISION REQ. 20 FEB 23; REVISION RECD. 14 MAR 23  
3 ACCEPTED 19 APR 23  
4 **ONLINE-FIRST: MAY 2023**  
5 DOI: <https://doi.org/10.18295/squmj.5.2023.036>

## 7 **An Unusual Presentation of Choriocarcinoma in A postmenopausal woman**

### 8 *A case report*

9 **\*Aref Zribi,<sup>1</sup> Reem Al Mazroui,<sup>2</sup> Raza Sayani,<sup>2</sup> Ikram A Burney<sup>1</sup>**

10  
11 <sup>1</sup>Women Health Program and <sup>2</sup>Department of Radiology, Sultan Qaboos Comprehensive Cancer  
12 Care and Research Centre, Muscat, Oman.

13 \*Corresponding Author's e-mail: [arefdoc@gmail.com](mailto:arefdoc@gmail.com)

### 14 15 **Abstract**

16 Choriocarcinoma (CC) is a malignant neoplasm of the trophoblastic tissue, with a potential to  
17 metastasize to distant organs. A limited case of gestational CC develops after a long latent  
18 period. We describe the case of a 52-year-old postmenopausal woman who developed metastatic  
19 choriocarcinoma presumably of gestational origin, 8 years after the last pregnancy, and 2 years  
20 after the last menstrual period. The patient was diagnosed with CC metastatic to the brain,  
21 spleen, lung and the kidney. The  $\beta$ -human chorionic gonadotrophin level was found to be raised  
22 (1,292,867 mIU/mL). The International Federation of Gynecologic Oncology (FIGO) risk score  
23 was calculated to be 14 (very high risk). The patient was initially treated with whole-brain  
24 radiotherapy (WBRT) and splenic artery embolization because of a hemoperitoneum. Afterwards  
25 the patient received systemic treatment using the standard EMA/CO regimen till complete  
26 serological remission.

27 **Keywords:** Choriocarcinoma; Postmenopausal; Latent period; Brain; Oman.

28  
29  
30

## 31 **Introduction**

32 Choriocarcinoma (CC) is a malignant neoplasm of the trophoblastic tissue, with a potential to  
33 metastasize to distant organs.<sup>1</sup> There are two sorts, gestational and non-gestational CC. Majority  
34 of cases of gestational CC are intra-uterine, and only 0.8-4 % develop in ectopic locations.<sup>2,3</sup> The  
35 non-gestational CC arise in the gonads, usually in the reproductive age. A limited cases of  
36 gestational CC develop after a long dormant period.<sup>4,5</sup> Gestational CC has been reported to  
37 develop between 5 weeks and up to 38 years after gestation, and even after menopause.<sup>4</sup>  
38 Approximately 30 % of cases of gestational CC are metastatic at the time of diagnosis.<sup>4</sup> The  
39 tumor metastasizes most commonly to the lungs (60-75%), vagina (40-50%), brain (15-20%),  
40 liver (15-20%), spleen (10%), intestines (5-10%), and the heart (4%).<sup>6-9</sup> Here, we illustrate the  
41 case of metastatic CC in a 52-year-old postmenopausal lady, growing 8 years after the last  
42 pregnancy, and 2 years after the last menstrual period.

## 44 **Case Report**

45 A 52-year-old female, menopausal for two years, was brought to the emergency room with a  
46 history of headache and an episode of seizure. There was no history of loss of consciousness.  
47 Past medical history revealed an episode of vaginal bleeding 8 years back, for which the patient  
48 underwent dilatation and curettage, and was diagnosed to have a molar pregnancy. She had no  
49 other past medical history of significance. On physical examination, the patient was conscious,  
50 oriented to time, place and person, vitally stable, and had normal power and tone in both upper  
51 and lower limbs. There was no facial asymmetry, and all cranial nerves were intact.  
52 Gynecological exam revealed a normal vulva; cervix was irregular and the uterus was bulky.  
53 There was no vaginal bleeding.

54 Magnetic resonance imaging (MRI) showed a large space occupying lesion involving the right  
55 frontal lobe, measuring 36 x 33 mm, with surrounding vasogenic edema and midline shift to the  
56 left, and subfalcine herniation in the frontal area. Several lesions involving the right parietal and  
57 the occipital lobes, largest measuring 20 x 20 mm, were also identified (Figure 1). The CT scan  
58 of the body cavity showed heterogeneous appearance of the endometrial cavity, and multiple  
59 hypodense lesions in the spleen, largest measuring up to 24 mm, and a small lesion in the right

60 kidney. A soft tissue nodule in the right middle lobe of the lung and in the left lung apex were  
61 also seen. MRI of the pelvis showed normal endometrial thickness and signal intensity, no  
62 adnexal masses, and no enlarged pelvic lymph nodes or ascites (figure 2).

63 Other than the splenic lesion, no other lesion was large enough to biopsy. The  $\beta$ -human chorionic  
64 gonadotrophin ( $\beta$ -HCG) level was found to be raised (1,292,867 mIU/mL; normal <5 mIU/mL).  
65 In absence of tissue diagnosis, no mass in the adnexal region, and a very high level of  $\beta$ -HCG, a  
66 diagnosis of gestational CC was made. The International Federation of Gynecologic Oncology  
67 (FIGO) risk score was calculated to be 14 (very high risk).

68 After admission to the hospital, the patient developed fever, and was found to have  
69 staphylococcus aureus bacteremia, the bacteria being sensitive to cefazolin. In addition, the  
70 patient was treated with levetiracetam and dexamethasone. The case was discussed in tumor  
71 board. Because of the midline shift and impending herniation, the patient was initially treated  
72 with whole-brain radiotherapy (WBRT) to a dose of 25Gy in 10 fractions. After radiotherapy,  
73 systemic treatment was commenced using induction chemotherapy, consisting of etoposide and  
74 cisplatin. Four days after receiving the 1<sup>st</sup> dose, the patient developed tachycardia (HR 140/min,  
75 regular, low volume). Electrocardiogram revealed sinus rhythm. The hemoglobin was found to  
76 be very low at 3 g/dl. An urgent CT scan of the abdomen showed hemoperitoneum and a  
77 significant progression in the size of the metastases to the spleen, which had breached the  
78 capsule (Figure 3). Splenic artery embolization was carried out leading to a complete occlusion  
79 of the artery and a rapid arrest of further bleeding (Figure 4). Systemic chemotherapy was  
80 continued, as the standard EMA/CO regimen, till complete serological remission. At the time of  
81 serological remission, CT scan of the body cavity revealed near complete resolution of the  
82 splenic and lung lesions. End-of-treatment CT scan and MRI of the brain confirmed the  
83 radiologic remission. Oral and written consent were taken from the patient for publication  
84 purposes.

85

## 86 **Discussion**

87 We report the successful treatment of a post-menopausal women, diagnosed to have stage IV,  
88 high risk CC, most likely of gestational origin, 8 years after the evacuation of a hydatidiform

89 mole, and managed with WBRT and splenic artery embolization, before being treated with  
90 systemic chemotherapy.

91 The vast majority of cases occur in women less than 35 years of age, usually within one year  
92 following the diagnosis of hydatidiform mole (60% of cases), or abortion (30%) and after a  
93 normal or ectopic pregnancy (10%).<sup>10,11</sup> A higher incidence is reported from Africa, Asia and  
94 South America, with an estimated incidence of 1 in 500-3000 pregnancies in south-east Asia.  
95 The occurrence in postmenopausal period is uncommon.<sup>12</sup> Furthermore, only a countable cases  
96 have been described after a long latent time from the last pregnancy.

97 The risk of hydatidiform mole raise significantly with increasing mother age.<sup>13</sup> CC can develop  
98 anytime between 5 weeks to several decades after antecedent pregnancy or even after  
99 menopause.<sup>14,15</sup> Desai published a case of CC in a 73-year-old patient, developing 38 years after  
100 pregnancy and 23 years after her last menstrual menses.<sup>5</sup> O'Neill reported the case of CC in a 57-  
101 year old lady, 22 years after the last known pregnancy.<sup>1</sup> Similarly, Okamoto reported the case of  
102 CC in a 53-year old lady, 23 years after an elective abortion.<sup>16</sup> Sonobe reported the case of a 50-  
103 year old lady with CC 23 years after the last pregnancy.<sup>17</sup> Ito reviewed the literature of late  
104 presentation of CC. The authors noted that the latent period was more than 2 years in 7.5% of  
105 patient with CC.<sup>18</sup> A long latent period from last pregnancy can be explained by an  
106 asymptomatic pregnancy. Alternatively, the trophoblastic tissue retained in the uterus following  
107 the antecedent pregnancy could lie dormant for several years before transformation to  
108 malignancy.

109 A limitation of this case report is the lack of tissue evidence of recurrence. A biopsy from the  
110 metastatic CC is usually not carried out due to a risk of hemorrhage, However, the very high  $\beta$ -  
111 HCG level, serially increasing in presence of metastases is known to occur frequently in CC. In  
112 the setting of an antecedent molar pregnancy, albeit, 8 years earlier, the patient was diagnosed to  
113 have recurrence of CC.

114

## 115 **Conclusion**

116 CC is one of the most curable gynecological cancer, and should be included in the differential  
117 diagnosis of cancer occurring in postmenopausal woman. A few cases of a long latent period

118 after the last pregnancy have been reported, however, the mechanism of late onset of CC is not  
119 known. Retained trophoblastic tissue or an asymptomatic pregnancy between the last known  
120 pregnancy and the diagnosis of CC may explain, however, the actual cause remains speculative.  
121 Non-gestational CC should be considered an alternative diagnosis in such cases.

122

### 123 **Conflicts of Interest**

124 The authors declare no conflict of interests.

125

### 126 **Funding**

127 No funding was received for this study.

128

### 129 **Authors' Contribution**

130 AZ and IAB managed the case. RAM provided the images. RS managed the splenic artery  
131 embolization. AZ, RAM and RS drafted the manuscript. IAB reviewed the manuscript. All  
132 authors approved the final version of the manuscript.

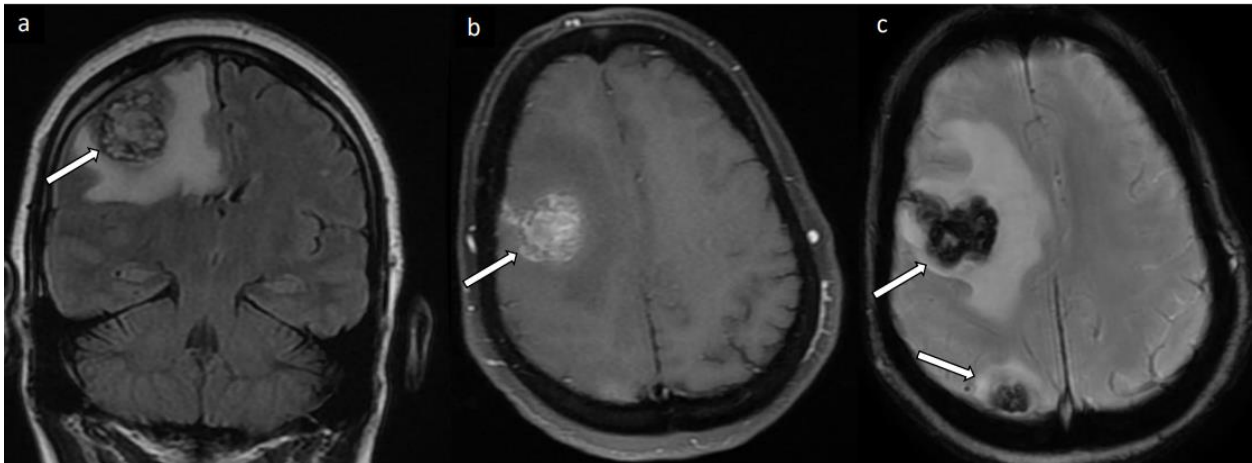
133

### 134 **References**

- 135 1. O'Neill CJ, Houghton F, Clarke J, McCluggage WG. Uterine gestational  
136 choriocarcinoma developing after a long latent period in a postmenopausal woman: the  
137 value of DNA polymorphism studies. *Int J Surg Pathol*. 2008 Apr;16(2):226-9. doi:  
138 10.1177/1066896907307038.
- 139 2. Rettenmaier MA, Khan HJ, Epstein HD, Nguyen D, Abaid LN, Goldstein BH. Gestational  
140 choriocarcinoma in the fallopian tube. *J Obstet Gynecol* 2013;33:  
141 912.doi: 10.3109/01443615.2013.834879
- 142 3. Chen, M.-J., Yang, J.-H., Lin, M.-C., Ho, H.-N. and Yang, Y.-S. An unusual gestational  
143 choriocarcinoma occurring primarily on the surface of a subserous leiomyoma. *BJOG*:

- 144 An International Journal of Obstetrics & Gynaecology, 2004;111: 188-190  
145 doi.org/10.1046/j.1471-0528.2003.00048.x
- 146 4. Hassadia A, Kew FM, Tidy JA, Wells M, Hancock BW. Ectopic gestational trophoblastic  
147 disease: a case series review. *J Reprod Med.* 2012 ;57(7-8):297-300. PMID: 22838244.
- 148 5. Desai NR, Gupta S, Said R, Desai P, Dai Q. Choriocarcinoma in a 73-year-old woman: a  
149 case report and review of the literature. *J Med Case Rep.* 2010; 4:379. doi: 10.1186/1752-  
150 1947-4-379.
- 151 6. Weiss S, Amit A, Schwartz MR, Kaplan AL. Primary choriocarcinoma of the vulva. *Int J*  
152 *Gynecol Cancer.* 2001;11(3):251-4. doi: 10.1046/j.1525-1438.2001.01005. x.
- 153 7. Wang L, Wan Y, Sun Y, Zhang X, Cheng X, Wu M et al. Pure non-gestational uterine  
154 choriocarcinoma in postmenopausal women: a case report with literature review. *Cancer*  
155 *Biol Ther.* 2019;20(9):1176-1182. doi: 10.1080/15384047.2019.1617564.
- 156 8. Tsukamoto N, Iwasaka T, Kashimura Y, Uchino H, Kashimura M, Matsuyama T.  
157 Gestational trophoblastic disease in women aged 50 or more. *Gynecol Oncol.*  
158 1985;20(1):53-61. doi: 10.1016/0090-8258(85)90124-6.
- 159 9. Mangla M, Singla D, Kaur H, Sharma S. Unusual clinical presentations of  
160 choriocarcinoma: A systematic review of case reports. *Taiwan J Obstet Gynecol.* 2017  
161 ;56(1):1-8. doi: 10.1016/j.tjog.2015.05.011.
- 162 10. Paradinas FJ. Pathology and classification of trophoblastic tumours *Gynaecologic*  
163 *Oncology* (Edited by: Coppleson M) Churchill Livingstone, London 1992;2:1013-1026.
- 164 11. ACOSTA-SISON H. Ab initio choriocarcinoma; two unusual cases. *Obstet Gynecol.*  
165 1959;13(3):350-2. PMID: 13633153.
- 166 12. Fox H and Buckley CH. The female genital tract and ovaries In. *Oxford text Book of*  
167 *Pathology* (Edited by: McGee JOD, Isaacson PG, Wright NA) Oxford university press,  
168 New York 1992; 2a:1565-1639
- 169 13. Samal SK, Rathod S, Ghose S. Postmenopausal choriocarcinoma: A rare case report. *J*  
170 *Midlife Health.* 2014;5(3):159-61. doi: 10.4103/0976-7800.141229.

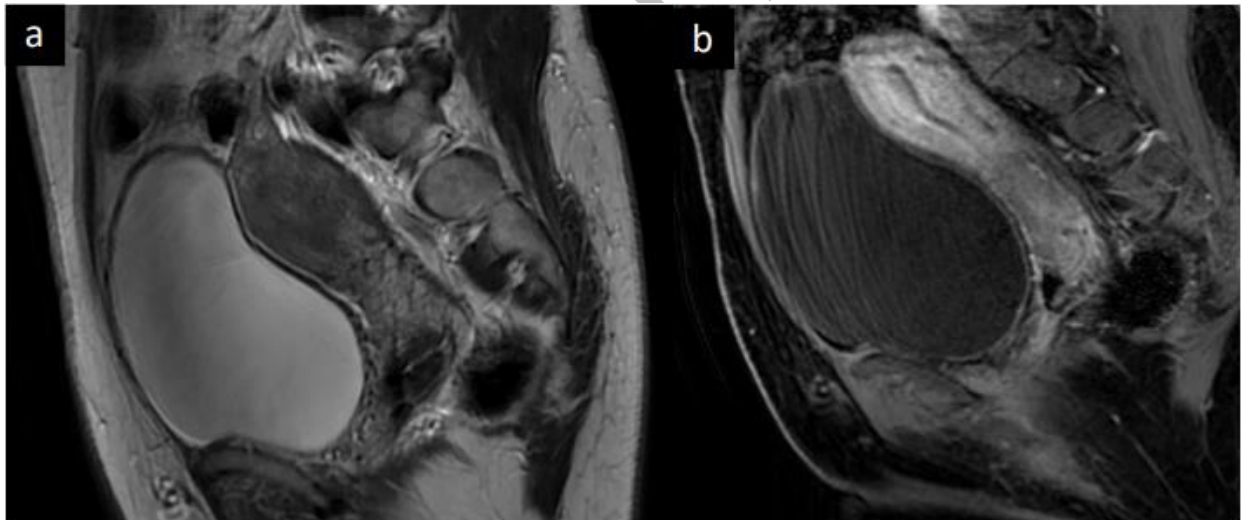
- 171 14. Hassadia A, Kew FM, Tidy JA, Wells M, Hancock BW. Ectopic gestational trophoblastic  
172 disease: a case series review. *J Reprod Med.* 2012;57(7-8):297-300. PMID: 22838244.
- 173 15. Soper JT, Mutch DG, Schink JC; American College of Obstetricians and Gynecologists.  
174 Diagnosis and treatment of gestational trophoblastic disease: ACOG Practice Bulletin  
175 No. 53. *Gynecol Oncol.* 2004;93(3):575-85. doi: 10.1016/j.ygyno.2004.05.013.
- 176 16. Okamoto T, Nomura S, Nakanishi T, Yamada S, Tomoda Y. A case of uterine  
177 choriocarcinoma with spontaneous rupture twenty-three years following the antecedent  
178 pregnancy. *J Obstet Gynaecol Res.* 1997;23(2):189-95. doi: 10.1111/j.1447-  
179 0756.1997.tb00830.x.
- 180 17. Sonobe H, Taguchi K, Ogawa K, Yoshioka T. Latent vaginal choriocarcinoma in a  
181 postmenopausal woman. *Acta Pathol Jpn.* 1976;26(5):611-8. doi: 10.1111/j.1440-1827.  
182 1976.tb00518. x.
- 183 18. Ito H, Tanaka T, Watanabe H, Yakushiji K, Sato H, Ito K. The nature of gestational  
184 choriocarcinoma latent over two years. *Nihon Sanka Fujinka Gakkai Zasshi.* 1985;  
185 37(5):730-4.  
186



187

188 **Figure1:** A) Coronal T2-weighted magnetic resonance imaging (MRI) reveals hemorrhagic  
189 lesion within the subcortical region of right parietal lobe measuring 2.7 x 2.2 cm with adjacent  
190 vasogenic edema; B) Axial contrast-enhanced T1-weighted MRI reveals multiple, enhanced,  
191 nodular lesions; C) Susceptibility weighted imaging demonstrates multiple hypointense,  
192 hemorrhagic lesions in the cortical and subcortical areas.

193

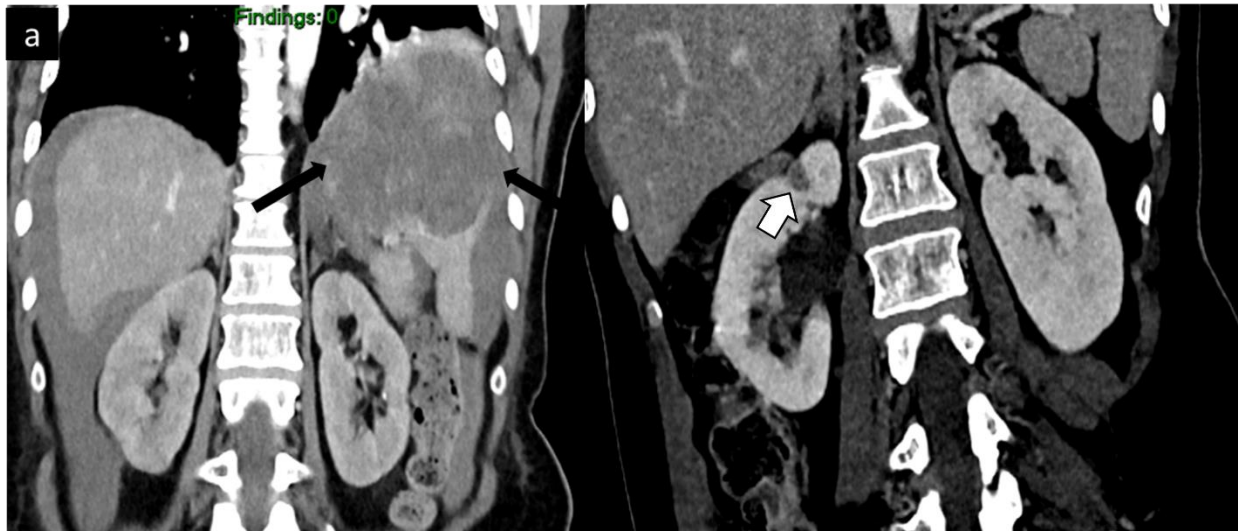


194

195 **Figure2:** A) Sagittal T2-weighted MR reveals normal uterus with normal endometrial stripe  
196 thickness and signal. Sagittal contrast-enhanced fat-suppressed T1-weighted MR image; B)  
197 demonstrates normal enhancement with no tumor seen.

198

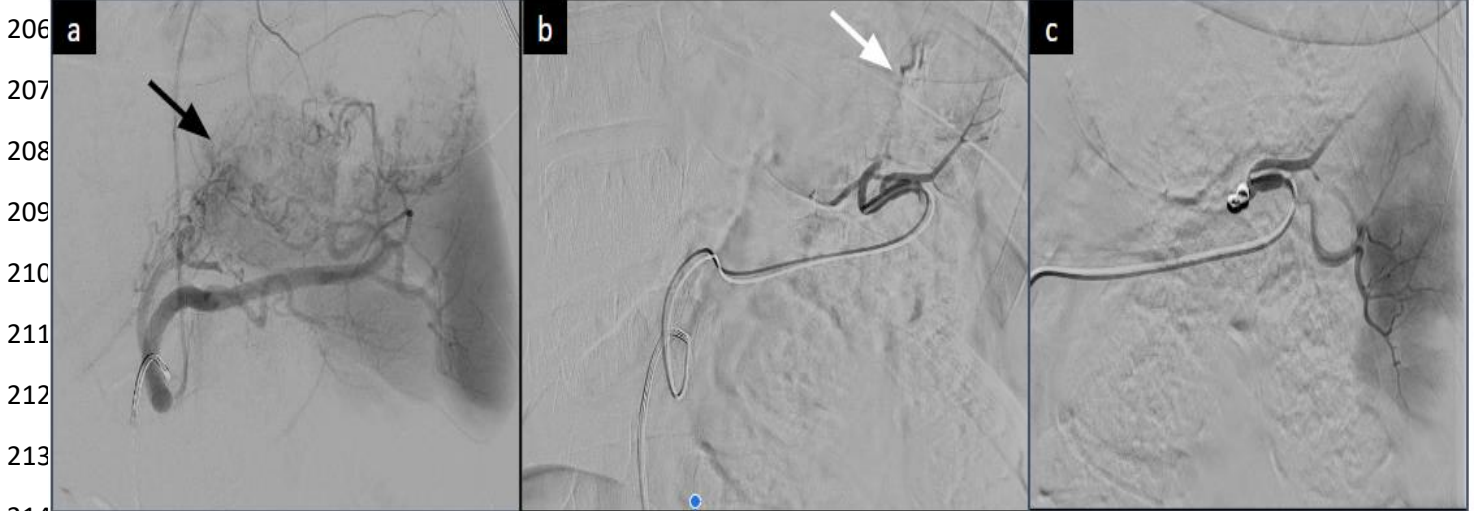




199

200 **Figure 3:** Contrast enhanced CT performed after 25 days from initial CT because patient showed  
 201 sudden drop of hemoglobin. Coronal reformat CT (a-b) reveals newly developed moderate  
 202 hemoperitoneum with rapid increase in size of splenic hemorrhagic masses (black arrow) that are  
 203 likely the cause of the retroperitoneal bleed. In addition, the right renal mass has also progressed  
 204 in size (white arrow)

205



206

207

208

209

210

211

212

213

214

215 **Figure 4:** Splenic artery embolization (distal technique). A) Celiac angiogram shows large round  
 216 mass medial to the spleen corresponding to the known metastatic deposit (black arrow). No  
 217 active extravasation; B) Distal splenic artery branches are selected. Abnormal blush with active  
 218 extravasation was seen from a branch of splenic artery (white arrow); C) A 2.7F Progreat  
 219 microcatheter was then inserted co-axially through the 5F catheter and advanced. This was super  
 220 selectively cannulated and embolization was then performed with PVA particles and coils. No  
 221 further extravasation seen (image C).