

Airway and Anaesthetic Challenges in a Child With Bronchus Suis and Superimposed Double Aortic Arch

A case report

*Nigel Kuriakose,¹ Mohamed Al-Ismaili,¹ Sameer Raniga,² Rohit Date,¹ Ali Al-Abady,¹ Zainab Al-Balushi³

تحديات المجرى التنفسي والتخدير في طفلة لديها شعبة هوائية متراكبة مع قوس الأبهر المزدوج

نايجل كوريكوس، محمد الإسماعيلي، سمير رانيجا، روهيت داتي، علي العبادي، زينب البلوشية

ABSTRACT: Bronchus suis or tracheal bronchus is an accessory bronchus arising from the trachea above the carina. Double aortic arch is a congenital vascular anomaly with persistence of both left and right aortic arches beyond fetal life which can form a vascular ring compressing the major airways and may be symptomatic. We report the case of a 16-month-old girl who had recurrent episodes of respiratory distress requiring multiple hospitalisations and was diagnosed at the Sultan Qaboos University Hospital, Muscat, Oman in 2019 with a double aortic arch compressing upon a tracheal bronchus causing symptomatic emphysema of the right upper lobe. This report presents anaesthetic and airway challenges during the patient's lobectomy. A single lumen cuffed endotracheal tube was successfully used as a bronchial blocker to occlude the origin of the aberrant bronchus. The position of the tube was confirmed intraoperatively using fibreoptic bronchoscopy. Following her discharge, she continued to have recurrent episodes of respiratory distress and three months after her last appointment she succumbed to her illness. To the best of the authors' knowledge, this is the first such reported case in Oman.

Keywords: Bronchus; Trachea; Aortic Arch; Endotracheal Intubation; Bronchoscopy; Anesthesia; Lobar Pneumonia; Oman.

المخلص: الشعبة الهوائية الخنزيرية أو القصبة الرغامية هي قصبة هوائية إضافية ناشئة من القصبة الهوائية فوق مستوى الجوّج. قوس الأبهر المزدوج هو شذوذ خلقي في الأوعية الدموية ناتج عن استمرار قوسي الأبهر الأيسر والأيمن إلى ما بعد مرحلة الجنين ويمكن أن تشكل حلقة وعائية تضغط على المجاري الهوائية الرئيسية وقد تؤدي إلى ظهور أعراض مرضية. في هذا المقال، نعرض حالة طفلة تبلغ من العمر 16 شهرا كانت تعاني من نوبات متكررة من ضيق التنفس تطلبت دخولا متكررا إلى المستشفى وتم تشخيصها في مستشفى جامعة السلطان قابوس بمسقط في عمان عام 2019 بقوس الأبهر المزدوج الذي يضغط على القصبة الرغامية مسببا انتفاخا في الفص العلوي للرئة اليمنى. يعرض هذا التقرير تحديات التخدير والمجرى التنفسي أثناء استئصال الفص الرئوي للمريضة. تم استخدام الأنبوب داخل الرغامى ذو التجويف المفرد بنجاح كحاجز للشعب الهوائية لإغلاق منشأ الشعبة الهوائية الشاذة. تم تأكيد موضع أنبوب الرغامى أثناء الجراحة باستخدام تنظير القصبات الليفي. بعد خروجها من المستشفى، استمرت إصابتها بنوبات متكررة من ضيق التنفس وبعد ثلاثة أشهر من آخر موعد للمراجعة استسلمت لمرضها. على حد علم المؤلفين، تعتبر هذه الحالة الأولى من نوعها التي تم الإبلاغ عنها في عمان.

الكلمات المفتاحية: شعبة هوائية؛ الرغامى؛ قوس الأبهر؛ تنبيب الرغامى؛ تنظير القصبات؛ التخدير؛ التهاب رئوي فصي؛ عمان.

BRONCHUS SUIS, ALSO KNOWN AS PIG BRONCHUS or tracheal bronchus, is an aberrant bronchus arising from the tracheal wall above the carina and is usually asymptomatic.¹ Although a normal variant in pigs, the incidence of bronchus suis in humans is 0.1–3% of which the most common is an aberrant bronchus to the right upper lobe.¹

Double aortic arch is a congenital vascular anomaly where the left and right aortic arches persist beyond fetal life. It can form a complete or incomplete vascular ring that can compress major airways and the oesophagus. The diagnosis of these two conditions

requires a high index of clinical suspicion and is confirmed using imaging techniques. A persistent double aortic arch presenting with compression of a bronchus suis has not been reported in the literature.

Case Report

A 16-month-old girl was diagnosed with bronchus suis and double aortic arch. She was born full-term and at one week of life started developing respiratory distress with recurrent respiratory tract infections requiring repeated hospitalisations and occasional

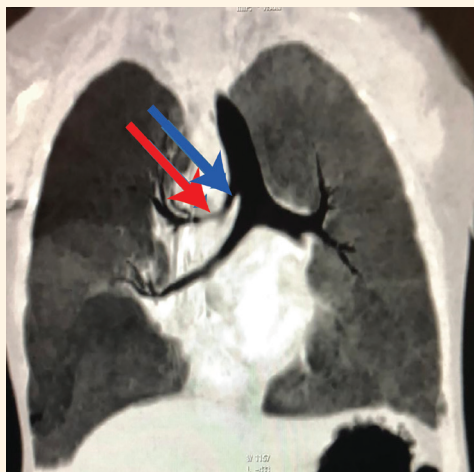

Figure 1: Pre-operative computed tomography scan of the chest of a 16-month-old girl showing the presence of an accessory bronchus (blue arrow) on the right side arising directly from the supracarinal trachea at a distance of 8-9 mm from the carina, suggestive of a tracheal bronchus. Entire right upper lobe is supplied by this accessory bronchus and there is marked focal thinning of the tracheal bronchus approximately 1 cm from its origin (red arrow). There is associated hyperinflation of the upper lobe of the right lung with paucity of the bronchovascular markings.

ventilatory support. Chest X-rays showed right upper lobe consolidation/collapse which was treated as lobar pneumonia.

A computed tomography (CT) scan performed during the sixth hospital admission at 16 months revealed an accessory bronchus arising from the posterolateral aspect of the trachea supplying the entire right side approximately 9 mm proximal to the carina suggestive of a bronchus suis. There was a focal luminal stenosis of the bronchus suis approximately 1 cm from its origin along with marked hyperinflation of the affected right upper lobe [Figure 1].

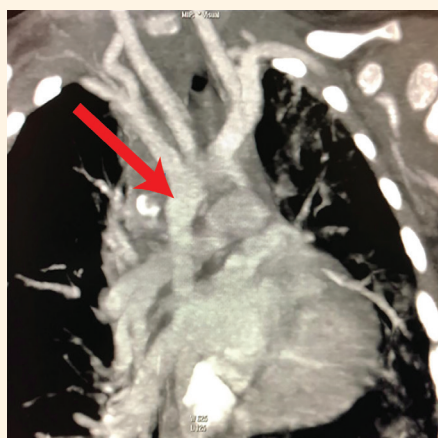

Figure 2: Coronal reformatted computed tomography scan of the lungs of a 16-month-old girl showing right-sided aortic arch (red arrow) with a midline descending aorta.

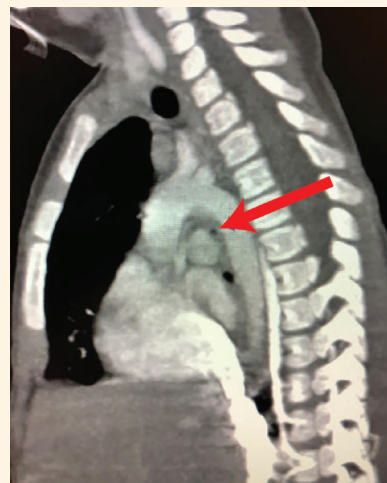

Figure 3: Sagittal reformatted computed tomography scan of the chest of a 16-month-old girl showing compression of the accessory tracheal bronchus (red arrow) between the anomalous right-sided aortic arch and pulmonary artery leading to luminal stenosis and bronchomalacia.

CT angiography revealed a persistent right-sided aortic arch, a midline descending aorta and an incomplete left aortic arch [Figure 2]. The accessory tracheal bronchus was markedly compressed between the abnormally placed right-sided descending aorta and the right pulmonary artery [Figure 3]. The left lung appeared small. The left pulmonary artery was absent with the left lung receiving arterial supply mainly from the bronchial arteries and multiple pleural branches.

An urgent lobectomy to relieve pressure effects of the emphysematous lobe on the normal lung tissue was performed. Preoperative echocardiography showed only mild pulmonary hypertension with pulmonary artery pressures of 30 mmHg. The child was on oxygen preoperatively via nasal cannula at 1 L/min. Her haemoglobin was 9.5 g/dL with neutrophilic leucocytosis. Her capillary blood gas showed a pH = 7.404, partial pressure of carbon dioxide = 51 mmHg, partial pressure of oxygen = 34 mmHg, serum bicarbonate concentration = 29.6 mmol/L, base excess = 7.6 mEq/L and lactate level = 2.7 mmol/L. On auscultation there was bilateral wheeze. On the day of surgery, the patient was still symptomatic. Intravenous access was secured. Following adequate preoxygenation, she was induced with intravenous fentanyl 2–3 µg/kg, propofol 2–3 mg/kg and cisatracurium 0.02–0.03 mg/kg. The trachea was intubated using C-MAC® (KARL STORZ SE & Co. KG, Tuttlingen, Germany) and 4.5 mm internal diameter single lumen tube (Covidien Shiley™ Cuffed Basic Endotracheal Tubes, Medtronic, Minneapolis, Minnesota, USA). Inflation pressure was limited and kept below 20 cm of water to avoid further hyperexpansion of the emphysematous lobe.

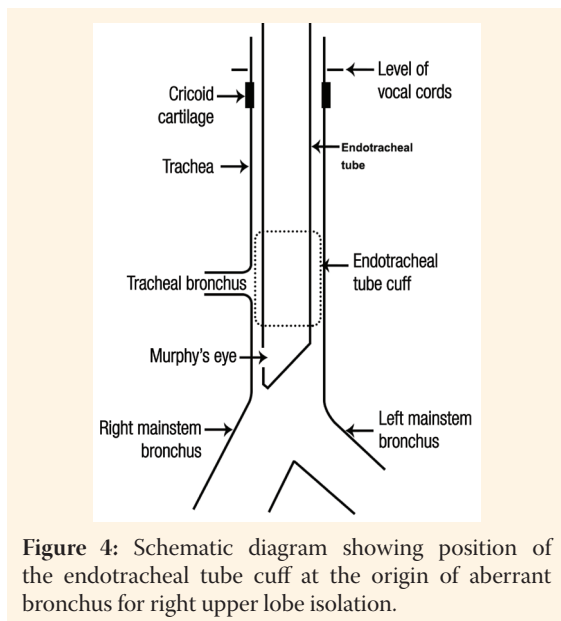


Figure 4: Schematic diagram showing position of the endotracheal tube cuff at the origin of aberrant bronchus for right upper lobe isolation.

General anaesthesia was maintained with oxygen, air and sevoflurane. Fibreoptic bronchoscopy was done which confirmed the presence of aberrant right upper lobe bronchus arising from the posterolateral wall of the trachea 8–9 mm proximal to the carina. It was fully compressed approximately 1 cm beyond its origin, which correlated with the preoperative CT findings. The left main bronchus was patent and normal in size. The right main bronchus was normal and gave rise to the right middle lobe and lower lobe bronchi. The endotracheal tube tip was positioned just above the carina with the aim of having the inflated cuff occlude the origin of the aberrant bronchus thus aiding in the thoracotomy and lobectomy [Figure 4].

In addition to standard intraoperative monitors, nasopharyngeal temperature and invasive left radial arterial pressure were monitored. Normothermia was maintained using warming blanket and fluid warmer. Right posterolateral thoracotomy through the fifth intercostal space was done in left lateral position. After dissection and separation of lobar arteries, veins and bronchus, the endotracheal tube was withdrawn under bronchoscopic guidance and the aberrant bronchus was transilluminated to help surgeons confirm its position. The right upper lobe was manually emptied of air and the endotracheal tube was then repositioned. On reinstatement of intermittent positive-pressure ventilation, the right upper lobe remained deflated confirming the proper placement of the endotracheal tube cuff at the origin of the aberrant bronchus. Ventilation parameters were maintained at a tidal volume = 70 mL, frequency = 26 breaths/min, oxygen fraction = 55% and positive end-expiratory pressure (PEEP) = 0–5 cm of water. A brief episode of desaturation during lung retraction was successfully

managed using the fraction of inspired oxygen = 100% and PEEP = 5 cm of water. The patient remained stable for the remainder of the procedure.

Intraoperative analgesia was achieved using intravenous fentanyl. Neuromuscular blockade was maintained using intermittent boluses of cisatracurium. At the end of the surgery, the patient was kept intubated and was transferred to the pediatric intensive care unit with stable haemodynamics for postsurgical observation and adequate pain management. Post-operative analgesia was maintained with intravenous morphine infusion.

The patient was extubated the next day and discharged from the hospital on post-operative day 17. Post-operative echocardiography after two months showed a worsened pulmonary artery pressure of 57 mmHg for which she was started on sildenafil. She had regular follow-up appointments for seven months. She continued to have recurrent episodes of respiratory distress for which she was on home oxygen and diuretics. The congenital absence of left pulmonary artery (causing decreased lung perfusion and V/Q mismatch) along with the right upper lobectomy may explain the persistent symptoms of her respiratory distress. Three months after her last appointment the child succumbed to her illness. As no autopsy was performed, the exact cause of death could not be ascertained. Consent was obtained over the telephone from the child's father regarding the publication of this case report.

Discussion

Tracheal bronchus was first described in 1785.² The right upper lobe bronchus normally originates approximately 1–3 cm distal to the carina. In the current patient, it arose from the right lateral wall of the trachea at a distance of <1 cm proximal to the carina.^{3,4} An aberrant bronchus is normally the result of additional tracheal outgrowth during early embryogenesis.⁵ Bronchus suis is usually right sided with greater predilection amongst males.⁶ It is commonly seen among syndromic children especially Down's syndrome and other bronchopulmonary anomalies.^{1,7}

Vascular rings and the presence of a double aortic arch account for <1% of congenital heart diseases.⁸ Hommel gave the first anatomical description of a double aortic arch in 1737 while Gross performed the first surgical correction in 1945.⁹ Classically, a double aortic arch is divided into three different types: right dominant aortic arch (75%), left dominant aortic arch (18%) and the balanced type (7%).¹⁰ Clinical symptoms with a double aortic arch usually appear in the first six

months of life.¹¹ The double aortic arch usually causes respiratory symptoms in 91% and gastrointestinal symptoms in 40% of cases.^{10,11}

The finding of a double aortic arch is usually an isolated cardiovascular malformation. In a study of 113 patients, coexisting cardiac anomalies occurred only in eight (7%); while in another study of 81 patients with double aortic arch such anomalies appeared in 14 patients (17%).⁸ In the current patient, other than the asymptomatic patent foramen ovale, no cardiac abnormalities were noted. The current case is unique as no previous literature on the coexistence of tracheal bronchus with double aortic arch could be found.

Challenges with airway management due to the presence of tracheal bronchus and double aortic arch have been reported separately for thoracic and nonthoracic surgeries, as well as for ventilation in the intensive care unit.¹² Due to its multifarious presentation, an undiagnosed tracheal bronchus during thoracic surgery may interfere with lung isolation and/or ventilation strategies depending on the surgical site and the type of one-lung ventilation device used.¹³ The preoperative condition of these patients is often challenging for anaesthesiologists. In the current case, the bronchial compression was revealed by respiratory distress and recurrent respiratory tract infections. Such children with recurrent respiratory tract infections coming for a corrective procedure maybe misdiagnosed.¹⁴ This may aggravate the symptoms of chronic airway obstruction through edema and inflammation. Meticulous preoperative evaluation is essential to comprehensively evaluate the presence of any compression, deviation or malformation of airways and the great vessels. The assessment for such patients should include a fiberoptic bronchoscopy for associated tracheal lesions such as tracheobronchomalacia and tracheal stenosis.¹⁵

Intraoperative one lung ventilation may be needed to prevent contamination of the dependent lung or to facilitate dissection during thoracotomy. Double-lumen tubes (DLT) may help the purpose. The smallest size of available conventional DLT is 26 Fr which is suitable for children above eight years of age. In the current patient, there was no question of lung soiling and hence complete lung isolation was not warranted with the approval of the surgeons.

Other available options for paediatric one-lung ventilation includes single-lumen endobronchial tubes, micro-cuff tubes, Marraro bilumen tubes and bronchial blockers. Single lumen endobronchial tubes are longer than standard endotracheal tubes but with smaller external diameters and smaller cuffs. An

important feature of these endobronchial tubes is a narrow bronchial cuff and a relatively short distance from the proximal edge of that cuff to the distal tip of the tube. Hence, there is less chance of the bronchial cuff obstructing the upper lobe bronchus and the margin of safety is much larger compared to standard endotracheal tubes. A double lumen tube is used for neonates and small children up to two or three years of age and consists of two uncuffed tubes that are moulded together so as to function like conventional DLTs.¹⁶ The smallest Univent tube has an internal diameter of 3.5 mm and is used for children less than six years of age. The smallest Arndt paediatric endobronchial blocker is 5 Fr which may be suitable for children more than two years of age as it requires at least a 4.5 mm internal diameter endotracheal tube. A Fogarty catheter can also be used for lung isolation in infants.

A single-lumen endotracheal tube is viewed as the simplest method of obtaining lung isolation. The technique for placement is straightforward and can be accomplished with standard intubation equipment. The current patient only needed occlusion of the aberrant bronchus which could be achieved with the inflated cuff of a normal single lumen endotracheal tube.

In the current patient, although the right upper lobe was emphysematous, it could have been contributing to the ventilation and oxygenation while the hyperinflated right upper lobe compressed other areas of the lung. Meanwhile, the occlusion and surgical manipulation of the right upper lobe could be the reason for the transient episode of desaturation intraoperatively. Postoperatively, airway obstruction may persist in approximately 30% of cases despite surgical correction which may warrant artificial ventilation or continuous positive airway pressure ventilation.⁸

Conclusion

This case report highlights that clinicians should consider rare anatomical variants such as a coexisting bronchus suis and a double aortic arch in children who present with repeated pneumonia, stridor or emphysematous lobes when other common aetiologies are excluded. The use of a single lumen cuffed endotracheal tube for lobe isolation and intraoperative fiberoptic bronchoscopy for positional confirmation would be a pragmatic choice in the airway management of these patients.

References

1. Ikeno S, Mitsuhashi H, Saito K, Hirabayashi Y, Akazawa S, Kasuda H, et al. Airway management for patients with a tracheal bronchus. *Br J Anaesth* 1996; 76:573–5. <https://doi.org/10.1093/bja/76.4.573>.
2. Lai KM, Hsieh MH, Lam F, Chen CY, Chen TL, Chang CC. Anesthesia for patients with tracheal bronchus. *Asian J Anesthesiol* 2017; 55:87–8. <https://doi.org/10.1016/j.aja.2017.09.002>.
3. Wong DT, Kumar A. Case report: Endotracheal tube malposition in a patient with a tracheal bronchus. *Can J Anaesth* 2006; 53:810–13. <https://doi.org/10.1007/BF03022798>.
4. Barat M, Konrad HR. Tracheal Bronchus. *Am J Otolaryngol* 1987; 8:118–22. [https://doi.org/10.1016/s0196-0709\(87\)80034-0](https://doi.org/10.1016/s0196-0709(87)80034-0).
5. Dosi RA, Jain A, Joshi P, Motiwale S, Songara A. A rare case of a tracheal bronchus. *JACP* 2018; 6:76–9. https://doi.org/10.4103/jacp.jacp_28_17.
6. Singh K, Agrawal A, Sahu D, Chaudhary M. Extremely rare congenital tracheobronchial anomaly of bronchus suis: A hidden cause of pulmonary infection. *Lung India* 2017; 34:577–9.
7. Bertrand P, Navarro H, Caussade S, Holmgren N, Sánchez I. Airway anomalies in children with Down syndrome: Endoscopic findings. *Pediatr Pulmonol* 2003; 36:137–41. <https://doi.org/10.1002/ppul.10332>.
8. Houba A, Bensghir M, Ahtil R, Slioui B, Balkhi H, Lalaoui SJ. Double aortic arch presenting with respiratory distress: A case report and review of the literature. *Saudi J Anaesth* 2017; 11:483–5. https://doi.org/10.4103/sja.SJA_249_17.
9. Hardin RE, Brevetti GR, Sanusi M, Bhaskaran D, Burack JH, Genovesi MH, et al. Treatment of symptomatic vascular rings in the elderly. *Tex Heart Inst J* 2005; 32:411–415.
10. Backer CL, Mavroudis C, Rigsby CK, Holinger LD. Trends in vascular ring surgery. *J Thorac Cardiovasc Surg* 2005; 129:1339–47. <https://doi.org/10.1016/j.jtcvs.2004.10.044>.
11. Alsenaidi K, Gurofsky R, Karamlou T, Williams WG, McCrindle BW. Management and outcomes of double aortic arch in 81 patients. *Pediatrics* 2006; 118:e1336–41. <https://doi.org/10.1542/peds.2006-1097>.
12. Agarwal S, Banks MA, Dalela S, Bates WB, Castresana MR. Incidental finding of tracheal bronchus complicating the anesthetic management of a left video-assisted thoracoscopic procedure. *J Anaesthesiol Clin Pharmacol* 2016; 32:106–8. <https://doi.org/10.4103/0970-9185.168167>.
13. Moon YJ, Kim SH, Park SW, Lee YM. The implications of a tracheal bronchus on one-lung ventilation and fiberoptic bronchoscopy in a patient undergoing thoracic surgery: A case report. *Can J Anaesth* 2015; 62:399–402. <https://doi.org/10.1007/s12630-014-0293-8>.
14. Zhang Q, Fu Z, Dai J, Geng G, Fu W, Tian D. Recurrent wheezing and cough caused by double aortic arch, not asthma. *Case Rep Cardiol* 2017. Article ID 8079851, 4 pages, 2017. <https://doi.org/10.1155/2017/8079851>.
15. Lee DK, Kim YM, Kim HZ, Lim SH. Right upper lobe tracheal bronchus: Anesthetic challenge in one-lung ventilated patients - A report of three cases. *Korean J Anesthesiol* 2013; 64:448–50. <https://doi.org/10.4097/kjae.2013.64.5.448>.
16. Marraro G. Selective endobronchial intubation in paediatrics: The Marraro paediatric bilumen tube. *Pediatr Anesth* 1994; 4:255–8. <https://doi.org/10.1111/j.1460-9592.1994.tb00174.x>.