

Chronic Blunt Traumatic Thoracic Aortic Injuries

Report of three cases from Oman

*Sara S.H. Al-Adawi,¹ Ahmed Naiem,² Ibrahim Abdelhady,³ Rashid Al-Sukaiti,⁴ Mahmood Al-Hajeri,⁵ Edwin Stephen,³ Sulaiman Al-Shamsi,⁶ Khalifa Al-Wahaibi³

إصابات رضحية كلية مزمنة في الأجر الصدري تقرير عن ثلاث حالات من عُمان

سارة العدوية، احمد نعيم، ابراهيم عبد الهادي، راشد السكيتي، محمود الهاجري، ادوين ستيفن، سليمان الشامسي، خليفة الوهيبي

ABSTRACT: Blunt thoracic aortic injuries are potentially lethal. Those who survive may form an organised haematoma in the periadventitial space resulting in a pseudoaneurysm, which may be identified incidentally decades later. While the role of thoracic endovascular aortic repair (TEVAR) in acute settings has been established, its role in chronic cases is yet to be defined. We report three cases that were diagnosed incidentally six, nine and 18 years after the injury. Two were managed by TEVAR while the third declined intervention and is on annual follow-up. Patients with asymptomatic and stable pseudoaneurysms of the descending thoracic aorta should be offered surveillance versus TEVAR because the risk of rupture is not negligible, whilst taking into account the patient's level of physical activity. These three cases highlight the importance of early diagnosis of aortic injuries in blunt trauma and its grading.

Keywords: Thoracic Aortic Aneurysm; Endovascular Procedures; False Aneurysm; Nonpenetrating Wounds; Traffic Accidents; Oman.

المخلص: تكمن خطورة إصابات الشريان الأورطي الصدري في إمكانية إفضائها إلى الوفاة. ويتكون عادةً ورم دموي منظم في المنطقة المحيطة بالإصابة يؤدي إلى تمدد شرياني يُكتشف بالصدفة بعد فترة طويلة من الزمن. وعلى الرغم من أهمية دور عملية إصلاح تمدد الأوعية الدموية في الإصابات الحادة، إلا أن دورها في الإصابات المزمنة غير واضح. نقدم هنا تقريراً عن ثلاثة حالات تم تشخيصها بالصدفة بعد انقضاء فترة تتراوح بين 6، 9 و 18 عاماً من الإصابة. تم علاج حالتين جراحياً، بينما رفض المريض الثالث التدخل الجراحي وتتم متابعته سنوياً. يجب أن يخضع المرضى للمراقبة الدورية بعد التشخيص بتمدد شرياني في ظل خلوهم من الأعراض. مع وضع التدخل الجراحي كخيار مهم بسبب خطر حدوث مزق أورطي. كما يجب مراعاة مستوى النشاط البدني للمريض عند اختيار الخطة العلاجية. يهدف هذا البحث إلى تسليط الضوء على أهمية التشخيص المبكر لإصابات الشريان الأورطي الصدري المزمنة.

الكلمات المفتاحية: تمدد الأوعية الدموية للشريان الأورطي؛ عمليات الأوعية الدموية؛ تمدد الأوعية الدموية؛ الجروح؛ الحوادث؛ حركة المرور؛ عُمان.

BLUNT THORACIC AORTIC INJURIES (BTAI) ARE potentially fatal. Those with lesser degrees of injury may survive with a haematoma formation in the periadventitial space followed by subsequent pseudoaneurysm formation. With the advent of better radiological imaging, cases have emerged where individuals survive the initial injury and live with a pseudoaneurysm for decades until its incidental discovery on imaging. The management of such cases has not been clearly established as it is underreported. We report three cases of chronic pseudoaneurysms detected six, nine and 18 years after the initial injury.

Case One

In 2015, a 37-year-old male patient was referred to Sultan Qaboos University Hospital (SQUH) with findings of

a widened mediastinum on a chest X-ray performed for a routine health screening for his promotion as an army officer. He denied any chest pain, hoarseness of voice, shortness of breath or other symptoms. The patient had a history of a motor vehicle collision (MVC) 18 years prior to presentation when he had undergone a laparotomy and splenectomy. Following these surgeries, he carried on regular official and recreational activities in the army with no restrictions. He had no family history suggestive of connective tissue disorder. A subsequent computed tomography angiography (CTA) revealed a 3.8 cm pseudoaneurysm at the proximal descending thoracic aorta at the origin of the left subclavian artery with partial calcification [Figure 1]. Having discussed the risks and benefits of endovascular intervention, a thoracic endovascular aortic repair (TEVAR) was performed using a 30 × 100 mm Zenith Alpha™ Thoracic Endovascular Graft

¹Department of General Surgery, Oman Medical Specialty Board, Muscat, Oman; ²Department of Vascular Surgery, McGill University, Montreal, Canada; ³Department of Vascular Surgery and ⁴Radiology, Sultan Qaboos University Hospital, Muscat, Oman; ⁵Department of Radiology and ⁶Vascular Surgery, The Royal Hospital, Muscat, Oman

*Corresponding Author's e-mail: sara93916@gmail.com

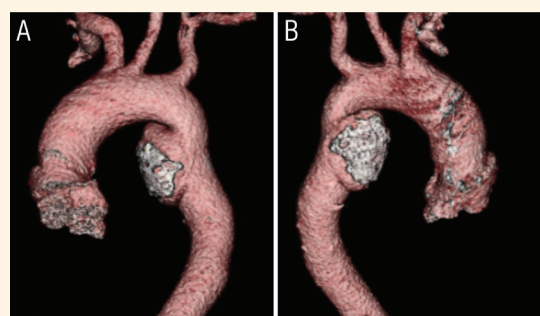


Figure 1: 3D reconstructed image of (A) anterior and (B) posterior view of an incidentally detected pseudoaneurysm of the descending thoracic aorta in a 37-year-old male patient, 18 years after initial trauma.

(Cook Medical, Bloomington, Indiana, USA) through a femoral cutdown. He has been under annual follow up with CTA. In 2018, a linear intra-stent thrombus was seen [Figure 2]. He was started on rivaroxaban 15 mg twice daily for three weeks, followed by 20 mg once daily for nine weeks. Repeat CTA in 2019 showed no progression of the thrombus, so he was switched to clopidogrel 75 mg once daily. His latest CTA in January 2020 showed no thrombus progression and no complications related to the stent-graft. He will be continued on antiplatelet therapy as long as there is evidence of thrombus on annual imaging. Meanwhile, he continues his army activities with a reduction in physical intensity and contact sport.

Case Two

In January 2017, a 37-year-old mother of four presented at SQUH and underwent a CT imaging of the abdomen for peritonitis. She was diagnosed with an acutely inflamed appendix and an incidental finding of a 7.5 cm right-sided diaphragmatic defect containing a herniated right lobe of the liver. A CT chest scan was performed to assess the diaphragmatic hernia further. It revealed a saccular pseudoaneurysm at the aortic isthmus, measuring 3 × 3 cm, that was distal to the

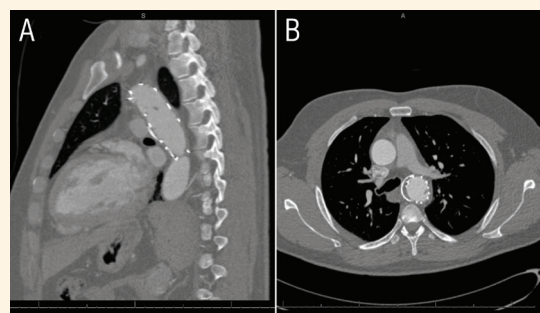


Figure 2: A linear intra-stent thrombus in a 37-year-old male patient seen on computed tomography angiography after thoracic endovascular aortic repair.

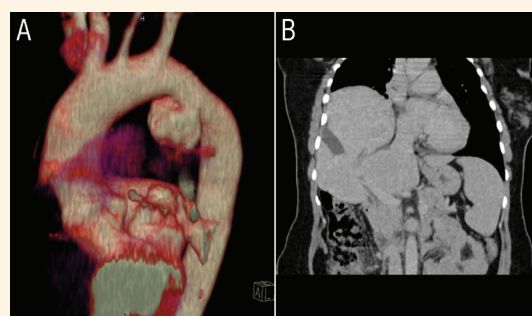


Figure 3: (A) Computed tomography scan showing an incidentally detected saccular pseudoaneurysm at the aortic *isthmus*, and (B) right diaphragmatic hernia containing the right lobe of the liver in a 37-year-old female patient, nine years after initial trauma.

left subclavian artery by 1.5 cm and with a curvilinear wall calcification [Figure 3]. Her history revealed an MVC nine years prior. She had occasional stabbing chest pain and tenderness over the left chest wall, which was managed with analgesics; otherwise, she lived an active lifestyle and had two of her children after the MVC. Following a discussion, she underwent a successful TEVAR through a femoral cutdown using a 28 × 100 mm Valiant™ thoracic stent graft with the Captivia™ delivery system (Medtronic, Minneapolis, Minnesota, USA) under fluoroscopic guidance. She has been on aspirin 75 mg once daily and under annual follow-up since. Her latest CTA in November 2019 showed the stent-graft in place and no endoleak or in-stent thrombus.

Case Three

In May 2019, a 29-year-old male patient was referred to SQUH with an incidental finding of a pseudoaneurysm of the descending thoracic aorta [Figure 4]. The patient denied any symptoms, had normal blood pressure readings and his examination was unremarkable. He was working with the military and regularly

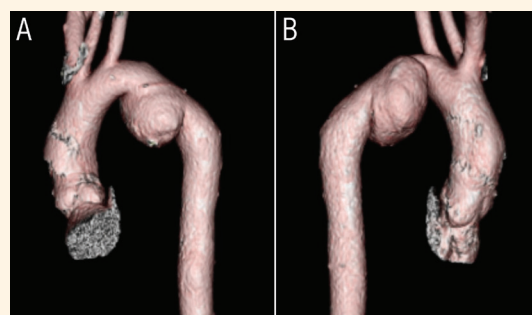


Figure 4: 3D reconstructed image of (A) anterior and (B) posterior view of an incidentally detected pseudoaneurysm of the descending thoracic aorta in a 29-year-old male patient, six years after initial trauma.

participating in intense physical activity. His history was significant for an MVC six years prior. After exploring all options and its associated risks and benefits, the patient opted to decline any intervention. He was given a follow-up appointment and instructions to report back if he developed any symptoms such as chest pain, inter-scapular pain, hoarseness of voice, dysphagia, dyspnoea or haemoptysis.

Discussion

We report three cases of pseudoaneurysms diagnosed incidentally on imaging several years after the initial trauma. All were young, otherwise healthy members of society. Two were regularly performing strenuous physical activities associated with their job as military personnel. The third was a female of childbearing age who had two pregnancies between the time of trauma until the pseudoaneurysm diagnosis.

BTAI can be classified into four grades: grade 1 signifies intimal tear; grade 2 is an intramural haematoma; grade 3 is a pseudoaneurysm; and grade 4 is the free rupture of the aorta.¹ The presence of shock, higher injury severity scores and concomitant brain injury are associated with a poor outcome from BTAI.²

The Society of Vascular Surgery and Eastern Association for the Surgery of Trauma recommend endovascular repair over open surgery, given the reduced rates of complications in the acute setting for grade 2–4 injuries. Grade 1 injuries may be managed non-operatively, but newer studies have emerged to suggest further that non-operative management for grade 2 injuries may also be acceptable.^{3–6}

Late complications of conservative treatment of aortic injuries include dissection, free rupture and pseudoaneurysms.⁷ Chronic pseudoaneurysms have been reported to develop years after the injury.^{7–9} In the current patients, these pseudoaneurysms were incidentally discovered several years after the trauma. Still, they could have led to free rupture when exposed to increased intra-abdominal and thoracic pressure during military exercise or labour.

There has been documented success of TEVAR in chronic traumatic pseudoaneurysms of the thoracic aorta.^{10,11} This is not free of complications including endoleak, stroke, paraplegia, intra-graft thrombus and mortality.^{5,10,12,13} Left subclavian artery coverage requiring carotid-subclavian bypass or use of fenestrated or chimney grafts must also be considered.¹³ While there are continuous improvements in profile and structure of stent-grafts, only time will tell whether the newer stent-grafts would have decreased re-intervention rates than their predecessors.

Non-operative management could be considered if the pseudoaneurysm remains stable in size, asymptomatic, densely calcified and with no connective tissue disease history. Literature in this regard is limited to earlier experience in this field.¹⁴

The role of open surgical therapy in acute and chronic cases cannot be ruled out. However, it is associated with higher morbidity and is reserved for those patients who are unsuitable for TEVAR. Literature is limited to case reports concerning open repair.¹⁵

In the current report, the risks of free rupture versus complications of TEVAR were weighed. Considering their lifestyles, all three patients were offered TEVAR. One patient developed intra-stent thrombus, which was managed with anticoagulant therapy. The second patient did not have any complications after TEVAR. The third patient refused intervention, so he was offered regular follow-up to ensure adequate blood pressure control with a CT angiogram every two years, followed by a yearly transoesophageal echocardiogram.¹⁶

Conclusion

Chronic, stable and a calcified wall are features that might support successful non-operative management of pseudoaneurysms formed after BTAI. Non-operative management of BTAI should only be offered with imaging surveillance and regular follow-up. The level of physical activity and its impact on exertional arterial pressure changes should be considered in decision-making.

References

1. Azizzadeh A, Keyhani K, Miller 3rd CC, Coogan SM, Safi HJ, Estrera AL. Blunt traumatic aortic injury: Initial experience with endovascular repair. *J Vasc Surg* 2009; 49:1403–8. <https://doi.org/10.1016/j.jvs.2009.02.234>.
2. Lin C-C, Liu K-S, Chen H-W, Huang Y-K, Chu J-J, Tsai F-C, et al. Blunt aortic injury: Risk factors and impact of surgical approaches. *Surg Today* 2016; 46:188–96. <https://doi.org/10.1007/s00595-015-1152-0>.
3. Lee WA, Matsumura JS, Mitchell RS, Farber MA, Greenberg RK, Azizzadeh A, et al. Endovascular repair of traumatic thoracic aortic injury: Clinical practice guidelines of the Society for Vascular Surgery. *J Vasc Surg* 2011; 53:187–92. <https://doi.org/10.1016/j.jvs.2010.08.027>.
4. Fox N, Schwartz D, Salazar JH, Haut ER, Dahm P, Black JH, et al. Evaluation and management of blunt traumatic aortic injury: A practice management guideline from the Eastern Association for the Surgery of Trauma. *J Trauma Nurs* 2015; 22:99–110. <https://doi.org/10.1097/JTN.0000000000000118>.
5. Soong TK, Wee IJY, Tseng FS, Syn N, Choong AMTL. A systematic review and meta-regression analysis of non-operative management of blunt traumatic thoracic aortic injury in 2897 patients. *J Vasc Surg* 2019; 3:941–53.e13. <https://doi.org/10.1016/j.jvs.2018.12.045>.

6. Sandhu HK, Leonard SD, Perlick A, Saqib NU, Miller 3rd CC, Charlton-Ouw KM, et al. Determinants and outcomes of non-operative management for blunt traumatic aortic injuries. *J Vasc Surg* 2018; 2:389–98. <https://doi.org/10.1016/j.jvs.2017.07.111>.
7. Mosquera VX, Marini M, Lopez-Perez JM, Muñoz-Garcia J, Herrera JM, Cao I, et al. Role of conservative management in traumatic aortic injury: Comparison of long-term results of conservative, surgical, and endovascular treatment. *J Thorac Cardiovasc Surg* 2011; 3:614–21. <https://doi.org/10.1016/j.jtcvs.2010.10.044>.
8. Rabin J, DuBose J, Sliker CW, O'Connor JV, Scalea TM, Griffith BP. Parameters for successful non-operative management of traumatic aortic injury. *J Thorac Cardiovasc Surg* 2014; 1:143–9. <https://doi.org/10.1016/j.jtcvs.2013.08.053>.
9. Finkelmeier BA, Mentzer Jr RM, Kaiser DL, Tegtmeier CJ, Nolan SP. Chronic traumatic thoracic aneurysm. Influence of operative treatment on natural history: An analysis of reported cases, 1950-1980. *J Thorac Cardiovasc Surg* 1982; 84:257–66.
10. Szostek MM, Jakuczun W, Alagbari A, Pogorzelski R, Szostek M, Oşka M, et al. Chronic traumatic thoracic aortic aneurysms—results of endovascular treatment. Fourteen-year single-center experience. *Int Angiol* 2015; 34:506–13.
11. Fattori R, Napoli G, Lovato L, Russo V, Pacini D, Pierangeli A, et al. Indications for, timing of, and results of catheter-based treatment of traumatic injury to the aorta. *AJR Am J Roentgenol* 2002; 179:603–9. <https://doi.org/10.2214/ajr.179.3.1790603>.
12. Abdoli S, Ham SW, Wilcox AG, Fleischman F, Lam L. Symptomatic intragraft thrombus following endovascular repair of blunt thoracic aortic injury. *Ann Vasc Surg* 2017; 42:305.e7–12. <https://doi.org/10.1016/j.avsg.2016.12.007>.
13. DuBose JJ, Leake SS, Brenner M, Pasley J, O'Callaghan T, Luo-Owen X, et al. Contemporary management and outcomes of blunt thoracic aortic injury: A multicenter retrospective study. *J Trauma Acute Care Surg* 2015; 78:360–9. <https://doi.org/10.1097/TA.0000000000000521>.
14. Katsumata T, Shinfeld A, Westaby S. Operation for chronic traumatic aortic aneurysm: When and how? *Ann Thorac Surg* 1998; 66:774–8. [https://doi.org/10.1016/S0003-4975\(98\)00519-0](https://doi.org/10.1016/S0003-4975(98)00519-0).
15. Miller S, Kumar P, Van den Bosch R, Khanafer A. Chronic Thoracic Aortic Aneurysm Presenting 29 Years following Trauma. *Case Rep Surg* 2015; 2015:470917. <https://doi.org/10.1155/2015/470917>.
16. Hiratzka LF, Bakris GL, Beckman JA, Bersin RM, Carr VE, Casey DE, et al. 2010 ACCF/AHA/AATS/ACR/ASA/SCA/SCAI/SIR/STS/SVM guidelines for the diagnosis and management of patients with thoracic aortic disease: A report of the american college of cardiology foundation/american heart association task force on practice guidelines, American Association for Thoracic Surgery, American College of Radiology, American Stroke Association, Society of Cardiovascular Anesthesiologists, Society for Cardiovascular Angiography and Interventions, Society of Interventional Radiology, Society of Thoracic Surgeons, and Society for Vascular Medicine. *Circulation* 2010; 121:266–369. <https://doi.org/10.1161/CIR.0b013e3181d4739e>.