

# Maxillary Artery Pseudoaneurysm as a Complication of Maxillofacial Injuries

## Report of three cases and literature review

\*Noor J. Al-Saadi,<sup>1</sup> Abdulaziz Bakathir,<sup>2</sup> Ali Al-Mashaikhi,<sup>3</sup> Ahmed Al-Hashmi,<sup>4</sup> Ahmed Al-Habsi,<sup>5</sup> Faisal Al-Azri<sup>6</sup>

## تمدد كاذب للشريان الفكي العلوي كإحدى مضاعفات إصابات الوجه والفكين تقرير ثلاث حالات مع مراجعة أدبية

نور جبار الساعدي، عبد العزيز باكثير، علي المشايخي، أحمد الهاشمي، أحمد الحبسي، فيصل العزري

**ABSTRACT:** Traumatic maxillary artery pseudoaneurysm is an uncommonly reported complication in the field of oral and maxillofacial surgery. It is usually discovered incidentally, either early after trauma or weeks-to-months later. Quick recognition and prompt management are essential to avoid devastating consequences. In this paper, we report three uncommon cases of maxillary artery pseudoaneurysm recognised during the surgical management of maxillofacial injuries in Muscat, Oman. All cases presented as sudden brisk bleeding during the intraoperative surgical repair and were subsequently diagnosed and successfully managed by endovascular embolisation with platinum coils. This case report highlights the clinical presentation, diagnosis and management of maxillary artery pseudoaneurysm, in addition to a brief review of the literature.

**Keywords:** Maxillofacial Injuries; Maxillary Artery; Pseudoaneurysm; Mandibular Condyle; Angiography; Therapeutic Embolization; Case Report; Oman.

**الملخص:** يعتبر التمدد الكاذب للشريان الفكي العلوي من المضاعفات الغير شائعة في مجال جراحة الفم والوجه والفكين. والتي عادة ما يتم اكتشافها عرضاً، إما في وقت مبكر بعد الإصابة أو بعد أسابيع إلى أشهر لاحقاً. التشخيص والمعالجة السريعة مهم جداً لتفادي المضاعفات الوخيمة لهذه الحالة. نعرض في هذا التقرير ثلاث حالات غير مألوفة لتمدد كاذب للشريان الفكي العلوي والتي تم تشخيصها أثناء المعالجة الجراحية لإصابات الوجه والفكين. جميع الحالات تعرضت لنزف حاد ومفاجئ أثناء العلاج الجراحي لهذه الحالات والتي تم بعد ذلك تشخيصها ومعالجتها بنجاح عن طريق غلق التمدد الكاذب للشريان من خلال وضع الوشائع داخل الأوعية الدموية باستخدام أسلاك البلاتين الناعم. يناقش هذا التقرير الأعراض السريرية بالإضافة إلى التشخيص والعلاج المناسب لحالات التمدد الكاذب للشريان الوجهي مع مراجعة أدبية مختصرة.

**الكلمات المفتاحية:** إصابات الوجه والفكين؛ الشريان الفكي العلوي؛ تمدد كاذب؛ لقمة الفك السفلي؛ تصوير الأوعية؛ الانصمام العلاجي؛ تقرير حالة؛ عمان.

**T**RAUMA IS A LEADING CAUSE OF VARIOUS forms of arterial injuries, including intimal injury, rupture, thrombosis, arteriovenous fistula, true aneurysm, pseudoaneurysm and dissecting aneurysm.<sup>1</sup> Maxillofacial arterial pseudoaneurysms have rarely been reported in the scientific literature.<sup>1-10</sup> A pseudoaneurysm usually occurs following an incomplete tear of an arterial wall. While the inner most layer of the artery and the blood flow are maintained, haemorrhage from the outer two layers occurs into the adjacent soft tissues. This leads to the formation of a haematoma that later organises and, with the continuous arterial pressure, creates an endothelial-lined sac in continuity with the arterial wall, which has the potential to expand further and rupture.<sup>4-6</sup>

This case report describes three cases of maxillary artery pseudoaneurysm (MAP) encountered

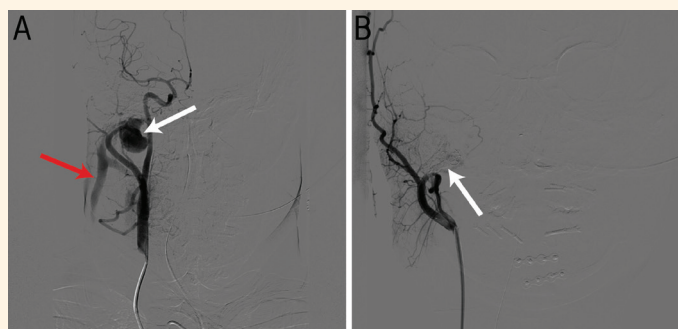during surgeries involving the mandibular condyle and coronoid processes as part of the management of maxillofacial injuries. All cases presented intraoperatively with brisk bleeding and were diagnosed and successfully managed by angiography and endovascular embolisation with platinum coils.

### Case One

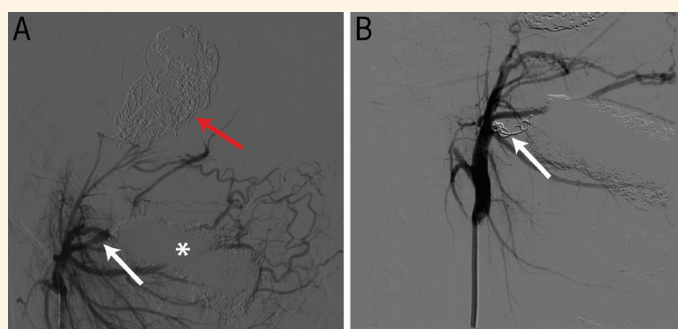
A 32-year-old male patient was referred to the Oral & Maxillofacial Surgery Unit at Al-Nahda Hospital, Muscat, Oman, in 2013 with a prolonged mandibular dislocation for five months following a motor vehicle collision (MVC). Clinical examination and computed tomography (CT) scan revealed bilateral anterior mandibular dislocation and a malunion of a mandibular symphyseal fracture. Manual reduction of the dislocated mandible, aided by a muscle relaxant

<sup>1</sup>Department of General Surgery, Al Rustaq Hospital, Al Rustaq, Oman; <sup>2</sup>Departments of <sup>2</sup>Dental & Maxillofacial Surgery and <sup>6</sup>Radiology & Molecular Imaging, Sultan Qaboos University Hospital, Muscat, Oman; <sup>3</sup>Oral and Maxillofacial Surgery Program, Oman Medical Specialty Board, Muscat, Oman; <sup>4</sup>Department of Dental and Maxillofacial Surgery, Al Nahda Hospital, Muscat, Oman; <sup>5</sup>Department of Radiology, Khoula Hospital, Muscat, Oman

\*Corresponding Author's e-mail: Dr.noorjabbar@gmail.com



**Figure 1:** Digital subtraction angiography images of the anterior-posterior view of the right external carotid artery (ECA) of a 32-year-old male patient showing (A) right maxillary artery pseudoaneurysm (MAP; white arrow) with early filling of the right internal jugular vein indicating an arteriovenous *fistula* (AVF; red arrow) and (B) the ECA after platinum coil embolisation showing the resolution of the MAP and AVF (white arrow).



**Figure 2:** Digital subtraction angiography images of the lateral view of the left external carotid artery of a 24-year-old male patient showing (A) an artefact area (asterisk) representing a gauze pack used for packing the bleeding site and just posterior to it an area of dilatation representing maxillary artery pseudoaneurysm (MAP; white arrow). Previous coiling of direct carotid-cavernous *fistula* on the day of a motor vehicle accident is visible (red arrow). (B) Coil embolisation led to complete resolution of the MAP (white arrow).

under general anaesthesia, was unsuccessful. Subsequently, through a transoral approach, a bilateral coronoidectomy was performed and the condylar necks were exposed in an attempt to reduce the dislocated condyles surgically. Intraoperatively, a sudden episode of massive bleeding was encountered on the right side, which was controlled initially with suture ligation and surgical packing.

The patient was then transferred to the Radiology Department at Khoula Hospital, Muscat, Oman. Digital subtraction angiography (DSA) was promptly performed revealing a large lobulated MAP arising just posterior to the neck of the right condyle with early filling of the jugular vein indicating an arteriovenous *fistula* (AVF) [Figure 1A]. At the same setting, endovascular embolisation was conducted using platinum coils and complete resolution of the MAP and the AVF was achieved [Figure 1B]. The surgical wound was subsequently closed uneventfully.

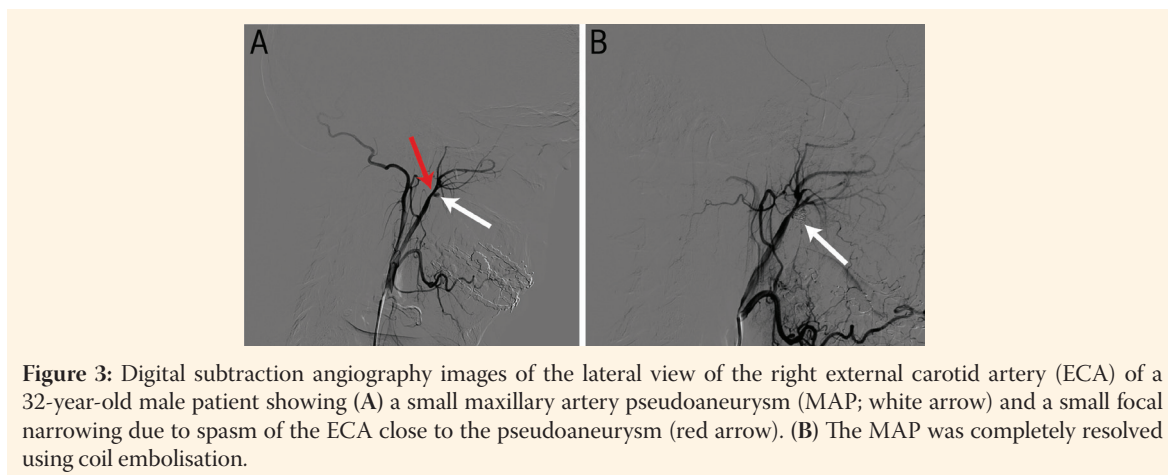
## Case Two

A 24-year-old male patient initially presented at Khoula Hospital in 2015 with a history of MVC, where

he sustained a head injury with a fracture in the base of the skull and cavernous AVF, which was managed by coil embolisation. In 2016, he presented to the Oral & Maxillofacial Surgery Unit at Al-Nahda Hospital with a chief complaint of limited mouth opening. Clinical and CT findings revealed coronoid pseudoankylosis with the base of the skull; subsequently, the patient underwent surgical release of the pseudoankylosis through a transoral approach. During the surgical removal of the left coronoid process a sudden severe haemorrhage was encountered. The bleeding was controlled with surgical packing and the surgery was abandoned. The patient was then transferred to the Radiology Department at Khoula Hospital. An urgent DSA revealed a left MAP and the patient underwent platinum coil embolisation with complete resolution of the lesion [Figure 2]. The surgical packing was removed and the mandibular surgery was completed with no bleeding. Subsequently, the patient's mouth opening improved significantly.

## Case Three

A 32-year-old male patient presented to the Oral &



**Figure 3:** Digital subtraction angiography images of the lateral view of the right external carotid artery (ECA) of a 32-year-old male patient showing (A) a small maxillary artery pseudoaneurysm (MAP; white arrow) and a small focal narrowing due to spasm of the ECA close to the pseudoaneurysm (red arrow). (B) The MAP was completely resolved using coil embolisation.

Maxillofacial Surgery Unit at Al-Nahda Hospital in 2015 with a history of MVC. The patient complained of limited mouth opening and deranged occlusion. Clinical and radiographic examinations revealed a medially displaced right mandibular subcondylar fracture. Subsequently, the patient underwent open reduction and internal fixation of the fracture through a retromandibular approach. During the reduction stage, a sudden episode of massive bleeding was encountered from and around the posterior-superior margin of the mandibular *ramus*. The bleeding was initially controlled with pressure packs and the surgery was abandoned. The patient was then transferred to the Radiology Department at Khoula Hospital where he underwent urgent DSA, which revealed an MAP just inferior to the right condylar head [Figure 3A]. The pseudoaneurysm was successfully embolised with platinum coils [Figure 3B]. Subsequently, the right subcondylar fracture was reduced and fixed through the previous approach uneventfully.

## Discussion

Most of the reported vascular aneurysms in the head and neck region tend to occur intra-cranially; only a small percentage reside in the extra-cranial part of the carotid and vertebral arteries.<sup>11</sup> There is a scarcity of head and neck pseudoaneurysm reports in the literature, with the majority of data based on case reports and case series; this supports the relatively rare occurrence of these lesions.<sup>1-5</sup>

Head and neck pseudoaneurysms have been reported to occur spontaneously or as a complication of surgical or traumatic injuries, chemoradiotherapy, carcinomas, arteriosclerotic disease and infections.<sup>1-10</sup> Mycotic aneurysms caused by infections were the most common form of extra-cranial carotid artery

aneurysms in the past.<sup>9</sup> However, with advances in infection control and antimicrobial therapy, aneurysms caused by infections are uncommon nowadays.<sup>9</sup> Trauma, penetrating or blunt, is currently the most common cause of head and neck pseudoaneurysms, representing nearly half of the reported cases.<sup>12-14</sup> Pseudoaneurysms occurring as a consequence of surgical procedures such as orthognathic, temporomandibular joint (TMJ), dental and ear, nose and throat surgeries have been reported in recent years as iatrogenic causes of maxillofacial pseudoaneurysms.<sup>4-6,10,11,15-18</sup>

Generally, branches of the external carotid artery are well protected from external insults. Nevertheless, some branches are more prone to trauma due to their anatomical location; for example, the superficial temporal artery is vulnerable to both penetrating and blunt trauma due to its superficial location.<sup>15</sup> In addition, facial fractures involving the mandibular condyle may contribute to vascular injury of the maxillary artery due to its close proximity, making it vulnerable to injury by the fracture fragments during the initial trauma or during surgical reduction.<sup>7,18</sup> Orthognathic and TMJ surgeries are the most common procedures performed close to the infra-temporal region, which poses a risk to the maxillary artery; however, vascular injuries during these surgeries are uncommonly reported.<sup>11,14</sup>

Pseudoaneurysms of the external carotid artery, facial and palatine arteries have also been reported in association with maxillofacial trauma or surgeries.<sup>16-18</sup> Given the large volume of maxillofacial trauma, surgical management of facial fractures, orthognathic and TMJ surgeries performed at Al-Nahda and Khoula Hospitals over the past 25 years, only the current three cases of MAP were diagnosed.<sup>19,20</sup> This confirms the relatively rare occurrence of this complication.

The clinical presentation of facial pseudoaneurysms is variable and depends on the location of

the involved vessel; in most cases, these lesions are asymptomatic.<sup>13,14</sup> Clinical signs and symptoms may occur immediately or weeks-to-months following the initial vascular insult.<sup>13,14</sup> Headache, facial and neck pain, pulsatile mass, local nerve compression, vascular thromboembolism and vascular rupture have been reported as clinical features of maxillofacial pseudoaneurysms.<sup>13</sup> Vascular thromboembolism as a complication of pseudoaneurysm has also been clinically reported as monocular blindness, transient ischaemic attack and stroke.<sup>13</sup> Vascular ruptures usually present as brisk bleeding either spontaneously or following an insult.<sup>16–18</sup>

Diagnosis of arterial pseudoaneurysm in the facial region requires careful assessment. Ultrasonography has a limited role in areas obscured by bone and thicker fatty tissues, such as the mandible, where visualisation becomes more difficult and less reliable.<sup>21</sup> Computed tomographic angiography and magnetic resonance angiography are non-invasive and highly defined imaging studies that provide detailed information about the aneurysm. Nowadays, angiography is the gold standard for diagnosis and a minimally invasive modality for treating pseudoaneurysms.<sup>13,19,21</sup>

In the literature, there is no consensus or criteria on vascular pseudoaneurysm repair. Treatment should be tailored for each case depending on the size and location of the lesion and the fitness of the patient. Treatment options include medical management, surgical excision and endovascular embolisation.<sup>6,11–13,22–25</sup> Spontaneous thrombosis of the aneurysmal sac has been reported in literature, yet the frequency and period at which this occurs is unpredictable.<sup>23,25</sup> Lotina *et al.* presented a case series of 12 patients with 13 extra-cranial carotid aneurysms.<sup>23</sup> Intraoperative findings revealed one complete and 11 partial thromboses of the aneurysmal sac and only one case underwent surgical intervention.<sup>23</sup> Other studies have demonstrated that spontaneous thrombosis may occur in up to 89% of vascular pseudoaneurysms in 5–90 days.<sup>24</sup> In contrast, Yi *et al.* reported an increased morbidity, risk of bleeding and other complications in observational cases of pseudoaneurysms.<sup>24</sup> A mortality rate of 70% for non-operated cases of carotid artery aneurysms has been reported.<sup>23</sup> Therefore, due to the unforeseeable nature of these lesions, many experts advocate prompt treatment.<sup>7,12,15</sup> Medical management in terms of antiplatelet and anticoagulant therapies is recommended for small lesions in high-risk patients who are unfit for surgical interventions.<sup>24</sup>

Endovascular embolisation of the facial pseudoaneurysms is superior to surgical treatment as it provides direct access to areas that might be difficult to

access surgically, in addition to the precise localisation and selective occlusion of the lesion.<sup>12,25</sup> Although coils are the most commonly used embolisation material, stents and liquid agents (such as glues and thrombin) have also been used.<sup>25</sup> In the current cases, the minimally invasive endovascular embolisation technique was used utilising platinum coils with no complications and good outcomes.

## Conclusion

Maxillary artery pseudoaneurysm is an unusual complication of maxillofacial trauma. While operating in the area of this artery, a surgeon must maintain a high level of suspicion if an intraoperative brisk or massive bleeding event is encountered. Utilisation of interventional radiology techniques in the management of these lesions can be accomplished with minimal complications.

## References

1. Sclafani AP, Sclafani SJ. Angiography and transcatheter arterial embolization of vascular injuries of the face and neck. *Laryngoscope* 1996; 106:168–73. <https://doi.org/10.1097/00005537-199602000-00012>.
2. Esteller E, León X, de Juan M, Quer M. Delayed carotid blow-out syndrome: A new complication of chemoradiotherapy treatment in pharyngolaryngeal carcinoma. *J Laryngol Otol* 2012; 126:1189–91. <https://doi.org/10.1017/S0022215112001910>.
3. Cheng KY, Lee KW, Chiang FY, Ho KY, Kuo WR. Rupture of radiation-induced internal carotid artery pseudoaneurysm in a patient with nasopharyngeal carcinoma--Spontaneous occlusion of carotid artery due to long-term embolizing performance. *Head Neck* 2008; 30:1132–5. <https://doi.org/10.1002/hed.20753>.
4. Lanigan DT, Hey J, West RA. Hemorrhage following mandibular osteotomies: A report of 21 cases. *J Oral Maxillofac Surg* 1991; 49:713–24. [https://doi.org/10.1016/s0278-2391\(10\)80235-6](https://doi.org/10.1016/s0278-2391(10)80235-6).
5. Lanigan DT, Hey JH, West RA. Major vascular complications of orthognathic surgery: False aneurysms and arteriovenous fistulas following orthognathic surgery. *J Oral Maxillofac Surg* 1991; 49:571–7. [https://doi.org/10.1016/0278-2391\(91\)90337-1](https://doi.org/10.1016/0278-2391(91)90337-1).
6. Elton VJ, Turnbull IW, Foster ME. An overview of the management of pseudoaneurysm of the maxillary artery: A report of a case following mandibular subcondylar osteotomy. *J Craniomaxillofac Surg* 2007; 35:52–6. <https://doi.org/10.1016/j.jcms.2006.11.002>.
7. Yeo MS, Goh TL, Nallathamby V, Cheong EC, Lim TC. Maxillary artery injury associated with subcondylar mandible fractures: A novel treatment algorithm. *Craniomaxillofac Trauma Reconstr* 2012; 5:83–8. <https://doi.org/10.1055/s-0032-1313353>.
8. Kamath G, Naalla R, Pai VB, Narayanan R. Left maxillary artery pseudoaneurysm: A rare and late postoperative complication after head and neck cancer treatment. *BMJ Case Rep* 2014; 13:2014. <https://doi.org/10.1136/bcr-2013-203078>.
9. Dunn GP, Uppaluri R, Hessler JL, Layland MK, Derdeyn CP, Sunwoo JB. Mycotic pseudoaneurysm of the internal maxillary artery: Case report and review of the literature. *Arch Otolaryngol Head Neck Surg* 2007; 133:402–6. <https://doi.org/10.1011/archotol.133.4.402>.



10. Zachariades N, Skoura C, Mezitis M, Marouan S. Pseudoaneurysm after a routine transbuccal approach for bone screw placement. *J Oral Maxillofac Surg* 2000; 58:671–3. [https://doi.org/10.1016/s0278-2391\(00\)90165-4](https://doi.org/10.1016/s0278-2391(00)90165-4).
11. Cameron JL, Cameron AM. *Current Surgical Therapy*. 12th ed. Philadelphia, USA: Elsevier, 2017.
12. Yousuf KM, Khan FH. Pseudoaneurysm of head and neck vessels has been frequently observed in road side bomb blast victims. *Surgeon* 2016; 14:142–6. <https://doi.org/10.1016/j.surge.2014.09.004>.
13. Hong JT, Lee SW, Ihn YK, Son BC, Sung JH, Kim IS, et al. Traumatic pseudoaneurysm of the superficial temporal artery treated by endovascular coil embolization. *Surg Neurol* 2006; 66:86–8. <https://doi.org/10.1016/j.surneu.2005.10.022>.
14. Ribeiro AL, Brasil da Silva W, Alves-Junior Sde M, de Jesus Viana Pinheiro J. Giant life-threatening external carotid artery pseudoaneurysm caused by a mandibular condylar fracture. *Oral Surg Oral Med Oral Pathol Oral Radiol* 2015; 119:e95–100. <https://doi.org/10.1016/j.oooo.2014.08.017>.
15. Silva AC, O’Ryan F, Beckley ML, Young HY, Poor D. Pseudoaneurysm of a branch of the maxillary artery following mandibular sagittal split ramus osteotomy: Case report and review of the literature. *J Oral Maxillofac Surg* 2007; 65:1807–16. <https://doi.org/10.1016/j.joms.2005.12.040>.
16. Madani M, Veznedaroglu E, Pazoki A, Danesh J, Matson SL. Pseudoaneurysm of the facial artery as a late complication of bilateral sagittal split osteotomy and facial trauma. *Oral Surg Oral Med Oral Pathol Oral Radiol Endod* 2010; 110:579–84. <https://doi.org/10.1016/j.tripleo.2010.03.021>.
17. Fernández-Prieto A, García-Raya P, Burgueño M, Muñoz-Caro J, Frutos R. Endovascular treatment of a pseudoaneurysm of the descending palatine artery after orthognathic surgery: Technical note. *Int J Oral Maxillofac Surg* 2005; 34:321–3. <https://doi.org/10.1016/j.ijom.2004.06.007>.
18. Hwang SH, Joo YH, Seo JH, Kang JM. Proximity of the maxillary artery to the mandibular ramus: An anatomic study using three-dimensional reconstruction of computer tomography. *Clin Anat* 2014; 27:691–7. <https://doi.org/10.1002/ca.22329>.
19. Bakathir AA, Margasahayam MV, Al-Ismaily MI. Removal of bone plates in patients with maxillofacial trauma: A retrospective study. *Oral Surg Oral Med Oral Pathol Oral Radiol Endod* 2008; 105:e32–7. <https://doi.org/10.1016/j.tripleo.2008.01.006>.
20. Al-Hashmi AK, Al-Ismaily MI, Goss AN. A comparative study of the etiology of adult mandibular fractures in the Sultanate of Oman and South Australia. *Saudi Med J* 2008; 29:1828–30.
21. Lönn L, Olmarker A, Geterud K, Risberg B. Prospective randomized study comparing ultrasound-guided thrombin injection to compression in the treatment of femoral pseudoaneurysms. *J Endovasc Ther* 2004; 11:570–6. <https://doi.org/10.1583/03-1181.1>.
22. Bouloux GF, Perciaccante VJ. Massive hemorrhage during oral and maxillofacial surgery: Ligation of the external carotid artery or embolization? *J Oral Maxillofac Surg* 2009; 67:1547–51. <https://doi.org/10.1016/j.joms.2009.03.014>.
23. Lotina S, Davidović L, Kostić D, Sternić N, Velimirović D, Stojanov P, et al. [Aneurysms of the carotid arteries]. *Srp Arh Celok Lek* 1997; 125:141–53.
24. Yi AC, Palmer E, Luh GY, Jacobson JB, Smith DC. Endovascular treatment of carotid and vertebral pseudoaneurysms with covered stents. *AJNR Am J Neuroradiol* 2008; 29:983–7. <https://doi.org/10.3174/ajnr.A0946>.
25. Fankhauser GT, Stone WM, Fowl RJ, O’Donnell ME, Bower TC, Meyer FB, et al. Surgical and medical management of extracranial carotid artery aneurysms. *J Vasc Surg* 2015; 61:389–93. <https://doi.org/10.1016/j.jvs.2014.07.092>.