

## Right Atrial Blood Cyst with Stones Suspended from the Coronary Sinus

Feridoun Sabzi,<sup>1</sup> Aghigh Heydari,<sup>1</sup> \*Atefeh Asadmobini,<sup>1</sup> Mohammad B. Heidari<sup>2</sup>

### كيس دم أذيني أيمن به حجارة متدلّية من الجيب التاجي

فريدون سابزي، أغيج حيدري، عطيفة أسدموبيني، محمد باقر حيدري

**ABSTRACT:** Cardiac blood cysts are rare benign neoplasms, usually involving the cardiac valves and are remnants of the Chiari network. They are usually detected in the first six months of life and rarely occur in children or adults. We report a 76-year-old male patient who was referred to the Imam Ali Hospital affiliated with Kermanshah University of Medical Sciences, Kermanshah, Iran, in 2018 with dyspnoea. Transthoracic echocardiography revealed a small patent *foramen ovale* (PFO) and a circumferential mobile cystic mass in the right atrium, with the impression of a tumour or thrombus. The patient underwent open-heart surgery with cardiopulmonary bypass to repair to PFO and remove the intra-atrial lesion. During surgical examination of the right atrial cavity, a blood cyst containing small stone-like structures on the coronary sinus valve of the right atrium was found. The post-operative course was uneventful and no recurrence of tumour was detected during six months of follow-up. To the best of our knowledge, this is the first reported case of a right atrial blood cyst with a few nodule-like stones in an adult with PFO in Iran and the second case in an adult with PFO worldwide.

**Keywords:** Cyst; Coronary Sinus; Adult; Operative Surgical Procedure; Case Report; Iran.

**المخلص:** أكياس دم القلب هي أورام حميدة نادرة وتشمل عادة الصمامات القلبية وهي بقايا من شبكة شياري. عادة ما يتم اكتشافها في الأشهر الستة الأولى من الحياة ونادراً ما تظهر في الأطفال أو البالغين. نعرض هنا حالة لمريض يبلغ من العمر 76 عاماً والذي تم إحالته إلى مستشفى الإمام علي التابع لجامعة كرمانشاه للعلوم الطبية، كرمانشاه، إيران، في عام 2018 بسبب ضيق التنفس. كشف تخطيط صدى القلب عبر الصدر عن وجود ثقب بيضاوي كامن صغير وكتلة كيسية كغافية متحركة في الأذين الأيمن تعطي انطباع عن وجود ورم أو تجلط. خضع المريض لجراحة قلب مفتوح مع مجرى تجاوز قلبي رئوي لإصلاح الثقب البيضاوي الكامن وإزالة الآفة داخل الأذين. أثناء الفحص الجراحي للتجويف الأذيني الأيمن تم العثور على كيس دم على صمام الجيب التاجي في الأذين الأيمن يحتوي على هيكل صغيرة تشبه الحجارة. كانت المسار بعد العملية الجراحية بلا مضاعفات ولم يتم اكتشاف أي تكرار للورم خلال الستة أشهر من المتابعة بعد العملية. على حد علمنا هذه هي أول حالة يتم الإبلاغ فيها عن وجود كيس دم أذيني أيمن يحتوي على بعض الحجارة التي تشبه العقيدات في شخص بالغ لديه ثقب بيضاوي كامن في إيران والحالة الثانية لدى شخص بالغ مصاب بثقب بيضاوي كامن حول العالم.

**الكلمات المفتاحية:** كيس؛ جيب تاجي؛ بالغ؛ عملية جراحية؛ تقرير حالة؛ إيران.

**B**LOOD CYST OF THE RIGHT ATRIUM WITH A connecting stalk to the coronary sinus valve is a lesion that rarely occurs in adults.<sup>1</sup> These cysts are remnants of the Chiari network (CAN) which comprises of fine *trabeculae* of fibrous tissue floating along the direction of blood flow to the tricuspid valve (TV).<sup>2</sup> The congenital aberrant regression of the primitive embryological network's plate leads to the formation of a *diverticulum* with an internal wall lined with cobblestone-like epithelium and an outer layer covered with fibrous tissue.<sup>3,4</sup>

These unusual cysts are filled with venous and non-coagulable blood and may partially occlude the orifice of the TV or inferior *vena cava* (IVC). However, they are benign lesions and in asymptomatic cases should be left untreated, yet pre-operative differential diagnosis from other similar cystic lesions is difficult. The presence of intra-cystic homogeneous echo density

with the absence of a calcified rim in the external wall, strongly justifies the presence of a blood cyst. If clear pre-operative delineation from other masses is not possible by imaging modalities and symptoms arise, the cyst should be resected.

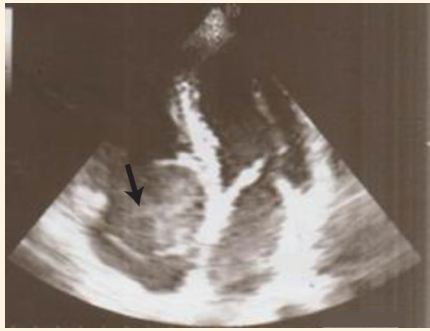This report describes a large mobile right atrial blood cyst reported in a patient with dyspnoea and patent *foramen ovale* (PFO) based on the results of transthoracic echocardiography (TTE).

### Case Report

A 76-year-old male patient was referred to the Imam Ali Hospital affiliated with the Kermanshah University of Medical Sciences, Kermanshah, Iran, in 2018 with dyspnoea that had persisted for two weeks. He had no history of coronary artery disease, chest pain or hypertension. Physical examination was normal with

<sup>1</sup>Cardiovascular Research Center and <sup>2</sup>Department of Surgery, Kermanshah University of Medical Sciences, Kermanshah, Iran

\*Corresponding Author's e-mail: a.asadmobini@gmail.com



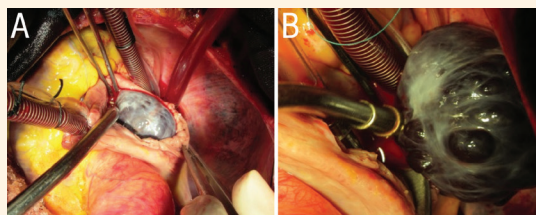
**Figure 1:** Transthoracic echocardiogram of the heart of a 76-year-old male patient showing a cystic mass in the right atrium (arrow).

no heart murmurs or other abnormal finding such as tachycardia or tachypnoea. Routine laboratory tests and thrombophilia screening were normal.

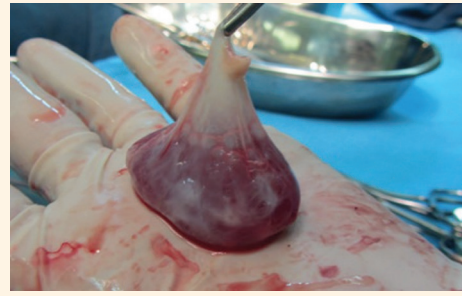Electrocardiogram results showed an irregular rhythm due to premature atrial contraction without any evidence of right or left bundle branch block. The patient's chest X-ray was normal. Subsequently, a TTE was performed for further delineation of dyspnoea and possible left ventricular dysfunction or valve abnormalities. TTE revealed a small PFO and a large mobile cystic mass connected to the atrial side of the coronary sinus valve with a short stalk prolapsing into the TV and the right ventricular cavity during each diastolic phase [Figure 1]. In addition, transoesophageal echocardiography (TOE) showed no evidence of tricuspid malfunction or right ventricular inflow occlusion caused by this large mass.

Left ventricular ejection fraction was normal. The cystic lesion was well demarcated from the right atrial cavity with a distinct, circumferential border, a thin homogenous wall and an echo-lucent internal cavity. However, some echo-density points were detected and attributed to intra-cystic calcifications. The coronary angiogram was normal. Based on the TOE findings, a circumferential thrombus, hydatid cyst or *myxoma* were included in the differential diagnoses.

As a result, the patient underwent open-heart surgery with cardiopulmonary bypass for removal of the intra-atrial lesion and repair of the PFO. After infusion of cardioplegia and incision of the right



**Figure 2:** Intraoperative photographs of an open-heart surgery of a 76-year-old male patient showing a black blood filled cystic mass.



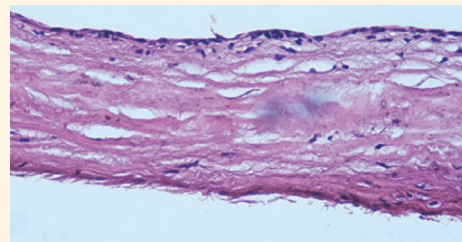
**Figure 3:** Photograph of the surgically removed blood cyst from the right atrium of a 76-year-old male patient showing gross pathology of a cyst filled with saline.

atrium, a black blood filled cystic mass was found. The cystic mass with its short stalk was connected to the coronary sinus valve [Figure 2]. The stalk of mass was excavated from its base by removal of the sub-endocardial layer [Figure 3]. In addition, the PFO was closed using prolene sutures. The patient was weaned from cardiopulmonary bypass and had an uneventful course. Histological examination revealed a blood cyst with internal cobblestone-like endothelium [Figure 4]. The stone-like nodules were not evaluated by a pathologist.

## Discussion

Anomalies of the CAN have been detected in necropsy examinations in 1.3–4% of the total population.<sup>5</sup> It is an aberrant embryologic anomaly produced by incomplete regression of the remnants of the primitive *sinus venosus* valve. The CAN originates from the eustachian valve of the IVC continuing in the direction of the superior *vena cava* (SVC) valve.<sup>6</sup> It has been previously reported that this network is rarely associated with thromboemboli or thrombus formation. CAN usually has a specific shape with many fenestrations in its wall; however, it can also present in a cystic or cord-like shape or a *diverticulum*.<sup>7,8</sup>

Hans Chiari was the first author who described a case series of patients with a fenestrated IVC valve connected superiorly to the SVC valve by a cord-like fibrotic stalk.<sup>9</sup> Although some studies have reported blood cysts of the right atrium, no study has yet



**Figure 4:** Haematoxylin and eosin at x10 magnification showing a thin epithelial layer with internal cobblestone-like endothelium of the surgically excised blood cyst.

reported a blood cyst with a coronary sinus valve origin, as is in the current case.<sup>10–12</sup> In the normal embryologic process, the *sinus venosus* valve completely disappears by the 15<sup>th</sup> gestational week, while in aberrant congenital processes, some parts of the IVC and SVC valves are not regressed by the 100<sup>th</sup> day of gestational age. This aberrant congenital process leads to the presence of remnants of the valve after the 15<sup>th</sup> gestational week, when IVC and SVC are separated completely from one another. Therefore, this network that existed between two structures is stretched and ruptured to form various shapes and contours. There is possibly an important relationship between the presence of autism spectrum disorder, PFO and CAN. In the 15<sup>th</sup> week of the embryologic period, almost all interatrial septal defects have been closed; the presence of an Ebstein anomaly is usually concomitant with the CAN.<sup>13</sup> The increased rate of right-to-left shunt in the current patient is related to many factors, such as low compliance of the right ventricle caused by chronic obstructive pulmonary disease or aging, stretching of the PFO due to the mass and the increased right atrial pressure caused by the presence of the tumour. The presence of a right atrial aneurysm is another common associated anomaly in CAN and has been reported in 21% of subjects.<sup>13</sup> Rare CAN complications include atrial fibrillation (AF), endocarditis and its role as a barrier to implantation of a pacemaker.<sup>9,14</sup> The pre-operative diagnosis of rare CAN with blood cyst is usually difficult and can be incorrectly diagnosed as thrombus, *myxoma* or hydatid cyst.<sup>15</sup> In the present case, the subject was found to have AF and PFO with no evidence of thrombus or atrial aneurysm. The right atrial lesion with a free floating thrombus, hydatid cyst or *myxoma* were the differential diagnoses as TTE findings revealed a thin wall cystic mass without the presence of calcification in the mass's core. According to the angiography results, the right coronary artery did not show tumour blush. Histologic examination determined that the lesion was a blood cyst with CAN origin. Although a blood cystic lesion has been reported previously in one case, the current case had two unique characteristics: (1) the cyst originated from the coronary sinus valve; and (2) few stone-like structures were found in the cyst sack.<sup>1</sup>

## Conclusion

A rare case of a large blood cyst of the coronary sinus valve was reported in a patient with a PFO defect and AF. To the best of the authors' knowledge, this is the second reported case of a blood cyst in an adult patient with PFO; although this case has the unique characteristic of a cyst originating from the coronary

sinus valve. Blood cysts should be considered in the differential diagnosis of atrial cystic lesions detected during echocardiography.

## References

- Bae CH, Kwon OC, Lee S, Lee CH, Cho JW. Cystic mass on right atrium of unusual form of Chiari's network: A case report. *Korean J Thorac Cardiovasc Surg* 2012; 45:254–6. <https://doi.org/10.5090/kjtc.2012.45.4.254>.
- Kim MJ, Jung HO. Anatomic variants mimicking pathology on echocardiography: Differential diagnosis. *J Cardiovasc Ultrasound* 2013; 21:103–12. <https://doi.org/10.4250/jcu.2013.21.3.103>.
- Bendadi F, van Tijn DA, Pistorius L, Freund MW. Chiari's network as a cause of fetal and neonatal pathology. *Pediatr Cardiol* 2012; 33:188–91. <https://doi.org/10.1007/s00246-011-0114-6>.
- Erdogan SB, Akansel S, Sargin M, Mete MET, Arslanhan G, Aka SA. A case of a large Chiari network mimicking a right atrial thrombus. *North Clin Istanb* 2017; 4:270–2. <https://doi.org/10.14744/nci.2017.76094>.
- Schwimmer-Okike N, Niebuhr J, Schramek GG, Frantz S, Kielstein H. The presence of a large Chiari network in a patient with atrial fibrillation and stroke. *Case Rep Cardiol* 2016; 2016:4839315. <https://doi.org/10.1155/2016/4839315>.
- Shivadeep S, Anandaraja S, Devi Jansirani D. Chiari network: An embryological remnant - A case report and review. *Int J Clin Cardiol* 2015; 2:3. <https://doi.org/10.23937/2378-2951/1410038>.
- Pellet AA. The Chiari network in an echocardiography student. *Echocardiography* 2004; 21:91–3. <https://doi.org/10.1111/j.0742-2822.2004.03069.x>.
- Jansirani DD, Deep SS, Anandaraja S. Anatomical study of Chiari network and the remnant of left venous valve in the interior of right atrium. *Anat Res Int* 2015; 2015:247680. <https://doi.org/10.1155/2015/247680>.
- Islam AK, Sayami LA, Zaman S. Chiari network: A case report and brief overview. *J Saudi Heart Assoc* 2013; 25:225–9. <https://doi.org/10.1016/j.jsha.2012.12.002>.
- Centella T, Moya JL, Muñoz M, Reguero EM. Images in cardiovascular medicine. Giant endocardial blood cyst in the right atrium: Echocardiographic and magnetic resonance imaging features. *Circulation* 2008; 117:3250–1. <https://doi.org/10.1161/CIRCULATIONAHA.107.734814>.
- Otsuka K, Terasaki F, Iimori A, Tonari S, Shimomura H, Ito T, et al. Right atrial blood cyst with total occlusion of the right coronary artery. *Heart Vessels* 2007; 22:208–10. <https://doi.org/10.1007/s00380-006-0972-7>.
- Otsuka H, Arinaga K, Fukuda T, Takaseya T, Shojima T, Takagi K, et al. Double right atrial blood cysts. *Ann Thorac Surg* 2016; 101:e147–9. <https://doi.org/10.1016/j.athoracsur.2015.10.021>.
- Loukas M, Sullivan A, Tubbs RS, Weinhaus AJ, Derderian T, Hanna M. Chiari's network: Review of the literature. *Surg Radiol Anat* 2010; 32:895–901. <https://doi.org/10.1007/s00276-010-0639-z>.
- Alegria-Barrero E, Alegria-Barrero A, Gavira Gómez JJ, Rábago Juan-Aracil G. Chiari's network and paroxysmal atrial fibrillation. *Rev Esp Cardiol* 2011; 64:727–8. <https://doi.org/10.1016/j.recesp.2010.11.003>.
- Michelena HI, Mulvagh SL, Schaff HV, Enriquez-Sarano ML, Klarich KW. A heart-shaped mass inside a heart: Echocardiographic diagnosis, pathology, and surgical repair of a flail tricuspid valve caused by a large blood-filled cyst. *J Am Soc Echocardiogr* 2007; 20:771.e3–6. <https://doi.org/10.1016/j.echo.2006.11.019>.