

# Sclerosing Mucoepidermoid Carcinoma

## A unique case

Keshava Bhat, \*Bhavna Pandey, Pushparaja Shetty, Vidya Manohar, Shruthilaxmi M. K., Madhika Patidar

## سرطان مخاطي بشروي متصلب حالة فريدة

كيشافا بات، بافنا باندي، بشباراجا شيتي، فيديا مانور، شرثيلاكشمي، مدهفيكا فاتيدار

**ABSTRACT:** Sclerosing mucoepidermoid carcinoma is an unusual type of mucoepidermoid carcinoma with special histological features which differ from those of the classic type of mucoepidermoid carcinoma. We report the case of a 32-year-old male, who reported to the Vydehi Institute of Dental Sciences, Bangalore, India, with an asymptomatic swelling over the right parotid region which had been present for the previous two and a half years. Histopathological sections of the tumour mass showed mucous and epidermoid cell nests in a dense, hyalinised, sclerotic stroma. A diagnosis of sclerosing mucoepidermoid carcinoma was made. A superficial parotidectomy was performed on the patient and he has remained disease free to date.

**Keywords:** Mucoepidermoid Carcinoma; Salivary Gland Neoplasms; Case Report; India.

**المخلص:** يعتبر السرطان المخاطي البشروي المتصلب من الأنواع غير الاعتيادية من السرطانات المخاطية البشروية مع وجود ملامح هستولوجية خاصة تفرقها عن الأنواع المعهودة من السرطانات المخاطية البشروية. نعرض هنا تقريراً لحالة ذكر عمره 32 عاماً، والذي عرض نفسه لمركز فيدهي لعلوم طب الأسنان في بنجلور بالهند، بشكوى لتورم عديم الأعراض في المنطقة اليمنى للغدة النكفية، والذي كان موجوداً منذ سنتين ونصف. مقاطع من مرضيات الأنسجة لكتلة التورم أظهرت وجود أعشاش لخلايا مخاطية وبشرانية ضمن تزجج كثيف من السدوية المتصلبة. تم إجراء استئصال سطحي للغدة النكفية للمريض مع خلو المريض من المرض حتى اليوم.

**كلمات البحث:** سرطان؛ مخاطي بشروي؛ متصلب؛ أورام الغدد اللعابية؛ تقرير حالة؛ الهند.

**T**HE MUCOEPIDERMOID CARCINOMA (MEC) was originally described by Volkmann in 1895. MEC has since emerged in most series as the most commonly diagnosed primary malignancy of the major salivary glands. Histologically, MEC is composed of various combinations of epidermoid, mucous and intermediate cells; the latter cell is presumed to be the precursor of the former. MEC occasionally displays morphological variations with a minimum or complete absence of more typical morphological features. The presence of clear cells, a focal spindle-cell pattern, sebaceous-like differentiation, areas mimicking thyroid follicles, a predominantly oncocyctic appearance and an intense sclerosing pattern may complicate the diagnosis.<sup>1-4</sup>

What distinguishes the sclerosing variant of a MEC from the other variants is a dense, hyalinised, sclerotic tumour stroma that surrounds, compresses and sometimes even obliterates the nests of tumour cells. Since not many cases have been reported, its behaviour is yet to be determined. The sclerosis associated with these tumours may overshadow

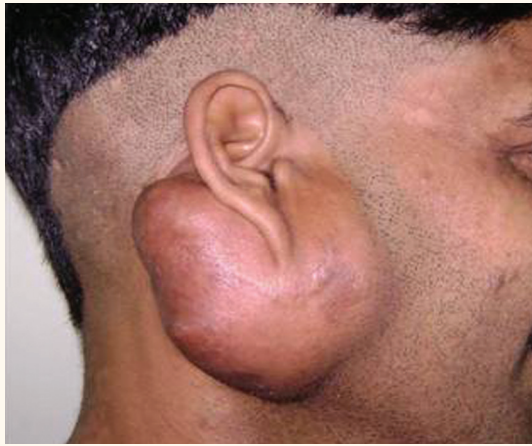the typical histopathological features and result in diagnostic confusion.<sup>2,5</sup>

We report the case of a sclerosing mucoepidermoid carcinoma (SMEC) that was diagnosed in a 32-year-old male and include a brief review of the literature.

## Case Report

A male patient aged 32 years reported to a private hospital with the chief complaint of an asymptomatic swelling over the right parotid region for the previous 2 years and 6 months. On clinical examination, a multilobulated swelling of the right parotid region was noted; it measured approximately 6 x 8 cm with a slight erythema of the overlying skin. The swelling also caused a lifting of the ear lobe [Figure 1]. Palpation of the swelling showed that it was firm in consistency with fixity to the deeper tissues. No lymphadenopathy was present on clinical examination and the facial nerve function was not altered. The results of routine blood tests were within normal limits.

The investigations performed prior to an incisional



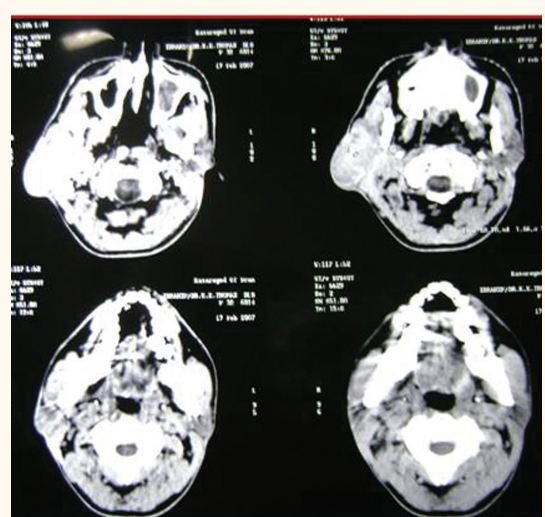
**Figure 1:** Multilobulated swelling of the right parotid region with slight erythema of the overlying skin.

biopsy included fine needle aspiration cytology (FNAC) and a computed tomography (CT) scan. The FNAC findings were inconclusive due to the paucity of cells. The CT scan revealed a well-defined soft-tissue density lesion [Figure 2]. A provisional diagnosis of a benign salivary gland tumour was considered due to the lack of adenopathy, a lack of nerve dysfunction, the CT findings and the duration of the tumour mass.

An incisional biopsy of the tumour was performed under local anaesthesia. This procedure was done prior to surgery to provide an accurate histological diagnosis. Gross examination revealed a specimen measuring around 4.5 x 3.0 x 2.5 cm, grayish-white in colour and of a very firm consistency.

The histopathological haematoxylin and eosin stained sections revealed a tumour mass consisting of mucous and epidermoid cells forming microcysts in a dense fibrinous stroma. The mucous cells were large, pale, columnar to polygonal in shape and seen to be lining the cystic areas. Epidermoid cells were formed solid masses in a few other areas. Several darkly-stained intermediate cells were also seen. Throughout the tumour mass connective tissue stroma was noted which consisted of dense hyalinised fibrous tissue made up of thick collagen fibres encircling the cellular nests and islands with scant inflammatory infiltrate [Figure 3]. A diagnosis of SMEC was made.

Following an incisional biopsy, a superficial parotidectomy was performed on the patient under general anaesthesia in consideration of the lack of facial nerve involvement and the absence of both fixity and lymphadenopathy. The tumour was completely excised with negative margins. A modified Blair incision was used to raise the skin flap covering the gland at face-lift level, i.e. in the layer of fat between the skin and the gland beyond the apparent margin of the tumour. The facial nerve was identified at the

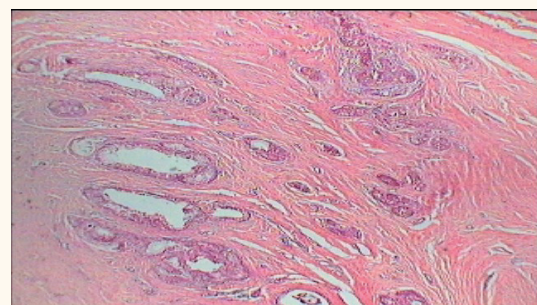


**Figure 2:** Computed tomography scans showing a well-defined soft tissue density lesion.

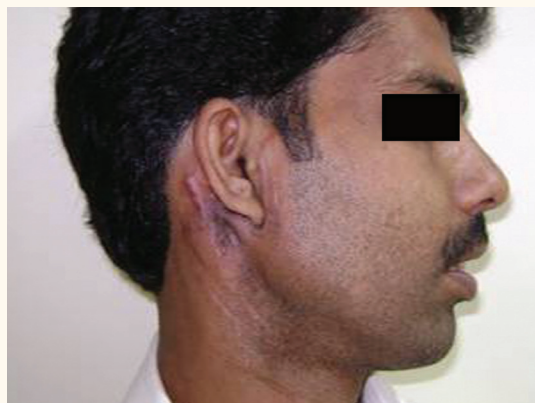proximal end as it emerged from the stylomastoid foramen before entering the substance of the gland. All the salivary tissue superficial to the facial nerve was removed and the skin flap was closed in layers. The patient continues to be on routine six-month follow-up and has remained disease free to date [Figure 4]. The facial nerve function has remained unaffected.

## Discussion

SMEC was first reported in 1987 by Chan and Saw, who described a case of parotid involvement.<sup>6</sup> The distinctive feature of the SMEC is an extreme sclerotic stroma that is present in the tumour mass. The sclerosis associated with these tumours may be so intense that it can confuse even experienced pathologists. Extensive desmoplastic stroma is observed in many salivary gland tumours like the pleomorphic adenoma and the carcinoma ex-pleomorphic adenoma, but is not commonly seen in the MEC. It is also seen in inflammatory salivary gland disease such as chronic



**Figure 3:** Scanner view of cellular nests and islands surrounded by dense hyalinised connective tissue stroma (haematoxylin and eosin stained sections, x 40 magnification).



**Figure 4:** Post-surgical photograph of the patient.

sclerosing sialadenitis.<sup>2,5</sup> The possible pathogenetic mechanisms causing this type of sclerosis are tumour infarction and mucin extravasation.<sup>5</sup> The mucin acts as a foreign material, resulting in fibrosis that forms as an attempt to wall-off the mucin.

As seen in this case, a SMEC represents a potential diagnostic pitfall on FNAC samples due to the intense sclerosis and low cellularity; the FNAC can therefore often prove to be inconclusive. Histologically, the sclerosing variant of the MEC is characterised by some exclusive features: areas of dense sclerosis (almost resembling that of a keloid) with distributed solid or cystic nests of mucoepidermoid tumour cells. In 1990, Batsakis and Luna mentioned stromal desmoplasia as a feature of high-grade MECs.<sup>7</sup>

According to Fadare *et al.*, the sclerosing morphological variant of this tumour is extremely rare, with only six reported cases. Out of these, two showed metastasis but this could have been because of their larger tumour size rather than the sclerotic stroma.<sup>5</sup> Analyses with larger number of cases are required to evaluate whether the sclerosis appears as a self-determining prognostic factor. Comparing the tumours reported in the past, most of them have been put into the low-grade category; they were observed with a few mitotic figures and minimal anaplasia.<sup>5</sup>

Perineural invasion, another factor that determines prognosis of salivary gland tumours, is generally absent in these sclerotic tumours. It was reported in only three of the previous cases.<sup>5-14</sup> Negative prognostic factors included the high grade of the tumour, increasing patient age, tumour size, extraparenchymal extension, nodal metastases and distant metastases.<sup>15,16</sup>

The histological differential diagnoses of salivary gland SMEC include sclerosing polycystic adenosis, chronic sclerosing sialadenitis, low-grade cystadenocarcinoma and necrotising sialometaplasia.<sup>10,11,15-17</sup>

The treatment recommended for these cases is

total surgical excision with marginal resection. The facial nerve should be preserved if it is not involved. If complete marginal resection is not possible, postoperative radiation therapy is recommended to prevent tumour spread, recurrence and distant disease. Patients should be routinely investigated with magnetic resonance and CT imaging studies of the tumour, with thorough evaluation of the regional lymph nodes, to ensure there is no recurrence or metastasis.<sup>10</sup>

## Conclusion

The present case of SMEC that was diagnosed in a 32-year-old male was found to have unique histological features, causing its recognition and diagnosis to be challenging. Moreover, in view of both its distinctive pathology and its rarity, no clear treatment strategy has been formulated. It was treated by superficial parotidectomy. The patient is on long-term review, having undergone clinical and ultrasonographic evaluation for the past six years and the prognosis has so far been favourable.

## References

1. Ellis GL, Auclair PL, Gnepp DR. Mucoepidermoid carcinoma. In: Mitchell J, Ed. Surgical Pathology of the Salivary Glands. Major Problems in Pathology Series. Vol. 25. Philadelphia: W. B. Saunders Co., 1991. Pp. 269–95.
2. Rajendran R, Sivapathasundharam B. Tumors of the salivary glands. In: Rajendran R, Sivapathasundharam B, Eds. Shafer's Textbook of Oral Pathology. 6th ed. New Delhi: Elsevier Health Sciences, Indian Reprint, 2009. Pp. 235–6.
3. Neville BW. Salivary Gland Tumors. In: Neville BW, Damm DD, Allen CM, Bouquot JE, Eds. Oral & Maxillofacial Pathology. 3rd ed. Philadelphia: Saunders/Elsevier, Indian Reprint, 2009. Pp. 487–90.
4. Regezi JA, Sciubba JJ, Jordan CKR. Salivary Gland diseases. In: Regezi JA, Sciubba JJ, Jordan CKR, Eds. Oral Pathology, Clinical Pathologic Correlations. 5th ed. Philadelphia: Saunders/Elsevier. Indian Reprint, 2009. Pp. 203–4.
5. Fadare O, Hileeto D, Gruddin YL, Mariappan MR. Sclerosing mucoepidermoid carcinoma of the parotid gland. Arch Pathol Lab Med 2004; 128:1046–9.
6. Chan JK, Saw D. Sclerosing mucoepidermoid tumour of the parotid gland: Report of a case. Histopathology 1987; 11:203–7.
7. Batsakis JG, Luna MA. Histopathologic grading of salivary gland neoplasms: I. Mucoepidermoid carcinomas. Ann Otol Rhinol Laryngol 1990; 99:835–8.
8. Hamper K, Schimmelpenninck H, Caselitz J, Arps H, Berger J, Askensten U, et al. Mucoepidermoid tumors of the salivary glands. Correlation of the cytophotometrical data and prognosis. Cancer 1989; 63:708–17.
9. Muller S, Barnes L, Goodurn WJ Jr. Sclerosing mucoepidermoid carcinoma of the parotid. Oral Surg Oral Med Oral Pathol Oral Radiol Endod 1997; 83:685–90.
10. Sinha SK, Keogh IJ, Russell JD, O'Keane JC. Sclerosing mucoepidermoid carcinoma of minor salivary glands: A case report [letter]. Histopathology 1999; 35:283–4.

11. Urano M, Abe M, Horibe Y, Kuroda M, Mizoguchi Y, Sakurai K, et al. Sclerosing mucoepidermoid carcinoma with eosinophilia of the salivary glands. *Pathol Res Pract* 2002; 198:305–10.
12. Heavner SB, Shah RB, Moyer JS. Sclerosing mucoepidermoid carcinoma of the parotid gland. *Eur Arch Otorhinolaryngol* 2006; 263:955–9.
13. Veras EF, Sturgis E, Luna MA. Sclerosing mucoepidermoid carcinoma of the salivary glands. *Ann Diagn Pathol* 2007; 11:407–12.
14. Aguiar MC, Bernardes VE, Cardoso SV, Barbosa AA, Mesquita RA, Carmo MA. A rare case of sclerosing mucoepidermoid carcinoma arising in minor salivary glands with immunohistochemical evaluation. *Minerva Stomatol* 2008; 57:453–7.
15. Mendelson AA, al-Macki K, Chauvin P, Kost KM. Sclerosing mucoepidermoid carcinoma of the salivary gland: Case report and literature review. *Ear Nose Throat J* 2010; 89:600–3.
16. Chen MM, Roman SA, Sosa JA, Judson BL. Histologic grade as prognostic indicator for mucoepidermoid carcinoma: A population-level analysis of 2400 patients. *Head Neck* 2013; 36:158–63. doi: 10.1002/hed.23256.
17. Shinhar SY. Sclerosing mucoepidermoid carcinoma of the parotid gland: case report. *Ear Nose Throat J* 2009; 88:E29–31.