

Weak Radial Artery Pulse

An unusual congenital cause

*Poothirikovil Venugopalan,¹ Puthuval Sivakumar,² Robert G. Ardley,³ Crispian Oates⁴

النبض الضعيف في الشريان الكعبري سبب خلقي غير عادي

بوثيريكوفيل فينوجوبالان، بوثوفال سيفاكومار، روبرت اردلي، كريسيان أوتس

المخلص: نُقدّم هنا حالة طفل عُمره 11 عاماً لديه ضعف النبض في الشريان الكعبري الأيمن، ونُصف التطبيق الناجح للموجات فوق الصوتية للأوعية الدموية لتحديد هيمنة الشريان الزندي ورقّة الشريان الكعبري الأيمن مع سرعة تدفق دوبلر الأدنى من الطبيعي والتي يمكن أن تُفسر هذا التناقض. نناقش أيضاً الآثار المترتبة على تحديد هذا الوضع الشاذ.

مفتاح الكلمات: شريان كعبري، نبض، شذوذ، التصوير بالموجات فوق الصوتية، تقرير حالة، المملكة المتحدة.

ABSTRACT: We present an 11-year-old boy with a weak right radial pulse, and describe the successful application of vascular ultrasound to identify the ulnar artery dominance and a thin right radial artery with below normal Doppler flow velocity that could explain the discrepancy. The implications of identifying this anomaly are discussed.

Keywords: Arterial anomalies; Pulse, radial; Congenital; Embryology; Ultrasonography; Catheterization; Case Report; UK.

DISCREPANCIES IN PALPABLE PULSES are not uncommon in children, and could cause concern for the patient and parents, as well as physicians. When these are detected in an otherwise well child, a dilemma exists as to how extensive the medical investigation should be. We report the interesting case of a boy with a weak radial pulse which was detected during a routine follow-up visit to a paediatric clinic. This case emphasises the clinical importance in terms of knowing about unusual but normal variations in palpable pulses.

Case Report

AB, an 11-year old boy, was on follow up for hypokalaemic periodic paralysis. During one of the clinic visits, he was noted to have a weak radial pulse on the right side, and this prompted further investigation. There was no asymmetry in the limb size and there was no evidence of hypo-perfusion of the right arm or hand. Other pulses were normally

felt, including both femoral and left radial pulses. His cardiovascular system was essentially normal and there was no cardiac murmur. AB had not had any previous cardiac surgery, or intensive care admission in early infancy or during neonatal life.

A vascular ultrasound scan of the arteries in the upper arms showed a number of features that explained the discrepancy in the pulses felt on each arm. On both sides, the radial artery was smaller than the ulnar artery, and the ulnar arteries provided the main source of blood flow to the arms (ulnar dominance).

On the left side, the radial artery arose from the brachial artery at its upper end, well above the elbow, and then crossed over to the radial side of the forearm at the elbow [Figure 1]. On the right side, the radial artery arose from the medial side of the brachial artery near the elbow and then looped across the distal end of the brachial artery to continue along the radial margin of the forearm. The loop was a very thin vessel, and continued to be thin in several places, especially at the wrist.

¹Department of Child Health, Brighton & Sussex University Hospitals, Brighton, UK; Departments of ²Child Health and ³Medical Physics University Hospital of Hartlepool, Hartlepool, UK; ³Regional Medical Physics Department, Freeman Hospital, Newcastle-upon-Tyne, UK.

Corresponding Author e-mail: pvenugopalan@gmail.com

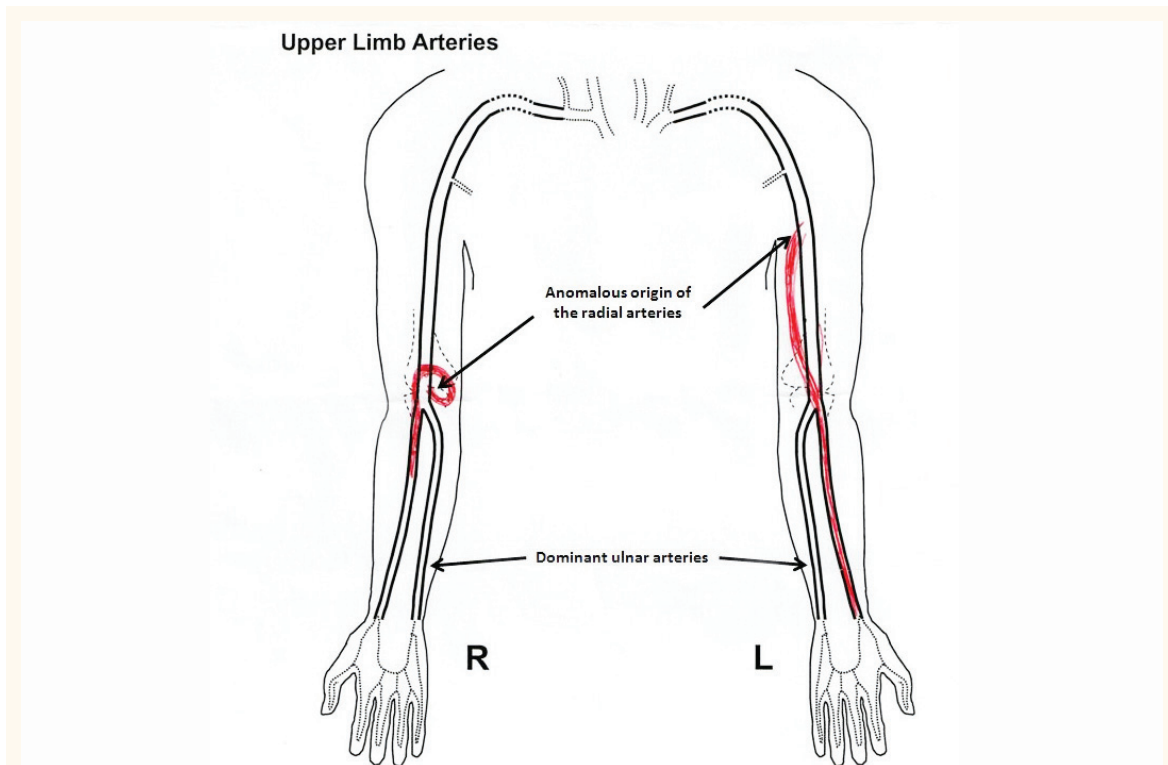


Figure 1: Diagrammatic representation of upper limb arteries in an 11 year-old boy showing the radial artery anomalies detected by vascular ultrasound (R = right; L = left). The diagram is not drawn to scale and hence does not depict the smallness of the radial arteries, but does show the abnormal origins (arrows).

Pulse-wave Doppler signals showed normal flow velocity (30–50 cm/sec) along the ulnar arteries [Figure 2]. The flow along the radial arteries was pulsatile, but with a below normal velocity, and more pronounced in the right radial artery (right 15 cm/sec; left 28 cm/sec). These variations explained the weak right radial pulse.

We discussed with the family the role of magnetic resonance imaging (MRI) to confirm the anomaly, but both the parents and the child were not happy to undergo any further tests.

Discussion

Congenital arterial anomalies of upper limbs have been reported in the literature, but each has its own thumbprint. Upper limb abnormalities are sometimes encountered during transradial coronary procedures. Such anomalies may contribute to procedure failure, or to vascular complications, and they may be a major reason to find alternative routes.

Arterial supply to the forearm and hand is by the radial and ulnar arteries. Both are branches of the brachial artery, arising within or just distal

to the cubital fossa from the bifurcation of the brachial artery. The radial artery is normally the dominant arterial supply to the hand.¹ Deviations from normal anatomy are not infrequent, occurring in 18.5% of 386 cadavers studied by McCormack *et al.*² Unilateral abnormalities were more common than bilateral (24.5% and 6.3%, respectively). Similar findings have also been reported by Fujii *et al.* and Ziakas *et al.*^{3,4} Rodriguez-Baeza *et al.* have proposed 4 groups of anomalies: isolated persistence of the median artery; high origin of the ulnar artery; high origin of the radial artery, and duplication of the brachial artery, either with or without anastomosis at the cubital fossa.⁵ The most common anomaly is a high origin of the radial artery, either from the brachial or axillary artery, and has been shown in 14.27% of cadaveric samples and 9.75% in angiographic examinations.⁶ The majority of reported cases have a symmetrical distribution of the anomaly.

The present case describes abnormal origins of radial arteries on both sides; however, the nature of the anomaly was different on each side. On the left side, the radial artery was proximal in its origin, and arose from the medial margin of the upper third of

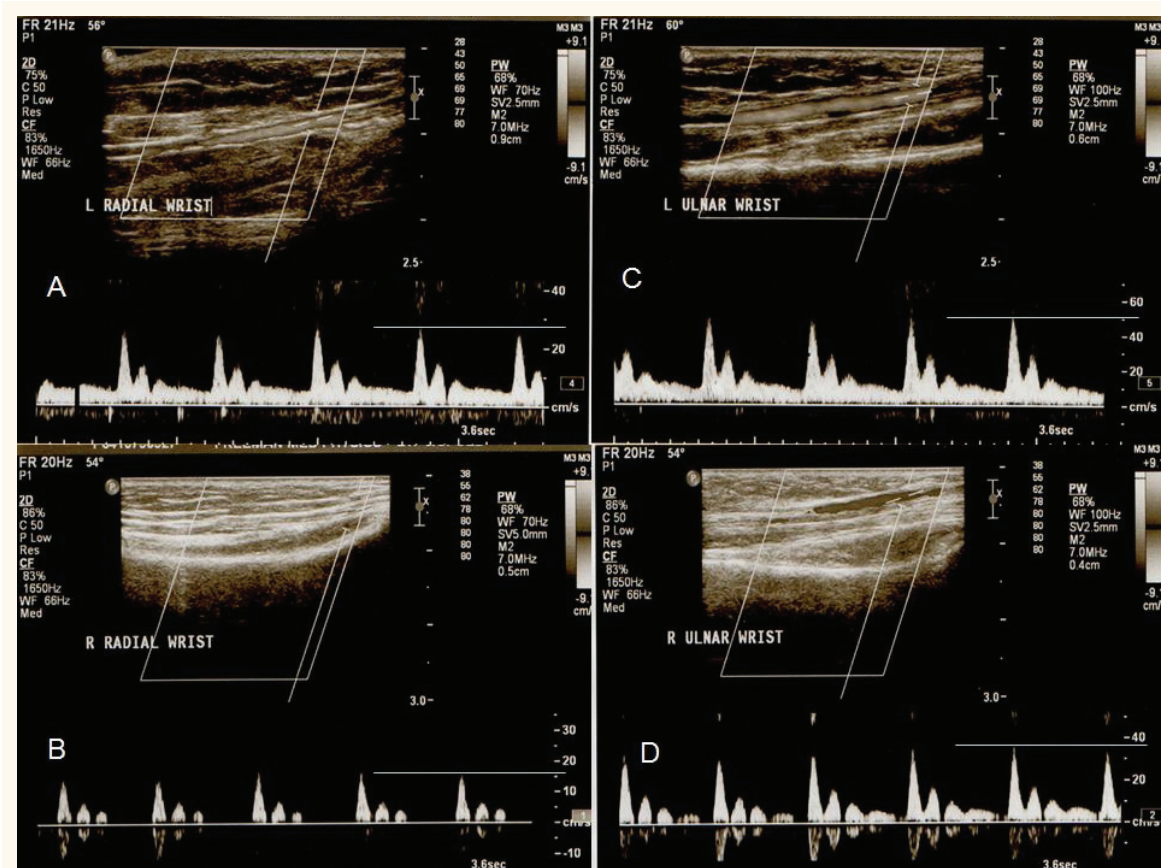


Figure 2: Pulse wave Doppler pictures of arterial blood flow at the wrist in an 11 year-old boy showing reduced Doppler flow velocity in the radial arteries compared to the ulnar arteries (Left radial artery [A] 28 cm/sec; Right radial artery [B] 15 cm/sec; Left ulnar artery [C] 50 cm/sec; Right ulnar artery [D] 38 cm/sec).

the brachial artery. This is a common variant seen in 5-10% of the population; however, the anomaly is usually seen symmetrically on both sides. In AB, the radial artery on the right side originated from the medial margin of the brachial artery, within the cubital fossa, and looped across the distal end of brachial artery, which is quite unusual. Moreover, the right radial artery was thin and hypoplastic with a lower flow velocity, giving rise to a weak radial pulse on the right side. This pattern of malformation is very unusual.

Our case also describes the successful use of vascular ultrasound to identify a potentially important variation in the upper limb blood supply. Recognition of anomalous anatomy was until recently possible only with arteriography or post-mortem examination. Non-invasive imaging is emerging as a dependable means of identifying these variations, as described by Yan *et al.*⁷ They published their study on 638 patients undergoing percutaneous coronary procedures, and defined normal values for adults with satisfactory inter-

observer agreement. More recently, MRI has been employed to delineate the anomaly; however, our patient, as mentioned earlier, was not happy to undergo the procedure.⁸

The arterial anomalies are better understood with a description of the normal development of the arterial pattern in the upper limbs. The upper limb arteries arise from the seventh cervical inter-segmental artery. Rodriguez-Niedenfu *et al.* studied a total of 112 human embryos (224 upper limbs) between 3–5 weeks (developmental stages 12–23) of development, and observed that formation of the arterial system in the upper limb takes place as a dual process.⁹ An initial capillary plexus appears from the dorsal aorta during week 3 (stage 12) and develops at the same rate as the limb. Subsequently, during the second stage, the capillary plexus begins a maturation process involving the enlargement and differentiation of selected parts. This remodelling process starts in the aorta and continues in a proximal to distal sequence, and parallels chronologically the development of the

skeletal system.

Deviations are the result of the persistence, enlargement, and differentiation of parts of the initial network which would normally remain as capillaries, or even regress. These are generally detectable by 5 weeks (stage 23) as the brachial artery has already differentiated. Most of the malformations can be explained by intussusceptive angiogenesis which occurs by internal division of pre-existing capillary beds by protrusion of capillary endothelial cells into the lumen, creating two new vessels from one vessel. A similar process has also been described in larger arteries in addition to the capillaries. Four main embryologic groups of anomalies exist, namely: failure of the primitive artery to recede; failure of the primitive artery to form; aberrant origin of the native vessel, and ectopic location of an otherwise normal vessel.

Appreciation of variations in the upper extremity vasculature is essential to prevent injury, particularly in patients requiring dialysis or undergoing arteriography. Inappropriate cannulation of these arteries due to aberrant locations in or near the antecubital fossa can result in thrombosis, gangrene, and even amputation of the limb.¹⁰ Yan *et al.* have shown that percutaneous coronary procedures took longer and were associated with higher failure rates and artery occlusion when there were smaller than normal radial arteries.⁷

Difficulties in palpable pulses in the limbs may act as a trigger to initiate a range of investigations including assessment of the heart and blood tests for thromboembolic disorders, and all these can be avoided if an ultrasound can quickly identify the congenital anomaly that underlies the discrepancy in the pulses. AB, as he was otherwise well, only underwent an echocardiogram to search for any underlying cardiovascular anomalies, followed by the vascular ultrasound which explained the pulse discrepancy.

Conclusion

We have reported an 11 year-old boy with a weak radial pulse on the right hand, and the use of vascular ultrasound to explain the anomaly. Clinical

implications related to accidental arterial puncture and difficulties in any future cardiac catheterisations were discussed.

References

1. Ciervo A, Kahn M, Pangilinan AJ, Dardik H. Absence of the brachial artery: Report of a rare human variation and review of upper extremity arterial anomalies. *J Vasc Surg* 2001; 33:191–4.
2. McCormack L, Cauldwell E, Anson B. Brachial and antebrachial patterns: A study of 750 extremities. *Surg Gynecol Obstet* 1953; 96:43–54.
3. Fujii T, Masuda N, Tamiya S, Shima M, Toda E, Ito D, et al. Angiographic evaluation of right upper-limb arterial anomalies: implications for transradial coronary interventions. *J Invasive Cardiol* 2010; 22:536–40.
4. Ziakas AG, Koskinas KC, Gavrilidis S, Giannoglou GD, Hadjimiltiades S, Gourassas I, et al. Radial versus femoral access for orally anticoagulated patients. *Catheter Cardiovasc Interv* 2010; 76:493–9.
5. Baeza RA, Nebot J, Ferreira B, Reina F, Perez J, Saundo JR, et al. An anatomical study and ontogenetic explanation of 23 cases with variations in the main pattern of the human brachio-antebrachial arteries. *J. Anal* 1995; 187:473–9.
6. Niedenfuhr RM, Vazquez T, Nearn L, Ferreira B, Parkin I, Sanudo JR. Variations of the arterial pattern in the upper limb revisited: A morphological and statistical study, with a review of the literature. *J Anat* 2001; 199:547–66.
7. Yan ZX, Zhou YJ, Zhao YX, Zhou ZM, Yang SW, Wang ZJ. Anatomical study of forearm arteries with ultrasound for percutaneous coronary procedures. *Circ J* 2010; 74:686–92.
8. Claassen H, Schmitt O, Werner D, Schareck W, Kröger JC, Wree A. Superficial arm arteries revisited: Brother and sister with absent radial pulse. *Ann Anat* 2010; 192:151–5.
9. Docimo S Jr, Kornitsky DE, Hill RV, Elkowitz DE. Arterio-arterial malformation between a high origin radial artery and brachial artery within the cubital fossa – its clinical and embryological significance: A case report. *Cases J* 2009; 2:6836.
10. Hazlett JW. The superficial ulnar artery with reference to accidental intra-arterial injection. *CMAJ* 1949; 61:289–93.