

# Stump Appendicitis following Laparoscopic Appendectomy

Suresh Parameshwarappa,<sup>1</sup> \*Gabriel Rodrigues,<sup>1</sup> Raghunath Prabhu,<sup>1</sup> Charudutt Sambhaji<sup>2</sup>

التهاب جَدَعَة الزائدة (النهاية القاصية من الطرف المبتور)  
بعد عملية رفع الزائدة بالمنظار

سوريش باراميشوارابا، جابرييل رودريغيز، راغونات برابهو، تشارودوت سامبهاجي

**المخلص:** التهاب جَدَعَة الزائدة مرض سريري - مرضي نادر يتميز بالتهاب النهاية القاصية من الزائدة المبتورة بعد عملية إزالة الزائدة غير الكاملة. لا يشك في تشخيص الحالة عادة بعد إجراء عملية إزالة الزائدة. ندرج هنا حالة التهاب جدعة الزائدة عند شخص يافع سبق وأن تم إجراء عملية استئصال الزائدة بواسطة المنظار، الأمر الذي أدى إلى ضرورة التدخل جراحياً لإكمال إزالة الزائدة.

**مفتاح الكلمات:** التهاب الزائدة، جدعة، جراحة، تقرير حالة، الهند.

**ABSTRACT:** Stump appendicitis (SA) is a rare clinicopathologic entity characterised by inflammation of the appendiceal remnant after incomplete appendectomy. The diagnosis is not routinely suspected in patients who have previously undergone appendectomy. We report a case of SA in an adolescent boy who had previously undergone laparoscopic appendectomy. The case necessitated surgical completion of the appendectomy.

**Keywords:** Appendicitis; Stump; Surgery; Case report; India

**S**TUMP APPENDICITIS (SA) IS A RARE POST-appendectomy complication whose exact incidence and prevalence are not clearly defined.<sup>1</sup> The incidence of SA may be increasing, possibly because of widespread utilisation of laparoscopic appendectomy. This may result in a long appendiceal stump which is the commonest aetiology for stump appendicitis.<sup>2,3</sup> Confirmation is either by imaging studies or diagnostic laparoscopy. Only a few cases of SA have been reported in English medical literature.<sup>3</sup>

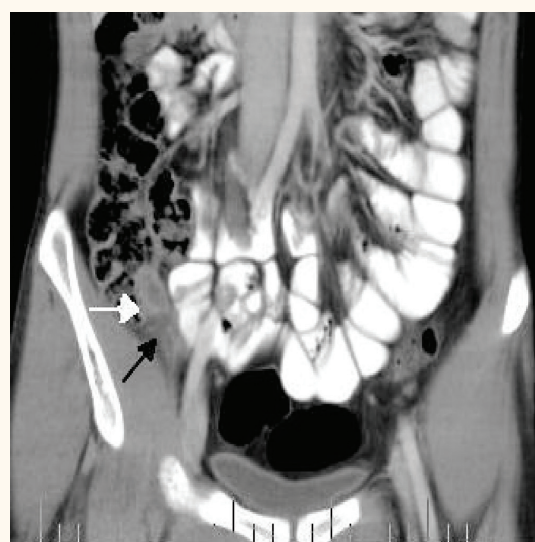
## Case Report

An eighteen-year-old boy who had undergone laparoscopic appendectomy one year previously presented at Kasturba Medical College Hospital, Manipal, India. He had lower abdominal pain of three days duration which was most acute in the right iliac fossa. It was not associated with fever and vomiting. He had had a similar episode six months previously, which had subsided with conservative treatment. The general physical examination was

unremarkable. Per abdominal examination revealed healed scars of laparoscopic surgery, along with tenderness in the right iliac fossa with no palpable mass. Laboratory investigations were within normal limits. A contrast enhanced computed tomography (CECT) scan of the abdomen and pelvis showed a short length tubular structure at the caput caecum with enhancing wall and stranding of adjacent periappendiceal fat consistent with an inflamed appendiceal stump [Figure 1]. A preoperative diagnosis of stump appendicitis was made and an open 'completion' appendectomy was performed with an uneventful postoperative period.

## Discussion

Stump appendicitis is rare following previous appendectomy, the known causative factor being a long residual stump. The true incidence and prevalence of SA are not known largely due to under-reporting and its poor definition.<sup>3</sup> The first case of SA was reported by Rose in 1945 and since then thirty-seven cases of 'residual appendicitis'



**Figure 1:** Distended residual appendicular stump (white arrow) at the caput caecum with periappendiceal fat stranding (black arrow) suggesting inflammation.

have been reported in English medical literature.<sup>2</sup> The age at presentation of SA ranged from 11 to 72 years (mean 39 years) with an equal incidence in both sexes. The time of onset ranged from two weeks to decades after the appendectomy.

Although no relationship between laparoscopic appendectomy and SA has yet been conclusively demonstrated, the occurrence of SA is more prevalent following laparoscopic appendectomy than conventional appendectomy.<sup>4,5</sup> The causes of SA are insufficient inversion of the stump, a long proximal remnant of the appendix, incomplete removal of the distal remnant and partial laparoscopic or laparotomic appendectomy. The growing utilisation of laparoscopic appendectomy may increase the frequency of stump appendicitis due to the potential limitations of this technique. These include a smaller field of vision, lack of three-dimensional perspective and the absence of tactile feedback, thus potentially leaving a longer stump.<sup>6</sup> Other causes reported in the literature include inadequate identification of the appendiceal base because of severe local inflammation; a retrocecal or sub-serous appendix; simple ligation of the appendix without invagination of the stump; leaving a long stump due to fear of caecal injury, and difficult dissection and local ulceration due to faecolith.<sup>3,6</sup> A stump longer than 5 mm serves as a reservoir for the faecolith, becomes ischaemic and eventually perforates. Inversion of the long stump

into the caecal wall does not necessarily prevent SA and other complications.<sup>7</sup> Clinically, SA patients present with signs and symptoms similar to those of appendicitis or acute abdomen and with a previous history of appendectomy. The presence of an appendectomy scar does not absolutely rule out the possibility of SA.<sup>4</sup>

Ultrasonography (USG) and a CT scan of the abdomen constitute the modalities of choice for preoperative diagnosis of SA. USG can reveal a thickened appendix stump, fluid in the right iliac fossa and caecal oedema.<sup>8</sup> A CT scan of the abdomen and pelvis is more useful than USG for the accurate preoperative diagnosis of SA, as it also excludes other aetiologies.<sup>1</sup> The CT features of SA are similar to those of acute appendicitis, which include pericecal inflammatory changes, abscess formation, fluid in the right paracolic gutter, cecal wall thickening, and an ileocecal mass. A specific diagnosis of SA can be made preoperatively when inflammatory changes surround a distended appendiceal stump.<sup>3,5</sup> Barium studies and colonoscopy have also been reported as being helpful in diagnosing SA.<sup>9,10</sup> Diagnostic laparoscopy is gaining popularity and can be helpful for the diagnosis of SA.<sup>6</sup>

SA is most commonly treated by an open operation, but cases successfully treated using laparoscopic intervention, have been reported.<sup>3</sup> Very rarely, an aggressive surgery such as ileocolic resection may be obligatory. Laparoscopy seems to be more successful than conventional laparotomy as it permits a global inspection of the abdominal cavity and an easier adhesiolysis.<sup>3</sup> Accurate visualisation of the base and leaving a stump less than 3 mm in depth can minimise the incidence of SA.<sup>11</sup> Use of angled scopes may provide good visualisation of the appendix.<sup>12</sup>

## Conclusion

The diagnosis of SA is often missed or delayed. It should be considered in patients presenting with right lower abdominal pain and a history of previous appendectomy. CT imaging studies help in preoperative diagnosis of SA. Completion of the appendectomy by conventional or laparoscopic means is the treatment of choice for SA.

## References

---

1. Shin LK, Halpern D, Weston SR, Meiner EM, Katz DS. Prospective CT diagnosis of stump appendicitis. *AJR Am J Roentgenol* 2005; 184:S62–4.
2. Aschkenasy MT, Rybicki FJ. Acute appendicitis of the appendiceal stump. *J Emerg Med* 2005; 28:41–3.
3. Gasmi M, Fitouri F, Sahli S, Jemai R, Hamzaoui M. A stump appendicitis in a child: a case report. *Ital J Pediatr* 2009; 35:35.
4. Al-Dabbagh AK, Thomas NB, Haboubi N. Stump appendicitis. A diagnostic dilemma. *Tech Coloproctol* 2009; 13:734.
5. O'Leary DP, Myers E, Coyle J, Wilson I. Case report of recurrent acute appendicitis in a residual tip. *Cases J* 2010; 3:14.
6. Walsh DC, Roediger WE. Stump appendicitis. A potential problem after laparoscopic appendectomy. *Surg Laparosc Endosc Percut Tech* 1997; 7:357–8.
7. Uludag M, Isgor A, Basak M. Stump appendicitis is a rare delayed complication of appendectomy: A case report. *World J Gastroenterol* 2006; 12:5401–3.
8. Baldisserotto M, Cavazzola S, Cavazzola LT, Lopes MH, Mottin CC. Acute edematous stump appendicitis diagnosed preoperatively on sonography. *AJR Am J Roentgenol* 2000; 175:503–4.
9. De U, De KK. Stump appendicitis. *J Ind Med Assoc* 2004; 102:329.
10. Nahon P, Nahon S, Hoang JM, Traissac L, Delas N. Stump appendicitis diagnosed by colonoscopy. *Am J Gastroenterol* 2002; 97:1564–5.
11. Mangi AA, Berger DL. Stump appendicitis. *Am Surg* 2000; 66:739–41.
12. Durgun AV, Baca B, Ersoy Y, Kapan M. Stump appendicitis and generalized peritonitis due to incomplete appendectomy. *Tech Coloproctol* 2003; 7:102–4.