

Ovarian Vein Thrombophlebitis

An unusual cause of postpartum fever and abdominal pain

*Anupam K Kakaria

الالتهاب الخثاري في وريد المبيض حالة غير اعتيادية لحمى وألم البطن بعد الولادة

انوبام كومار كاكاريا

الملخص: الالتهاب الخثاري لوريد المبيض حالة نادرة، لكنها خطيرة في الولادات المعقدة. تمزق الأغشية قبل فترة طويلة من الولادة يكون أحد العوامل المسببة لذلك. هذا التقرير يصف حالة تمزق الأغشية قبل فترة طويلة من الوضع، والذي أدى إلى حصول الالتهاب الخثاري لوريد المبيض. عولجت المريضة بالأدوية وتحسنت بشكل ملموس.

مفتاح الكلمات: تمزق الأغشية لفترة طويلة. الالتهاب الخثاري لوريد المبيض. حمى ما بعد الولادة. تقرير حالة. عمان.

ABSTRACT Ovarian vein thrombophlebitis is an uncommon, but potentially serious, complication of complicated deliveries. Prolonged rupture of membranes prior to delivery is a pre-disposing factor. We report a case of a patient with prolonged ruptured membranes, who developed right ovarian vein thrombophlebitis. The patient was managed medically and responded favourably to treatment.

Keywords: Prolonged ruptured membranes, Ovarian vein thrombophlebitis, Postpartum fever, Case report, Oman

PAIN IN THE LOWER ABDOMEN IN FEMALE patients can be a confusing problem at the best of times. In the immediate postpartum period, the situation is worsened as the list of possible diagnoses expands to include problems peculiar to the puerperal state like adnexal torsion, broad ligament hematoma and abscesses, in addition to the usual causes of pain like acute appendicitis,¹ diverticulitis etc. The post partum state is characterized by many physiological changes including ligamentous laxity, hypercoagulability and other changes peculiar to this particular physiological event. It may be further compounded by bacterial inoculum caused by complicated parturition. Post partum ovarian vein thrombophlebitis is an uncommon, potentially serious puerperal complication,

unless it is diagnosed and treated promptly. Prior to the introduction of cross sectional imaging, the diagnosis and management were often delayed. As the clinical examination and laboratory investigations are not able to delineate the problem clearly and provide a definitive diagnosis, imaging plays an important role in diagnosis and management of these patients. Imaging can now provide an accurate and reliable method for the diagnosis and follow up of these patients. This may lead to early surgery if required. On the other hand, an alternative diagnosis can lead to medical management and obviate the need for unnecessary exploration. This complication is reported in 1 in 600 to 1 in 2,000 deliveries.²

*Department of Radiology, Armed Forces Hospital, PO Box 726, PC 111, CPO Seeb, Muscat

Email: bittanupam@gmail.com

CASE REPORT

The patient was a 26 year old female who presented to the Antenatal Clinic of the Armed Forces Hospital, Muscat, at a gestation age of 30 weeks. She was gravida three, para two with two living children. She presented with the chief complaint of liquid leaking from the vagina. On examination, the fundal height was consistent with the gestational age. An ultrasound revealed a normal for age fetus, but with reduced amniotic fluid. In view of the diagnosis of spontaneous rupture of membranes and the early gestational age, the patient was admitted and started on three antibiotics prophylactically (a third generation cephalosporin, an aminoglycoside and an antianerobic antibiotic) and dexamethasone. This was standard practice by gynecologists in this hospital for prolonged rupture of membranes. In spite of all efforts to prolong the gestation, the patient delivered spontaneously, vaginally on the 9th day of admission. Although triple antibiotics were administered, the patient started to have spikes of fever reaching up to 39° C from the 11th day of admission. The white blood cell count was $12 \times 10^9/l$ with 85% polymorphonuclear cells, and she started to complain of pain in the right iliac fossa from the 13th day of admission. On examination, there was tenderness on deep palpation of the right iliac fossa. Mild rebound tenderness could be elicited. Clinically acute appendicitis was suspected and the patient was referred for ultrasound examination. Evaluation of the right iliac fossa revealed a long, tubular, non compressible aperistaltic structure located to the right of the inferior vena cava (IVC). The ultrasound findings and the clinical review did not produce a good fit for acute appendicitis and the patient was subjected to a computed tomography (CT) scan for further evaluation. Contrast enhanced CT identified a round lesion in the right paracaval region, with central hypodensity and marginal enhancement. The lesion veered towards the right iliac fossa on caudal scans. On cranial scans, the lesion indented and then projected into the lumen of the IVC [Figs. 1 & 2]. A coronal reformat showed better the course of the lesion away from the cecum and pointing towards the IVC. The findings were consistent with the diagnosis of right ovarian vein thrombosis. The diagnosis had not been considered and came as a surprise. With this diagnosis in mind, two of the antibiotics (the aminoglycoside and the anti anaerobic antibiotic) were stopped empirically on the basis of the prevalent flora in the hospital at the time) and the pa-

tient was started on IV low molecular weight heparin. The patient, who had continued to be febrile on three antibiotics, improved significantly with the introduction of low molecular weight heparin and was afebrile within 48 hrs. The patient continued I/V heparin for 7 days after which she was put on oral anti coagulation titrated to keep INR of around 2-2.5. She continued oral anticoagulation for four weeks after which she was lost to follow up. Further investigations for thrombophilia were not done in view of clear precipitating factors for the thrombophlebitis (prolonged rupture of membranes) and no previous history of thrombotic events in the previous pregnancies or otherwise.

DISCUSSION

Post partum ovarian vein thrombosis is an uncommon, but potentially serious, complication of post partum sepsis.³ Ovarian vein thrombosis has an incidence of 1:600 to 1:2,000 deliveries.⁴ Virchow's triad is closely related to the pathogenesis of the puerperal vein thrombosis. The Virchow's triad consists of (a) change in circulating coagulation factor levels, (b) alterations in the vein walls, (c) stasis of blood flow. Pregnancy and puerperium fulfill the first and the third criteria and the venous walls may be altered by the surgical trauma and bacterial insult to the endothelium. In addition, high thromboplastin levels in placenta and amniotic fluid may gain access to maternal circulation during parturition.

Right ovarian vein is involved in 80-90% of patients.^{2,3} The increased incidence of the right vein involvement may be partly due to dextrorotation of the enlarging uterus which compresses the right ovarian vein at the pelvic brim and partly due to retrograde flow from the left ovarian and uterine veins into the right system, which increases the size of the bacterial inoculum in the right ovarian vein. In addition, the increased length of the right ovarian vein and presence of multiple incompetent valves are contributory factors.⁵

The patients complain of pyrexia starting 2-4 days postpartum or post operatively. Lower quadrant pain on right or the left side, depending on the side of vein involved, may be associated with chills, tachycardia, nausea, and vomiting.^{5,6,7} Acute appendicitis, adnexal torsion, abscess, pyelonephritis are the differential diagnoses.

Ultrasound is the initial imaging investigation of choice and usually can suggest the correct diagnosis.

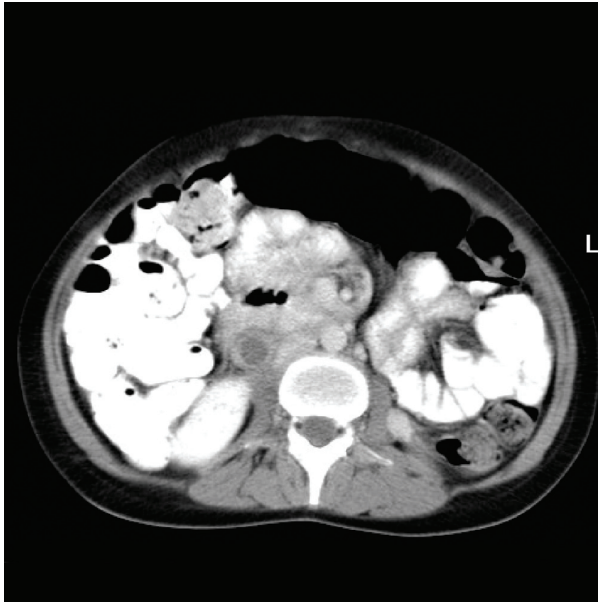

Figure 1: CECT shows a round hypodense lesion to the right of the IVC with marginal enhancement

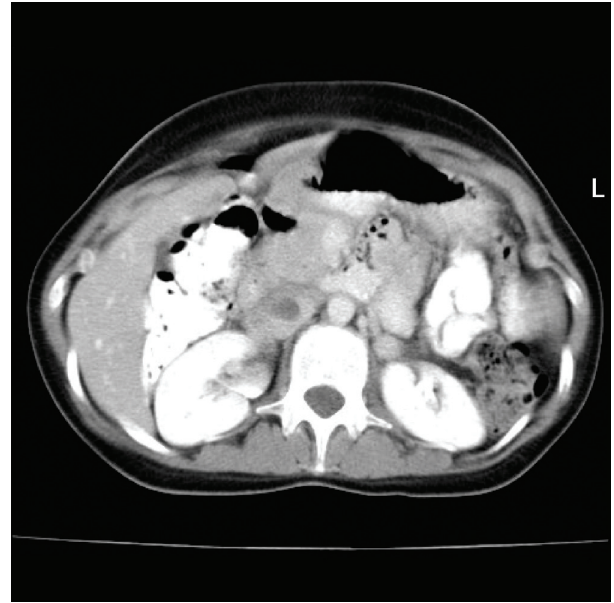


Figure 2: Cranially the lesion extends up to the IVC, indents it and projects into the lumen of IVC

In cases of ambiguity, CT with contrast can help in resolving this dilemma. Due to flow sensitivity and ability to assign the age to the venous clot, the MRI may be of use in difficult cases. Surgical ligation of the ovarian vein was sometimes used in the past for controlling a possible pulmonary embolism. Currently, the management is mainly medical. There is no standard protocol for the duration of anticoagulation or conversion to warfarin.² Surgical excision may have to be resorted to in cases of failure of medical management and pulmonary embolism.⁸

CONCLUSION

Recognition and adequate treatment of this rare but significant complication of pregnancy is critical as it can lead to significant maternal morbidity.⁹ Since the clinical and laboratory parameters are non-specific and there is no clear set of predisposing factors, the diagnosis of ovarian vein thrombosis remains difficult. This mandates a high index of suspicion and ovarian vein thrombosis should be in the list of differential diagnoses in post partum patients undergoing evaluation for abdominal pain and fever in spite of adequate antibiotic treatment.

REFERENCES

1. Jinxing Yu, Fulcher AS, Turner MA, Halvorsen RA. Am J Roentgenol. Helical CT Evaluation of Acute Right

- Lower Quadrant Pain: Part II, Uncommon Mimics of Appendicitis 2005; 184:1143-1149.
2. Dähnert W. Radiology Review Manual, 5th ed. Philadelphia: Lippincott, Williams & Wilkins, 2003. p. 1050
3. Gourlay M, Gutierrez C, Chong A, Robertson R. Group A streptococcal sepsis and ovarian vein thrombosis after an uncomplicated vaginal delivery. J Am Board Fam Pract 2001; 14:375-80.
4. Jain KA, Jeffrey RB Jr. Gonadal vein thrombosis in patients with acute gastrointestinal inflammation: diagnosis with CT. Radiology 1991; 180:111-113.
5. Savader SJ, Otero RR, Savader BL. Puerperal ovarian vein thrombosis: Evaluation with CT, US and MR imaging. Radiology 1988; 167:637-639.
6. Munsick RA, Gillanders LA. A review of the syndrome of puerperal ovarian vein thrombophlebitis. Obstet Gynecol Surg 1981;36:57-66.
7. Duff P, Gibbs R. Pelvic vein thrombophlebitis: diagnostic dilemma and therapeutic challenges. Obstet Gynecol Surg 1983; 38:365-373.
8. Carr S. Surgical treatment of ovarian vein thrombosis. Vasc Endovascular Surg 2007; 40:505-508.
9. Kominiarek MA, Hibbard JU. Post partum ovarian vein thrombosis: an update. Obstet Gynecol Surv 2006; 61:337-442.