

Pulmonary Infarction

A rare case of adrenal carcinoma

*Sukhpal Sawhney¹, Ikram Burney², Rajeev Jain¹

احتشاء الرئة حالة نادرة من سرطانة الكظر

سخبال سوهني، اكرام بورني وراجيف جين

المخلص: هذا تقرير حالة شابة أدخلت للمستشفى لعدة مرات بسبب انخفاض ضغط الدم. وكان لديها سرطانة الكظر غير المشخص مع انسداد الشريان الرئوي. التصوير المقطعي المحوسب أظهر كتلة كبيرة في غدة الكظر اليمنى ممتدة إلى الوريد الأجوّف السفليّ، الأذين الأيمن، البطين الأيمن والشريان الرئوي الأيمن. في الأدبيات الطبية، هناك العديد من تقارير لحالات توثق خثرة كلا من الوريد الأجوّف السفلي والأذين الأيمن عند المرضى المصابين بسرطانة الكظر. حسب علمنا هذه أول حالة توثق بصورة خاصة الاحتشاء الرئوي نتيجة امتداد الورم إلى الشريان الرئوي.

مفتاح الكلمات: سرطانة الكظر، احتشاء الرئة، التّصوُّيرُ المَقْطَعِيُّ المَحُوسَّب. تقرير حالة، عمان.

ABSTRACT A case report of unsuspected adrenal carcinoma with pulmonary artery obstruction in a young girl who was admitted with recurrent episodes of hypotension is presented. Computed tomography (CT) scans demonstrated a large right adrenal mass extending into the inferior vena cava (IVC), right atrium, right ventricle and right pulmonary artery. There are many case reports in literature documenting IVC and right atrial thrombus in patients with adrenal carcinoma. To our knowledge, this is the first case report specifically documenting pulmonary infarction secondary to tumour extension into the pulmonary artery.

Keywords: Adrenal carcinoma, Pulmonary infarction, Computed Tomography, Case report, Oman.

WE REPORT A CASE OF A PREVIOUSLY well young girl with newly diagnosed adrenal carcinoma, who presented with a pulmonary infarction due to a tumour thrombus extending in-continuity from the inferior vena cava to the right atrium, right ventricle and pulmonary artery. She did not have any clinical or imaging studies in the past. There have been no previous reports specifically documenting pulmonary embolism from a tumour thrombus of adrenal carcinoma, though there are many reports in literature documenting inferior vena cava and right atrial thrombus in patients with adrenal carcinoma. This is the first reported case of adrenal cortical carcinoma presenting as pulmonary infarction

in which a computed tomography (CT) scan established the diagnosis.

CASE REPORT

A 15-year-old girl was referred to a tertiary hospital in urban Oman with a two-month history of sudden onset of hirsutism, acne, and a three-day history of episodes of prolonged hypotension, with blood pressure dropping to 90/60 mmHg. Her past medical history was not significant for medical or surgical illness. However, the menstrual history was significant, in that she had not attained menarche. On examination, she had a pulse rate of 138/min, blood pressure of 110/70mmHg, had a coarse voice, hirsutism, acne, ascites, and bilateral

¹Department of Radiology and Molecular Imaging, Sultan Qaboos University Hospital, P. O. Box 35, Al-Khod 123, Sultanate of Oman ²Department of Medicine, Sultan Qaboos University, P. O. Box 35, Al-Khod 123, Sultanate of Oman

*To whom correspondence should be addressed. Email: sukh@squ.edu.om

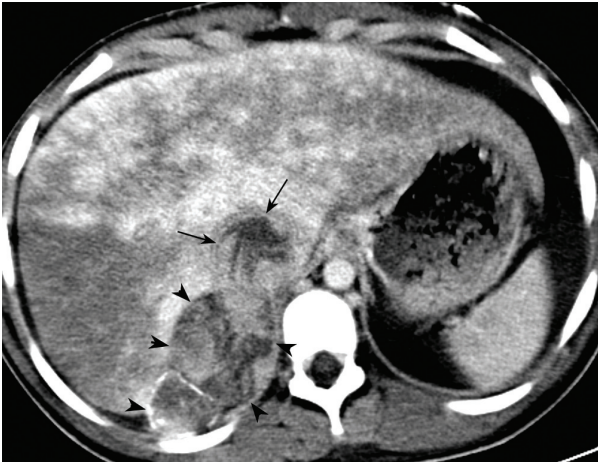


Figure 1: Contrast-enhanced CT scan of upper abdomen shows an enhancing mass in the right adrenal gland (arrowheads), extending into the intrahepatic inferior vena cava (IVC) see arrows. Geographic hepatic parenchymal enhancement together with IVC occlusion by enhancing tumour thrombus indicates hepatic venous outflow obstruction (Budd-Chiari syndrome)

pitting edema. Her external genitalia were normal. The oxygen saturation was 95%, and blood gases revealed pH 7.42, pCO₂ 2.4 KPa, PO₂ 11.9 KPa, HCO₃ 11.9 mmol/l. The results of the full blood count were as follows: Hb 16.1 g/dl, WBC 16.8x10⁹/l, cytology platelets 208 x 10⁹ / l. Ascitic tap revealed lymphocytic exudates, with a protein content of 22.8gm/l. Serum cortisol levels were 6284 nanomol/L.

A CT scan of her abdomen and chest was performed. A contrast enhanced CT scan (CECT) of the abdomen showed a large enhancing mass in the right adrenal gland. The mass was extending into and within the extrahepatic and intrahepatic course of the inferior vena cava. The liver showed features of Budd-Chiari syndrome in the form of an enlarged liver with areas of patchy parenchymal enhancement and multiple enhancing regenerative nodules. Hepatic veins could not be identified [Fig 1]. A CECT scan of her chest at the level of the heart showed a mass in the right atrium extending into the right ventricle [Fig 2]. The CT scan at the level of the main pulmonary arteries showed an extension of the tumour in the right main pulmonary artery, with diminished perfusion of the lung distally [Fig 3]. The patient died on the third day after admission, before any surgical intervention could be contemplated.

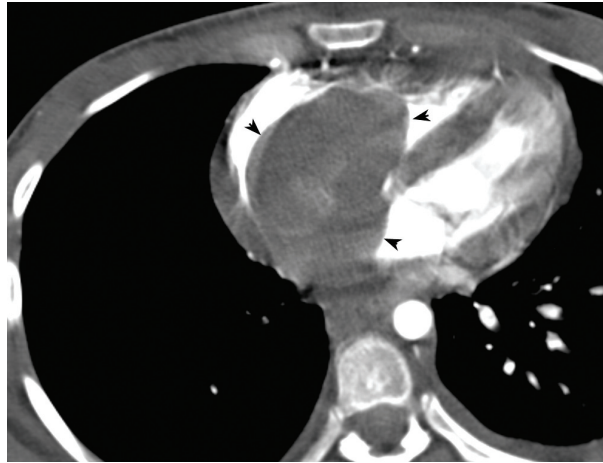


Figure 2: Contrast-enhanced CT scan of chest at the level of the right ventricle shows a large tumour thrombus as a filling defect in the right atrium and ventricle (arrowheads). Hardly any enhancing pulmonary arteries are identified on the right side

DISCUSSION

This is the first reported case of an adrenal tumour with an IVC thrombus extending into the pulmonary artery. The estimated incidence of adrenocortical carcinomas in patients younger than 20 years of age is three per million of the population.¹ Of adrenal tumours in children, adrenocortical neoplasms are far less common than neuroblastomas, but more common than pheochromocytomas.² It is now recognized that most children with an adrenocortical neoplasm show clinical evidence of an endocrine abnormality, in contrast to the behaviour of adrenocortical neoplasms in adults.³

Although the commonest cause of inferior vena cava extension of a tumour is from renal cell carcinoma, various other tumours, such as leiomyosarcomas of the inferior vena cava, adrenal cortical carcinomas, pheochromocytomas, neuroblastomas, transitional cell carcinomas of the renal pelvis, metastatic small cell carcinomas and Wilms tumours have been described to extend into the inferior vena cava.⁴ Pulmonary artery tumour thrombus has been reported in patients with renal cell carcinomas,^{5,6} but to our knowledge there is no reported case of an adrenal carcinoma with tumour thrombus extension into the pulmonary artery.

Adrenal carcinomas may extend into the renal veins and inferior vena cava, and are usually accompanied by a thrombus.⁷ Right atrial involvement is very rare.⁷ Evidence suggests that as many as a third of primary

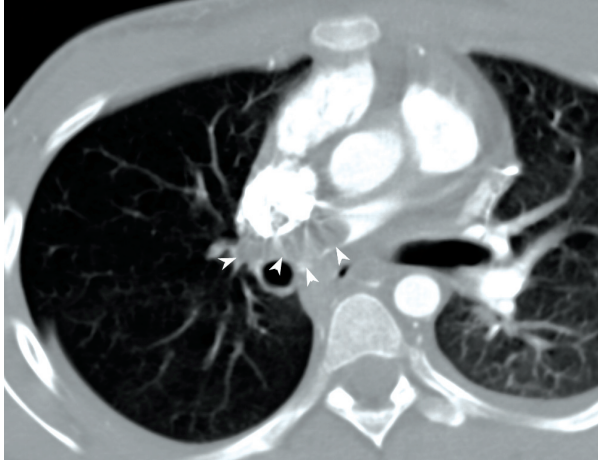


Figure 3: Contrast-enhanced CT scan of chest demonstrates a thrombus in the right main pulmonary artery (arrowheads) with diminished arterial perfusion of the right lung.

adrenocortical cancers may develop a tumour thrombus within the inferior vena cava.⁸ The thrombus may be asymptomatic or may become manifest as ascites, nephrotic syndrome, hepatomegaly, acute tricuspid valve failure or the Budd-Chiari syndrome.⁹

A limitation of this case report is the lack of availability of a tissue diagnosis. The patient was very ill at presentation, in a state of hypotension and pursued a rapid downhill course, succumbing to the disease within three days of admission. However, virilising clinical features, a very high serum cortisol, together with a radiological picture of an adrenal mass with extension into the IVS, right atrium and right pulmonary artery are highly suggestive of an adrenal carcinoma.

CONCLUSION

Patients with adrenocortical carcinomas may have an extensive inferior vena caval tumour thrombus, which can extend into the right cardiac chambers and occasionally into the pulmonary arteries. Such patients may present with clinical features of pulmonary infarction.

Alternatively, cardiac and/or pulmonary extensions of tumour thrombi may be overlooked, if not assiduously looked for. Therefore, a complete evaluation of a patient with adrenocortical carcinoma should include an evaluation of the cardiac chambers with echocardiography or contrast-enhanced CT scans.

REFERENCES

1. Lack EE, Mulvihill JJ, Travis WD, Kozakewich HP. Adrenal cortical neoplasms in the pediatric and adolescent age group: clinicopathologic study of 30 cases with emphasis on epidemiological and prognostic factors. *Pathol Ann* 1992; 27:1-53.
2. Stewart DR, Jones PH, Jolleys A. Carcinoma of the adrenal gland in children. *J Pediatr Surg* 1974; 9:59-67.
3. Lack EE. Adrenal cortical neoplasms in childhood. In Lack EE, Ed. *Atlas of tumors of the adrenal gland and extra adrenal paraganglia*. Fasc 19, Ser 3. Washington, DC: Armed Forces Institute of Pathology, 1997. p. 153-168.
4. Chesson JP, Theodorescu. Adrenal Tumor with caval extension. Case report and review of the literature. *Scand J Urol Nephrol* 2002; 36: 71-73
5. G Gayer, S. Mini, D. Olchovosky, et al. Pulmonary embolism - the initial manifestation of renal cell carcinoma in a young woman. *Emerg. Radiol* 2003; 10:43-45.
6. Wieder JA, Laks H, Freitas D, Marmureanu A, Belldegrun A. Renal cell carcinoma with tumor thrombus extension into the proximal pulmonary artery. *J Urol* 2003; 169: 2296-2297.
7. Rosen B, Rozenman Y, Harpaz D. Extension of adrenocortical carcinoma into the right atrium-echocardiographic diagnosis; A case report. *Cardiovas Ultrasound* 2003; 16:5.
8. Radecka E, Brekkan E, Juhlin C, Sundin A, Magnusson A. An unusual case of tumor thrombus in the inferior vena cava. *Acta Radiol* 2003; 44:160-161
9. Hugh TB, Jones RM, Shanahan MX. Intra-atrial extension of renal and adrenal tumors: diagnosis, management, and prognosis. *World J Surg* 1986; 10:496-500.