

BRIEF ARTICLES

Cutaneous Nontuberculous Mycobacteria Infection after Cosmetic Tattooing: A Case Report

Jennifer Seyffert, DO¹, Christopher Wong, BS², Sadia Saeed, MD¹, David Fitzmaurice, PA-C¹

¹KCUMB-Advanced Dermatology and Cosmetic Surgery, Orlando, FL

²Western University of Health Sciences, Pomona, CA

ABSTRACT

Nontuberculous (atypical) mycobacteria rarely cause skin and soft tissue infections. Tattooing with contaminated gray ink has been implicated in previously reported outbreaks. We report the case of a 39-year-old Hispanic man who presented with a refractory, pruritic, papular eruption within the distribution of his tattoo with punch biopsy demonstrating papillary dermal granulomatous and suppurative inflammation surrounding small collections of acid-fast bacilli with associated superficial and deep dermal perivascular lymphatic inflammation consistent with nontuberculous mycobacterial infection. Although uncommon, clinicians should consider nontuberculous mycobacterial infection in the differential diagnosis of refractory tattoo-associated skin eruptions.

INTRODUCTION

Nontuberculous mycobacteria (NTM), also known as atypical mycobacteria, are acid-fast bacilli (AFB) and are subcategorized by growth rate and pigment production. Though almost all NTM species have been associated with skin and soft tissue infections, rapidly-growing mycobacteria (RGM) species are most often responsible. The NTM RGM species which most commonly cause cutaneous infections include *Mycobacterium fortuitum*, *M. chelonae*, and *M. abscessus*.¹ Clinical presentations of cutaneous infection by NTM vary widely. Lesions may initially appear as papules, plaques, pustules, nodules, folliculitis, abscesses, cellulitis, or panniculitis; these may progress to ulceration or draining sinus tracts. Lesions

may spread in a sporotrichoid pattern along lymphatic vessels.^{1,2} Due to overlapping and nonspecific clinical features, cutaneous NTM infections require a high index of suspicion for diagnosis and should be considered in patients who present after a surgical or cosmetic procedure and fail to respond to initial therapy.

CASE PRESENTATION

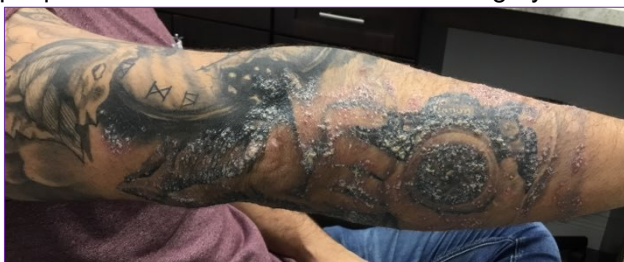A 39-year-old Hispanic man with no significant past medical history presented for evaluation of a tender, pruritic, papular rash present for four days within the distribution of his new tattoo, which he had completed 2 days prior to rash onset. He denied fevers, chills, weight loss, and other constitutional symptoms. Dermatologic examination demonstrated numerous erythematous to

July 2020 Volume 4 Issue 4

violaceous hyperkeratotic papules coalescing into plaques with excoriation localized to areas tattooed with grey ink (Figure 1). Despite initial therapy with topical triamcinolone cream, oral prednisone, oral doxycycline, and oral fluconazole, the eruption continued to evolve without improvement, prompting two 5-mm punch biopsies for H&E and DIF.

Histologic examination demonstrated a focal area of papillary dermal granulomatous and suppurative inflammation with associated superficial and deep perivascular lymphocytic infiltrate (Figure 2). AFB and Fite stains highlighted small collections of acid-fast bacilli within the granulomatous inflammation (Figure 3). PAS stain was negative for fungi and *Treponema pallidum* immunoperoxidase analysis was negative for spirochetes. Along with the clinical examination, the histologic findings supported a diagnosis of atypical mycobacterial infection in association with grey tattoo ink. Additional biopsies for tissue cultures and PCR were performed, and the patient began doxycycline, moxifloxacin, and clarithromycin. The subsequent culture and PCR testing were negative.

Figure 1. Hyperkeratotic papules coalescing into plaques distributed in areas tattooed with grey ink.



DISCUSSION

Infection by NTM is not currently a reportable disease in much of the United States; thus, estimating the total disease burden is difficult. The overall incidence of

cutaneous NTM infection is rare with a reported incidence of approximately 0.9-2.0 cases per 100,000 persons; however, the incidence rate has risen threefold since 1980.¹ NTM species are ubiquitous in the environment, with a recent study finding 78% of tap water samples positive for NTM.³

Figure 2. Low power H&E demonstrating focal area of papillary dermal granulomatous and suppurative inflammation with associated superficial and deep perivascular lymphocytic infiltrate.

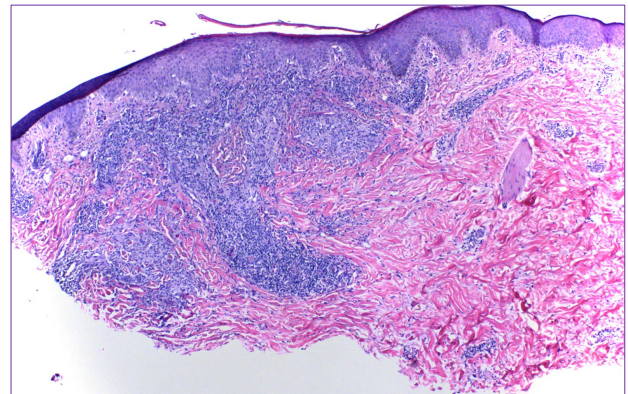
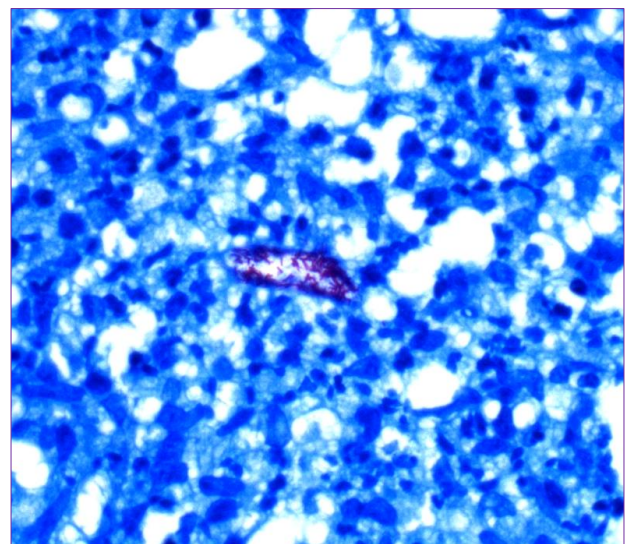


Figure 3. Positive Fite stain demonstrating acid fast bacilli.



Surgical or cosmetic procedures are a known risk factor for NTM infections. A recent systematic review identified 25 case reports and another systematic review described 114 cases of NTM infection after tattooing.⁴ In a number of these cases, the

July 2020 Volume 4 Issue 4

ink used tested positive for NTM species. Black ink is presumably diluted with contaminated tap water to create grey ink, which has been commonly implicated as the source of NTM infection.^{5,6} Additional cases after 2013 have been reported in association with contaminated grey ink,⁷⁻¹⁰ as well as one case of NTM infection in red ink.¹¹ *Mycobacterium chelonae* was the most common culprit identified in several cases by tissue culture and PCR, however as with our case, identification of the caustic mycobacterial agent was not feasible in all reported cases.

In addition to the history and physical examination, evaluation of suspected NTM infection should include skin biopsy and tissue cultures. Histopathologic examination most characteristically shows suppurative granulomas with admixed lymphocytes and foci of necrosis, as were present in our patient. If an infectious etiology is suspected, multiple AFB stains may be used to identify organisms due to a low positivity rate of 16-21% for a single stain.¹

Cultures are the gold standard for diagnosis of NTM infection. Incubation at temperatures between 28-30°C and 35-37°C provide optimal conditions for growth. Most RGM species require more than a week to grow in primary culture, but they may grow within 7 days on subculture. Molecular biologic techniques, including DNA probing, PCR, and mass spectrometry, may provide more immediate diagnostic results; however, these modalities do not offer susceptibility testing for the identified species.¹ Despite these recommendations, diagnosis and identification of the particular organism has proven difficult in our case as well as others.

Selection of appropriate antimicrobial therapy depends on identification of the responsible mycobacterial species and

susceptibility testing. Clarithromycin 500 mg twice a day for a minimum of four months, in combination with an additional agent to prevent resistance, is recommended; surgical intervention may be required with extensive infection or abscess formation.¹²

CONCLUSION

We report a rare case of cutaneous infection by NTM following tattooing with presumably contaminated gray ink. Clinicians should be alert to this possible diagnosis when examining patients presenting with a refractory eruption within a recently placed tattoo.

ABBREVIATIONS

NTM: Nontuberculous
AFB: Acid-fast bacilli
RGM: Rapidly-growing mycobacteria
H&E: Hematoxylin and eosin
DIF: Direct immunofluorescence
PAS: Periodic acid-Schiff
PCR: Polymerase chain reaction
DNA: Deoxyribonucleic acid

Conflict of Interest Disclosures: None

Funding: None

Corresponding Author:

Jennifer Seyffert, DO
260 Lookout place, Suite 103
Maitland, FL 32751
Phone: 847-987-4977
Fax: 407-333-2140
Email: Jennifer.seyffert@adcsclinics.com

References:

1. Chung J, Ince D, Ford BA, Wanat KA. Cutaneous Infections Due to Nontuberculosis Mycobacterium: Recognition and Management.

- Am J Clin Dermatol.* 2018;19(6):867-878.
doi:10.1007/s40257-018-0382-5
2. Misch EA, Saddler C, Davis JM. Skin and Soft Tissue Infections Due to Nontuberculous Mycobacteria. *Curr Infect Dis Rep.* 2018;20(4):6.
doi:10.1007/s11908-018-0611-3
 3. Donohue MJ, Mistry JH, Donohue JM, et al. Increased Frequency of Nontuberculous Mycobacteria Detection at Potable Water Taps within the United States. *Environ Sci Technol.* 2015;49(10):6127-6133.
doi:10.1021/acs.est.5b00496
 4. Mudedla S, Avendano EE, Raman G. Nontuberculous mycobacterium skin infections after tattooing in healthy individuals: A systematic review of case reports. *Dermatol Online J.* 2015;21(6).
 5. Bounniyt H, Guth-Muller S, Zimmermann U, Blom A, Saiag P. Une complication rare d'un tatouage permanent. *Presse Médicale.* 2018;47(1):94-95. doi:10.1016/j.lpm.2017.10.013
 6. Griffin I, Schmitz A, Oliver C, et al. Outbreak of Tattoo-associated Nontuberculous Mycobacterial Skin Infections. *Clin Infect Dis.* November 2018.
doi:10.1093/cid/ciy979
 7. Frew JW, Nguyen RT. Tattoo-associated mycobacterial infections: an emerging public health issue. *Med J Aust.* 2015;203(5):223.
doi:10.5694/mja15.00098
 8. Brooks J, Behrens E, Prickett K. Painful and Pruritic Papules in the Gray Shading of a Tattoo. *JAMA Dermatol.* 2016;152(2):205.
doi:10.1001/jamadermatol.2015.3448
 9. Painsi C, Lange-Asschenfeldt B. Image Gallery: Pink papules within a tattoo linked to *Mycobacterium chelonae* infection. *Br J Dermatol.* 2017;177(1):e1-e1.
doi:10.1111/bjd.15481
 10. Velez L, Harb J, Anuszewski S, Wesson S. Cutaneous *Mycobacterium massiliense* infection from tattooing: a common yet under-reported and persistent epidemic hazard for dermatologists. *BMJ Case Rep.* January 2018:bcr-2017-222762.
doi:10.1136/bcr-2017-222762
 11. Bhargava A, Chandrasekar PH. Gradually Worsening Tattoo Lesion. *JAMA.* 2015;314(19):2071.
doi:10.1001/jama.2015.10066
 12. Griffith DE, Aksamit T, Brown-Elliott BA, et al. An Official ATS/IDSA Statement: Diagnosis, Treatment, and Prevention of Nontuberculous Mycobacterial Diseases. *Am J Respir Crit Care Med.* 2007;175(4):367-416.
doi:10.1164/rccm.200604-571ST