

BRIEF ARTICLES

Truncal Demodex Folliculitis

Timothy J. Orlowski, M.D.¹, H. Harris Reynolds², M.D.², Lauren V. Graham, M.D., Ph.D.²

¹1479th Flying Training Group, Aviation Medicine Department, Naval Hospital Pensacola, Pensacola, (FL) USA

²University of Alabama at Birmingham, Department of Dermatology, Birmingham, (AL) USA

ABSTRACT

Demodex brevis and *Demodex folliculorum* are two species of ubiquitous parasites whose role in human disease continues to be fully elucidated.^{1,2} *Demodex* most commonly causes symptomatic infestations confined to the head and neck.³ Clinically, symptoms may mimic acne vulgaris, papulopustular rosacea, perioral dermatitis, and seborrheic dermatitis, among others.¹⁻³ Practitioners must maintain a high level of suspicion to avoid misdiagnosis.

INTRODUCTION

A 42-year-old man with skin-type II was referred to our dermatology outpatient clinic for a 10-year history of a rash on his face, upper chest and upper back. The rash was constantly present and would acutely flare once to twice monthly. These flares would last for several days and would resolve regardless of attempted treatments. During each flare, the rash would become more painful than baseline, with accompanying serous exudate. The patient was unable to identify any triggers for his flares and denied any exacerbation of symptoms by sunlight. He had previously been treated for seborrheic dermatitis and tinea corporis with topical antifungals and eventually oral terbinafine and oral antibiotics without improvement. Various topical steroids provided little improvement and he denied use of topical medications for acne. The patient's other medications at the time of evaluation were trazodone, quetiapine, sertraline and lisinopril. Exam was remarkable for erythematous plaques with collarettes of scale on the upper

chest and upper back, as well as generalized facial erythema without telangiectasias, pustules, or papules (Figure 1). A potassium hydroxide (KOH) stain was negative. A punch biopsy of the mid chest was performed and histopathology revealed a slight spongiotic dermatitis with a sparse superficial perivascular infiltrate and the presence of *Demodex* mites within the hair follicles (Figure 2). Periodic acid-Schiff (PAS) stain was negative for fungus. The patient was given two doses of ivermectin 200 µg/kg one week apart. The patient's rash resolved completely. At his four-month follow-up visit, he had no visible rash and no pruritus. Topical sulfur was recommended for treatment should his symptoms return.

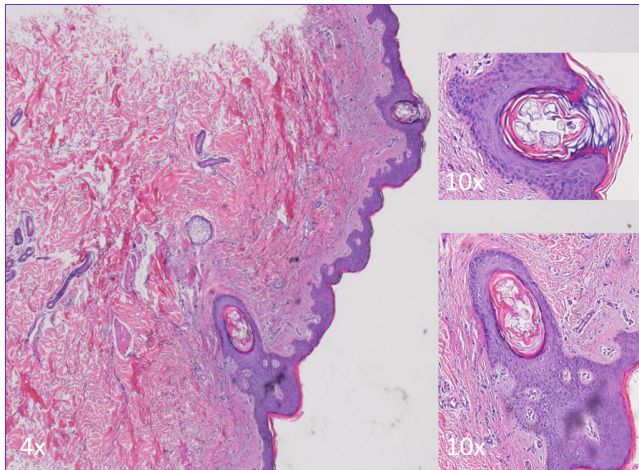
Eight months following his initial treatment, the patient experienced a mild recurrence of his symptoms. He was again prescribed a course of oral ivermectin and his rash resolved within a week.

SKIN

Figure 1. *Demodex* folliculitis before treatment with two doses of ivermectin 200 µg/kg 1 week apart and resolution. A. Generalized facial erythema and scale. B. Mid-chest with erythematous papules and pustules coalescing into plaques. C. Upper-mid back with erythematous papules and pustules coalescing into plaques. D&E. Resolution of *Demodex* folliculitis.

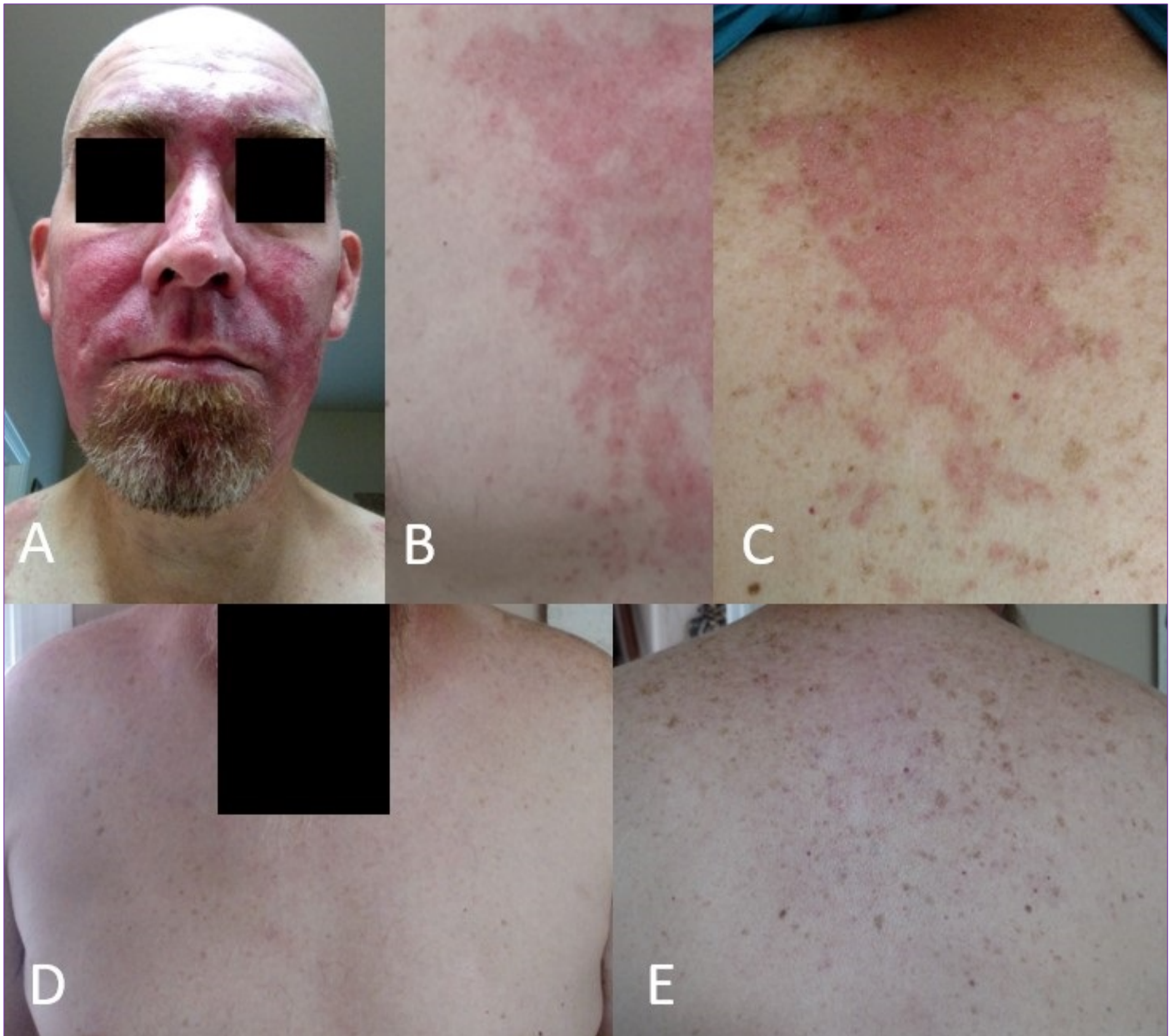

Figure 2. “Biopsy specimen demonstrating *Demodex* mites within two of two visible hair follicles.”



DISCUSSION

Demodex mites are a common inhabitant of normal human skin. Two species, *D. brevis* and *D. folliculorum*, have been identified.^{1, 2, 3}

It has been proposed that up to 80-90% of humans harbor the *Demodex* mite, which is usually found in the pilosebaceous unit of normal skin and can be found in all ages^{1, 4}. Roughly 10% of biopsies from normal skin will contain the *Demodex* mite¹. Adults are most commonly diagnosed with *Demodex* folliculitis and immunosuppression may contribute to cutaneous manifestations of the disease⁵.

Clinically, patients most commonly present with erythematous papules and pustules on hair bearing skin, usually on the face.^{1, 2} A KOH stain of affected skin will be positive for *Demodex* mites, but clinical correlation is necessary because of the high prevalence of *Demodex* mites in normal skin. Patients can be treated with topical medications such as permethrin or sulfur-containing preparations. Oral ivermectin as two 200 µg/kg doses one week apart can also be effective.^{6, 7} Other

treatments such as topical lindane & oral metronidazole have also been described.^{1, 2}

This case describes a symptomatic infestation with the *Demodex* mite below the head and neck. Interestingly, most evidence of follicular involvement on physical examination was confined to the trunk, with only erythema and telangiectasia present on exam of the head and neck. The patient's longstanding symptoms despite numerous treatment attempts with antifungals and anti-inflammatories, combined with the complete response to treatment with ivermectin, suggest that the finding of *Demodex* mites on biopsy was pathologic. This is further supported by our patient's mild recurrence that was easily treated with a second course of ivermectin.

Truncal *Demodex* has been reported in a small number of cases in the past.^{1, 2, 5, 8, 9} Increasing awareness of the possibility of symptomatic *Demodex* infestation below the head and neck can lead to more efficient diagnosis and treatment. The possibility of *Demodex* folliculitis should be considered in patients with a recalcitrant dermatitis without a clear etiology.

Conflict of Interest Disclosures:

Dr. Graham has received clinical research support from Pfizer and Octapharma. Dr. Graham is a consultant for UCB and has received an honorarium from the National Psoriasis Foundation.

Dr. Orłowski was active duty Air Force at the time of submission. The views expressed are those of the authors and are not to be construed as official or as representing those of the US Air Force or the Department of Defense. Dr. Orłowski was a full time federal employee at the time portions of this work were completed. They are in the public domain.

Dr. Reynolds has no conflicts of interest to declare.

Funding: None

Corresponding Author:

Timothy Jay Orlowski
 101 E Romana Street
 Apt 674
 Pensacola, FL 32502, USA
 Phone: 847-370-7347
 Email: torlowski13@gmail.com

References:

1. Elston, C. A., & Elston, D. M. (2014). Demodex mites. *Clinics in Dermatology*,32(6), 739-743.
2. Elston, D. M. (2010). Demodex mites: Facts and controversies. *Clinics in Dermatology*,28(5), 502-504.
3. Aylesworth, R., & Vance, J. C. (1982). Demodex folliculorum and Demodex brevis in cutaneous biopsies. *Journal of the American Academy of Dermatology*,7(5), 583-589.
4. Rusiecka-Ziółkowska, J., Nokiel, M., & Fleischer, M. (2014). Demodex – An Old Pathogen or a New One? *Advances in Clinical and Experimental Medicine*,23(2), 295-298.
5. Chen, C., Timerman, D., Finnin, C. Y., & Gallitano, S. M. (2018). Sparing of the scalp in severe Demodex folliculitis after stem cell transplantation. *JAAD Case Reports*,4(10), 1055-1058.
6. F., S., M., & S. (1998). Demodex folliculorum and topical treatment: Acaricidal action evaluated by standardized skin surface biopsy. *British Journal of Dermatology*,138(3), 461-466.
7. Salem, D. A., El-Shazly, A., Nabih, N., El-Bayoumy, Y., & Saleh, S. (2013). Evaluation of the efficacy of oral ivermectin in comparison with ivermectin–metronidazole combined therapy in the treatment of ocular and skin lesions of Demodex folliculorum. *International Journal of Infectious Diseases*,17(5).
8. Blondell, R.D. (1986). Truncal rashes associated with Demodex. *Journal of Family Practice*,23(4), 373-4.
9. Nakagawa, T., Sasaki, M., Fujita, K., Nishimoto, M., & Takaiwa, T. (1996). Demodex folliculitis on the trunk of a patient with mycosis fungoides. *Clinical and Experimental Dermatology*,21(2), 148-150.