

RISING DERM STARS

Prophylactic botulinum toxin in post-excisional scars: a randomized, doubleblinded, controlled clinical trial

Danielle P Dubin BA, Richard L Torbeck MD, Daniel M Bernstein MD, Matthew J Lin MD, Hooman Khorasani MD

Background: Excision of non-melanoma skin cancer on the face is usually curative, but the resultant scar in this cosmetically sensitive area may cause significant distress. Excessive wound tension may impair the healing process and lead to unsightly scars¹; therefore, one of the key principles in cutaneous surgery is to minimize wound tension. Botulinum toxin is utilized as a treatment for facial rhytids due to its ability to induce a chemical paralysis of the musculature². It has been hypothesized that it may also be used to minimize facial scars by paralyzing facial muscles, thereby leading to reduced wound tension.

Objective: To assess post-operative scar outcomes after administration of botulinum toxin at the time of excisional skin cancer surgery.

Methods: In this single center, single surgeon, double-blinded, prospective, randomized clinical trial, 25 Caucasian patients ≥ 18 years of age were randomized to receive either botulinum toxin injections or placebo injections of normal saline immediately following closure of skin cancer defects from Mohs Micrographic Surgery on the forehead. All defects underwent layered closure by a single dermatologic surgeon with thirteen years of surgical experience. Botulinum toxin (50 units) or saline (1 mL) were then injected in a standardized pattern

on the forehead (Figure 1). Wounds were dressed in a standardized manner with Mastitol®, Steri-Strips®, Telfa®, gauze, Hypafix® and cutaneous sutures were removed 7 days after surgery. The primary outcome was a blinded assessment of the scar six months after surgery with the modified Manchester Scar Scale (mMSS) and Visual Analog Scale (VAS). The study arms were compared using the Mann-Whitney U test. Two-tailed tests with a significance level of 5% were used.

Results: The placebo and botulinum toxin groups were similar in terms of age (mean of 57 and 59), gender (female:male ratio 5:6 and 5:9), smoking history (2 and 3 patients, respectively), autoimmune disorders (1 each), and scar location. There was no significant difference in mMSS scores between the study arms (median 10.00 and 10.15, $p = 0.79$). Similarly, there was no significant difference in the VAS scores (median values 3 and 3, $p = 0.87$). Analysis of subgroups stratified by age, gender, closure type, scar orientation, and sub-locations also failed to demonstrate a significant difference.

Conclusion: When administered at the time of wound closure, botulinum toxin does not significantly improve post-operative facial scar outcomes. Further studies are needed to determine the efficacy of prophylactic

December 2018 Volume 2 Supplemental Issue

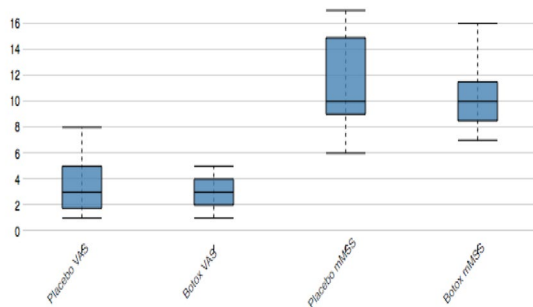
administration of botulinum toxin prior to wound closure, which may allow for maximum chemical paralysis of the facial musculature.

Figure 1: Standardized injection pattern for both study arms.



Oncology, vol. 18, no. 1, 1992, pp. 17-21.,
doi:10.1111/j.1524-4725.1992.tb03295.x

Figure 2: Box plot comparing VAS and mMSS for the placebo versus botulinum toxin study arms.



References:

References:

1. Meyer, M, and DA McGrouther. "A Study Relating Wound Tension to Scar Morphology in the Pre-Sternal Scar Using Langers Technique." *British Journal of Plastic Surgery*, vol. 44, no. 4, May 1991, pp. 291-294., doi:10.1016/0007-1226(91)90074-t.
2. Carruthers, Jean D.A., and J. Alastair Carruthers. "Treatment of Glabellar Frown Lines with C. Botulinum-A Exotoxin." *The Journal of Dermatologic Surgery and*