

## ORIGINAL RESEARCH

**Striae Cream with Regenetrol Complex™ Demonstrates Efficacy on Stretch Marks: A Double-Blind, Controlled Study**

Stephanie Moy BA<sup>a</sup>, Lawrence S. Moy MD<sup>b</sup>, Timothy Lesser BS<sup>c</sup>

<sup>a</sup>Ronald Reagan Medical Center

<sup>b</sup>Harbor UCLA Medical Center

<sup>c</sup>Torrance Memorial Medical Center

## ABSTRACT

This article reviews the efficacy of the first product that is specifically devoted to treating stretchmarks. Stretchmarks previously have been considered an untreatable cosmetic problem. Striae Cream with the Regenetrol Complex™ was studied in a double-blind controlled format in which the cream applied to one side of the body was compared with the control cream applied to the other side of the body after two months. The results demonstrate that 80% of the patients tested benefited from using the cream and 35% had marked clearing. Results could be seen within 4 weeks. The cream was successful for treating the ridging, redness, and whiteness associated with stretchmarks. Additionally, older and thicker stretchmarks demonstrated improvement with Regenetrol Complex™ application.

## INTRODUCTION

Stretchmarks, or striae, are a common problem that affects many men and women. Clinically, stretchmarks are characterized by a thinning of the skin in streaks usually located around the hips, thighs, buttocks, abdomen, and shoulders. The most common developments of stretchmarks occur during third trimester pregnancy (~40%), pubertal growth spurts or rapid weight gain (~30%), active weight training (~30%), and excessive use of topical cortisones.<sup>1,2</sup>

Stretchmarks from pregnancy are typically on the abdomen, hips, and thighs. Rapid growth rate stretchmarks in females occur along the sides of the hips, on the lateral breasts, and along the arms and legs on the extensor surfaces. Young men often develop horizontal, deep stretchmarks across the lower back. Weight change induced stretchmarks are usually seen around the trunk, the abdomen, and chest. Stretchmarks due to weight lifting are commonly around the shoulders and upper chest.

The streaks characteristics of stretchmarks are often erythematous, hypopigmented or hyperpigmented, and ridged. Lesions occur commonly in the presence of skin “stretching” and elevated hormone levels. While most of the symptoms are physical, patients with stretchmarks can experience psychological and emotional distress as well.<sup>3</sup>

Histopathologically, there is a marked thinning of all the skin layers and especially dramatic thinning of collagen fibers and other connective tissue. On electron microscopy, there is a breakdown and friable deterioration of the fibers in the region of the stretchmarks. Also, fibroblasts have the decreased amounts of endoplasmic reticulum and mitochondria characteristic of relatively low levels of protein synthetic activity.

Several articles discuss the use of various treatments as a way to eliminate stretchmarks. Some of the more involved procedures use lasers, micro-needles, microscopy, and pulsed light to solve the problem of stretchmarks. We are currently performing follow up studies involving electron microscopy and its efficacy on stretchmark removal. While fractionated microneedle radiofrequencies, lasers, and pulsed magnetic fields seem to be effective, some patients can still experience the continuing presence of stretchmarks after the procedure.<sup>4,5</sup> Although these procedures seem promising, many of them can be complex and out of the normal price range for most patients.

Other less involved procedures generally include the use of dermatological products, but many of them do not effectively remove the streaks seen in stretchmark development. Natural remedies and creams are available for use, but many are not

recommended for patients who are looking for a complete disappearance of their stretchmarks and further studies must be done on formulations that produce more significant results.<sup>6,7</sup>

While there seem to be many procedures available to patients with stretchmarks, many of these options have a limited effect on stretchmarks and a single clearly effective treatment has not yet been found.<sup>8,9</sup> This study investigates the efficacy of using Striae Cream with the Regenetrol Complex™ for the treatment of stretchmarks.

## METHODS

Healthy normal volunteers were recruited in several dermatologic clinic centers for the studies following Institutional Review Board approval. Forty patients were gathered who had significant stretch marks on the hips, abdomen, and thighs, which are generally the most common areas for stretchmarks appear. The patients had an average age of 37 years with a range of 16 to 47 years of age. Of the 40 patients, 29 had a positive history of stretch marks occurring during or immediately after pregnancy, seven had lesions from puberty growth periods and four had lesions from weight training.

Patients were instructed to apply the Striae Cream with Regenetrol Complex™ to the stretch marks twice per day. Application was done by taking a generous amount and rubbing thoroughly into the skin. A control cream was applied to one side of the body and the Striae Cream was applied to the other side. Both the evaluators and the patients were blinded as to which cream was the Striae Cream and which was the placebo.

The study lasted for two months, with evaluations at the beginning, after one month, and at the end of the study after two months. The evaluations were separated into different categories. First, the stretch marks were evaluated for specific characteristics, including erythema, hypopigmentation, hyperpigmentation, and ridging. The patients were also evaluated for extent of improvement over the one month and two-month time period. The evaluation was rated by 0--no change, 1--mild change, 2--moderate change, and 3--marked change.

As a separate portion of the study, a blinded evaluator examined the skin and was asked to choose the side that had improved based on the initial evaluations. The evaluator's chosen side was then compared to the actual treatment side versus the control side.

## RESULTS

The study evaluated the consequences of applying Striae Cream with Regenetrol Complex™ to the stretch marks on each patient. A majority of the patients (80%) had some measurable improvement in the appearance of their stretchmarks (Figure 1). Out of the 40 patients studied over the two-month period, 45% had mild improvement (18 patients), 25% had moderate improvement (10 patients), and 10% had marked improvement (4 patients). Figure 2 demonstrates the improvement in specific characteristics of the stretchmarks. Erythema and hypopigmentation improved the most dramatically with a 72% response, hyperpigmentation improved in 56% of the cases, and ridging improved in 44% of the cases. Figure 3 shows that the blinded evaluator was able to choose the correct, active cream in 19 out of 20 cases (95%).

The product showed positive benefits to all types of stretchmarks, independent of the cause of development. A Chi Square statistics test was performed to determine the significance of the results for improvements in the following categories: 'Overall', 'Redness', 'Hypopigmentation', 'Hyperpigmentation', and 'Ridging'. The total Chi Square values for were 5.154 for the product and 4.818 for the control, both for four degrees of freedom (Critical Value of 9.488 for  $p = 0.05$ ). There was no significant difference between improvements seen in any one category, though there were more improvements seen in general from the product side than the control side.

A Chi Squared test was also performed for the product's efficacy with the categories 'No Change', 'Mild Change', 'Moderate Change', and 'Marked Changed'. The Chi Square value for the product was 10.4 for three degrees of freedom (Critical Value of 9.348 for  $p = 0.025$ ) compared with the Chi Square value for the control, which was 71.8 for three degrees of freedom (Critical Value of 20.515 for  $p = 0.001$ ). There was a significant difference in the number of patients who categorized their improvements with the product as 'Mild Change', while there were fewer who observed no change in their stretch marks. The control cream showed a strong and significant difference in the number of patients who saw no change while there were very few patients who observed any improvement in their stretch marks.

Figures 4, 5, and 6 demonstrate the visual improvements of stretchmarks after 6 weeks using the Striae Cream with Regenetrol Complex™. Although some pigmentation remains, the overall appearance of the stretchmarks has significantly diminished.

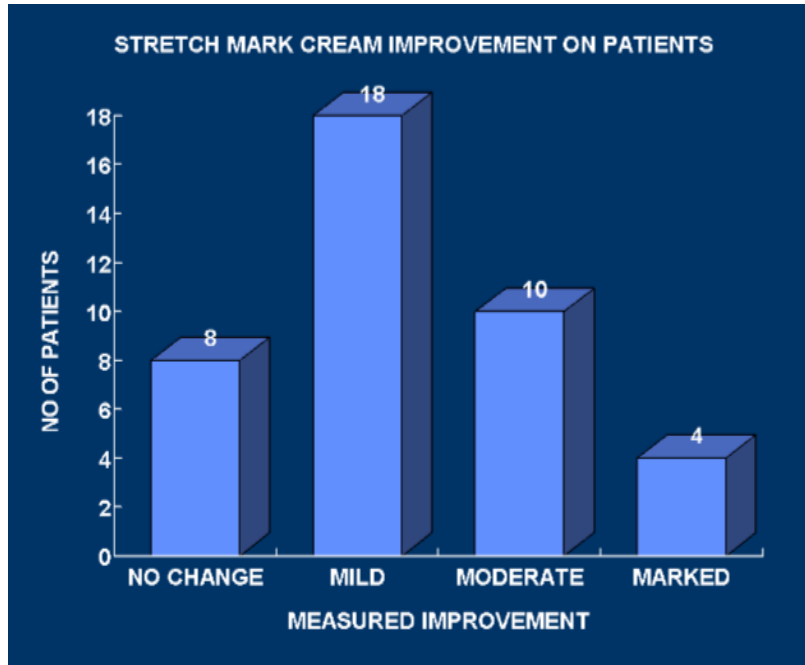


Figure 1. Stretchmark cream improvement on patients. Subjects (n=40) self-evaluated the improvement of their stretchmarks by categories: No Change, Mild, Moderate, and Marked. 8 participants showed no change in their stretchmarks, 18 showed mild changes, 10 showed moderate changes, and 4 showed marked changes.

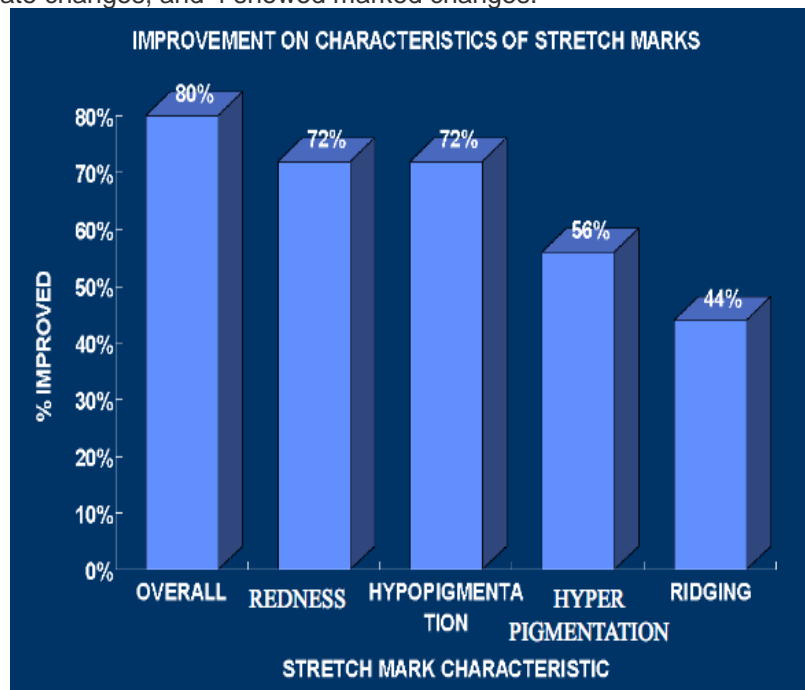
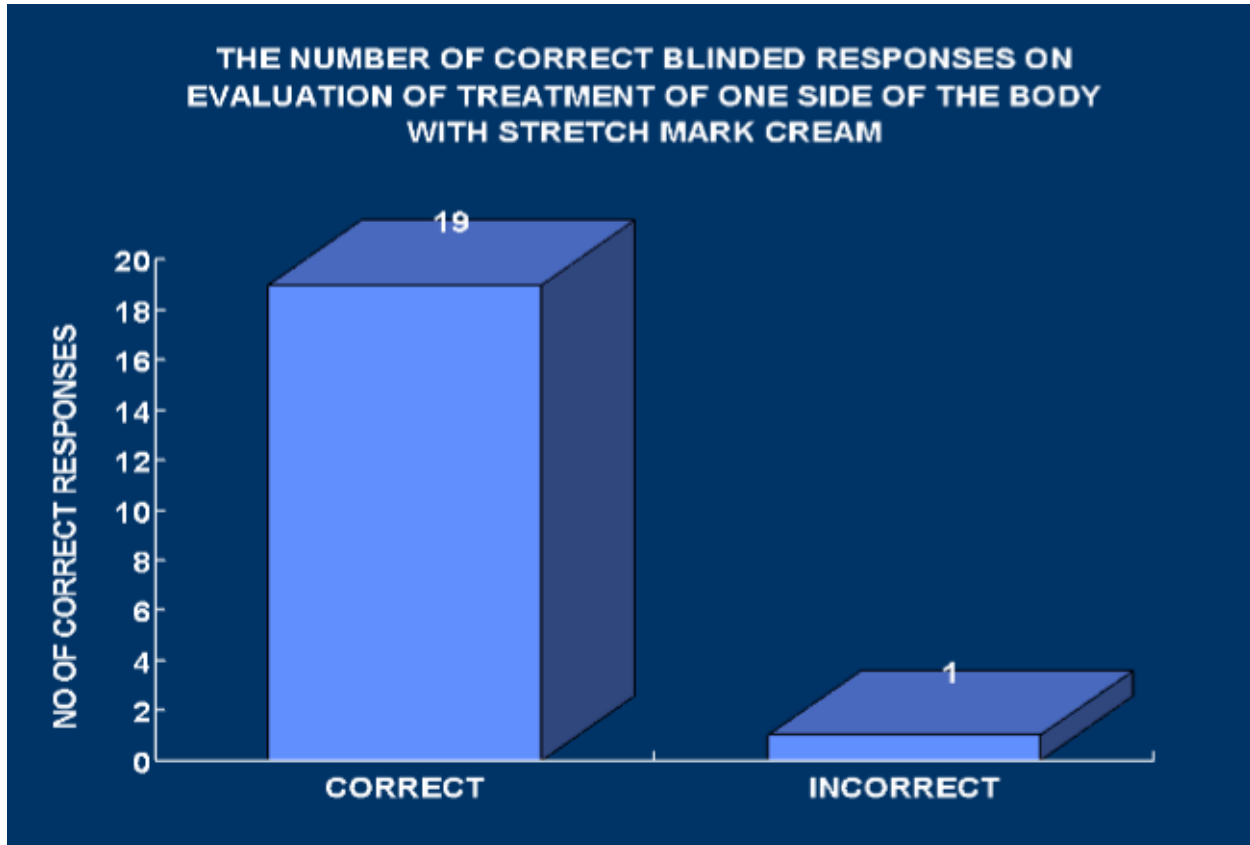


Figure 2. Improvement in characteristics of stretchmarks. Subjects (n=40) self-evaluated the characteristic changes of their stretchmarks, with 80% of subjects having an overall improvement in the quality of their stretchmarks. 72% of subjects saw a decrease in redness of their skin. 72% saw improvements in hypopigmentation. 72% saw improvements in hyperpigmentation. 44% saw a reduction in the amount of ridging of their stretchmarks.



**Figure 3.** The number of correct blinded responses on evaluation of treatment of one side of the body with stretch mark cream. Evaluations were made by a skin professional. In 19 out of the 20 cases, the physician was successfully able to identify on which side the Striae cream was applied.

## DISCUSSION

The study demonstrates the efficacy of a new product for treating stretchmarks. 80% of the patients showed an improvement in the appearance of their stretchmarks from use of the cream. Although many of the patients had mild to moderate effects, the results were promising because of the short duration of treatment (two months). Anecdotally, a number of patients had measurable improvement in two to four weeks and, in addition, many of the patients showed progressive, dramatic improvement with additional weeks of treatment.

The improvement of all the stretch mark characteristics from Figure 2

points to a specific action on stretch marks that can improve all facets of the lesions. In a very short two-month study, the lesions would be expected to improve most dramatically with respect to their erythema and hypopigmentation. The ridging effect would correlate with the deepest histologic effect and would continue to improve with continued therapy, but in two months would not be expected to be the most notable response.

The blinded evaluator response was performed to ensure the quality of the products and to ensure that the control cream was not producing similar results as

the active cream. Clearly, there is a visual difference that can be seen due to the clinical improvement that Regenetrol™ has on the skin.

Previous studies have initially shown promise with using topical retinoids for stretchmarks. However, a recent study demonstrated that tretinoin 0.025% cream was “ineffective in improving striae distensae in these subjects.”<sup>10</sup> The lack of consensus of tretinoin's efficacy may be due to possible irritant effects that occur with the product's use.<sup>11</sup> Other products have been reported in small studies to improve stretch marks. Centella asiatica may be effective, but it is a weak sensitizer. It is not clear if this product also works based on an irritant effect.

Limitations of this study include the small sample size, the narrow age range of participants, and the short duration of follow-up.

## CONCLUSION

Regenetrol™ appears to elevate the level of total protein synthesis. Preliminary laboratory studies have so far shown the elevated total protein synthesis to be correlated with an increase in collagen and elastin. As demonstrated, the histologic thickness of the epidermis and the dermis was markedly increased as well. The increase in total protein levels may explain the advantage Regenetrol™ has over other products tested at this time. As seen from a number of studies, all protein fibers, including keratin, collagen and elastin, were markedly decreased in people with striae distensae. Therefore, Regenetrol™ may give the most positive structural support for reversing the weakening of protein fibers associated with stretchmarks.

Although the study did not specifically examine the most responsive patient for Regenetrol™ treatment, anecdotal experience has shown that stretchmarks that are both older and newer can respond well; however, more recently developed stretchmark lesions appear to be more responsive. Additionally, stretchmarks from pregnancy and weight training appear to respond equally to the product. Responses to growth spurts were positive but efficacy was a little less. Anatomical areas did not appear to affect the effectiveness of the product. Perhaps the use of this product could be further enhanced with the addition of lasers or other forms of treatment.

**Conflict of Interest Disclosures:** The Striae Cream with Regenetrol Complex™ is manufactured and distributed by Dr. Lawrence Moy, M.D.

**Funding:** None

**Corresponding Author:**

Stephanie Moy, BA  
Address:  
1101 N Sepulveda Blvd  
Manhattan Beach, Ca 90266  
Phone: (310) 546-7780  
Email: moys@alumni.usc.edu

---

**References:**

1. Valente, D., Zanella, R., Doncatto, L., & Padoin, A. (2014). Incidence and Risk Factors of Striae Distensae Following Breast Augmentation Surgery: A Cohort Study. *PLoS ONE*.
2. Otman, Haley. "Stretch Mark Science: What Happens to Your Skin When Pregnancy Gives You a Stretch Mark?" *University of Michigan*. University of Michigan, Health System, 17 Nov. 2015. Web. 12 May 2016.

3. Korgavkar, K., & Wang, F. (2015). Stretch marks during pregnancy: A review of topical prevention. *Br J Dermatol British Journal of Dermatology*,606-615.
4. Dover, J., Rothaus, K., & Gold, M. (2014). Evaluation of safety and patient subjective efficacy of using radiofrequency and pulsed magnetic fields for the treatment of striae (stretch marks). *J Clin Aesthet Dermatol*.
5. Ryu, H., Kim, S., Jung, H., Ryoo, Y., Lee, K., & Cho, J. (2013). Clinical Improvement of Striae Distensae in Korean Patients Using a Combination of Fractionated Microneedle Radiofrequency and Fractional Carbon Dioxide Laser. *Dermatologic Surgery*.
6. Soltanipour, F., Delaram, M., Taavoni, S., & Haghani, H. (2014). The effect of olive oil and the Saj® cream in prevention of striae gravidarum: A randomized controlled clinical trial. *Complementary Therapies in Medicine*,220-225.
7. Ud-Din, S., D. McGeorge, and A. Bayat. "Result Filters." *National Center for Biotechnology Information*. U.S. National Library of Medicine, 20 Oct. 2015. Web. 12 Jan. 2016.
8. Sardana, K. (2014). Lasers for treating striae: An emergent need for better evidence. *Indian J Dermatol Venereol Leprol Indian Journal of Dermatology, Venereology, and Leprology*, 392-392.
9. Moore, J., Kelsberg, G., & Saphranek, S. (2012). Clinical Inquiry: Do any topical agents help prevent or reduce stretch marks? *J Fam Pract*.
10. Hexsel, D., Soirefmann, M., Porto, M., Schilling-Souza, J., Siega, C., & Dal'forno, T. (2014). Superficial Dermabrasion Versus Topical Tretinoin on Early Striae Distensae: A Randomized, Pilot Study. *Dermatologic Surgery*,537-544.
11. Black, Martin M., Christina M. Ambros-Rudolph, Libby Edwards, and Peter J. Lynch. "Ch 3: Physiologic Skin Changes of Pregnancy." *Obstetric and Gynecologic Dermatology*. London: Mosby, 2008. 24. Print.