

SHORT COMMUNICATION

An Eruption of Follicular Keratotic Spicules with Alopecia

Andrew S. Desrosiers MA^a, Anas Bernieh MD^b, Adam C. Byrd MD^c, Robert T. Brodell MD^c

^aUniversity of Mississippi School of Medicine, Jackson, MS

^bDepartment of Pathology, University of Mississippi Medical Center, Jackson, MS

^cDepartment of Dermatology, University of Mississippi Medical Center, Jackson, MS

CASE REPORT

A 62 year-old woman presented with hair loss on her scalp, face, neck, and arms for 2 years. The hair loss was associated with an initial red rash that persisted for several months, and then cleared. The hair loss persisted with dryness, flaking, and itching. There were no known aggravating or alleviating factors and no previous medical problems. The patient was taking no medications or supplements. Thyroid stimulating hormone (TSH) and antinuclear antibody (ANA) screen were negative. A physical examination revealed follicular keratotic papules and associated hair loss distributed throughout the scalp, post-auricular area, and posterior neck (Figure 1).

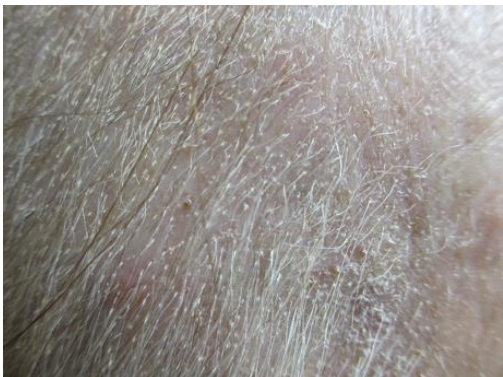

Figure 1. Follicular keratotic papules and associated hair loss on scalp of 62 year-old female.

A punch biopsy was performed (Figure 2). Pathologic examination of a punch biopsy specimen revealed hair follicles demonstrating spongiosis with reticular degeneration and mucin deposition that was confirmed with a colloidal iron stain with appropriate control. Surrounding mixed inflammation was noted including numerous eosinophils. There was neither lichenoid inflammation nor amyloid deposition. There were no mycosis cells, Pautrier microabscesses, or tagging of lymphocytes along the dermal-epidermal junction. Histological and clinical features were consistent with follicular mucinosis. Specific features of cutaneous T-cell lymphoma were not identified.

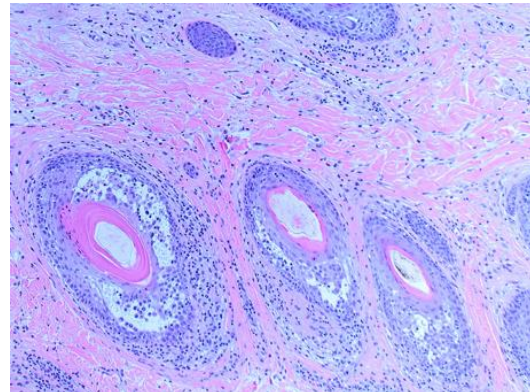


Figure 1. Punch biopsy revealing spongiosis with reticular degeneration and mucin deposition.

DISCUSSION

Follicular mucinosis (FM), also known as alopecia mucinosa, is an uncommon inflammatory disorder first described by Pinkus in 1957.¹ The condition tends to affect children and adults in the third and fourth decades of life.² There are two subsets of FM. Primary FM is an idiopathic and benign form presenting as an acute or subacute eruption in children or young adults manifesting as pink plaques of grouped follicular papules on the face or scalp associated with alopecia.³ Secondary FM is a chronic condition in older patients associated with atopic dermatitis or cutaneous T-cell lymphoma (particularly mycosis fungoides and Sézary syndrome) presenting with a generalized distribution of large plaques.⁴

There is no single reliable criterion for differentiating between primary and mycosis fungoides-associated FM. The primary form tends to be associated with younger patients, a solitary or smaller number of plaques, localization around the head and neck, and spontaneous resolution.² Some cases of primary FM may represent a more indolent, localized form of cutaneous T-cell lymphoma.⁵

For many cases of primary FM, spontaneous resolution occurs within 2-24 months. Watchful waiting is a reasonable course of action.² In some cases patients have benefited from corticosteroids, PUVA, dapsone, antimalarials, indomethacin, minocycline, isotretinoin, interferon- α -2b, orthovoltage irradiation, or UVA1 phototherapy.² For secondary FM, treatment should focus on the underlying T-cell lymphoma. In contrast to primary cicatricial alopecia, in which hair follicles are irreversibly destroyed and replaced by

fibrous tissue resolution of both types of FM is generally not accompanied by the formation of a true scar, allowing hair regeneration to occur.⁶

Conflict of Interest Disclosures: None

Funding: None

Corresponding Author:

Andrew Desrosiers, MA
2500 North State Street, Jackson, MS 39216
asdesrosiers@gmail.com

References:

1. Pinkus H, Macaulay W, Lund H, Delaney J, Anderson H, Hitch J. Alopecia mucinosa: Inflammatory plaques with alopecia characterized by root-sheath mucinosis. *Arch Dermatol.* 1957;76(4):419-426.
2. Bologna J, Jorizzo J, Schaffer J, eds. *Dermatology.* Philadelphia: Elsevier Saunders; 2008.
3. Brown HA, Gibson LE, Pujol RM, Lust JA, Pittelkow MR. Primary follicular mucinosis: Long-term follow-up of patients younger than 40 years with and without clonal T-cell receptor gene rearrangement. *J Am Acad Dermatol.* 2002;47(6):856-862.
4. Rongioletti F, De Lucchi S, Meyes D, et al. Follicular mucinosis: A clinicopathologic, histochemical, immunohistochemical and molecular study comparing the primary benign form and the mycosis fungoides-associated follicular mucinosis. *J Cutan Pathol.* 2010;37(1):15-19.

5. Cerroni L, Fink-Puches R, Bäck B, Kerl H. Follicular Mucinosis: A Critical Reappraisal of Clinicopathologic Features and Association with Mycosis Fungoides and Sézary Syndrome. *Arch Dermatol.* 2002;138:182-189.
6. Sellheyer K, Bergfeld WF. Histopathologic evaluation of alopecias. *Am J Dermatopathol.* 2006;28(3):236-259.