

## BRIEF ARTICLE

## Successful Treatment of Refractory Hailey-Hailey Disease with Dupilumab: A Case Report

Nikita Wong, MS<sup>1</sup>, Andrew D. King, MD, PhD<sup>2</sup>, Geoffrey A. Potts, MD<sup>2</sup>

<sup>1</sup>Wayne State University School of Medicine, Detroit, MI

<sup>2</sup>Department of Dermatology, Wayne State University, Detroit, MI

### ABSTRACT

**Introduction:** Hailey-Hailey disease (HHD) is an autosomal dominant blistering dermatosis with incomplete penetrance caused by an *ATP2C1* gene mutation. Currently, there is no cure for HHD; however therapeutic options aim to minimize the exacerbating factors and manage patients' symptoms.

**Case Report:** A 58-year-old male presented with a 10-year history of biopsy-proven HHD. He was seen consistently over the course of nine years with multiple flares a year consisting of pruritic and painful intertriginous plaques with involvement of the chest, upper arms, and back. His disease was recalcitrant to topicals, oral and topical antibiotics, phototherapy, and systemic corticosteroids. He was started on dupilumab and noticed significant improvement.

**Conclusion:** We present a case of HHD recalcitrant to various modalities of treatment. Our description of rapid improvement with dupilumab suggests a role for Th2 signaling in the pathophysiology of HHD. We propose that dupilumab works for HHD due to the significant skin barrier dysfunction, similar to atopic dermatitis, and consider whether inflammation plays an earlier role in the disease. Although used for an off-label purpose, in this case, further studies should assess the clinical response and safety of patients with recalcitrant HHD treated with dupilumab.

### INTRODUCTION

Hailey-Hailey disease (HHD) is an autosomal dominant blistering dermatosis with incomplete penetrance caused by an *ATP2C1* gene mutation.<sup>1</sup> This gene mutation affects calcium homeostasis due to a defect in the secretory pathway  $\text{Ca}^{2+}/\text{Mn}^{2+}$  ATPase (SPCA1) located in the Golgi apparatus (GA).<sup>1</sup> This plays a key role in the assembly of desmosomes in the epidermis and thus is responsible for the defective cell adhesion. HHD presents clinically as recurrent vesicles and erosions in intertriginous areas such as

the groin, axilla, neck, mammary folds, and perineum. Notably, maceration and superinfections are often frequently seen and can complicate the clinical presentation. Currently, there is no cure for HHD; however therapeutic options aim to minimize the exacerbating factors and manage patients' symptoms. In this case report, we discuss a relentless case of HHD and the role of dupilumab, a biologic monoclonal antibody in the management of the disease. Dupilumab was approved in 2017 by the US Food and Drug Administration (FDA) for the treatment of moderate to severe atopic dermatitis (AD),

March 2023 Volume 7 Issue 2

however, it has potential benefit for cutaneous disease beyond AD.

## CASE REPORT

A 58-year-old male presented with a 10-year history of biopsy-proven HHD. His mother presented in her 50s and his brother was also diagnosed with HHD. He was seen consistently over the course of nine years with multiple flares a year consisting of pruritic and painful intertriginous plaques with involvement of the chest, upper arms, and back.

He was initiated on numerous topicals including betamethasone valerate 0.1% ointment, fluocinonide 0.05% ointment, triamcinolone 0.1% ointment, tacrolimus 0.1% ointment, pimecrolimus 1% cream, calcipotriol 0.005% cream, benzoyl peroxide 5% gel, clindamycin 1% solution, mupirocin 2% ointment, and zinc oxide paste. He had also tried in-clinic phototherapy for more than 4 months, home phototherapy for years, systemic treatment with multiple courses of oral antibiotics including doxycycline, minocycline, and cephalexin for flares, low dose naltrexone 3mg nightly for 5 months, acitretin up to 30mg daily over 9 months, glycopyrrolate 1mg twice daily, and multiple courses of prednisone. His clinical course was also complicated by perianal condyloma acuminata and cutaneous staphylococcus aureus infections.

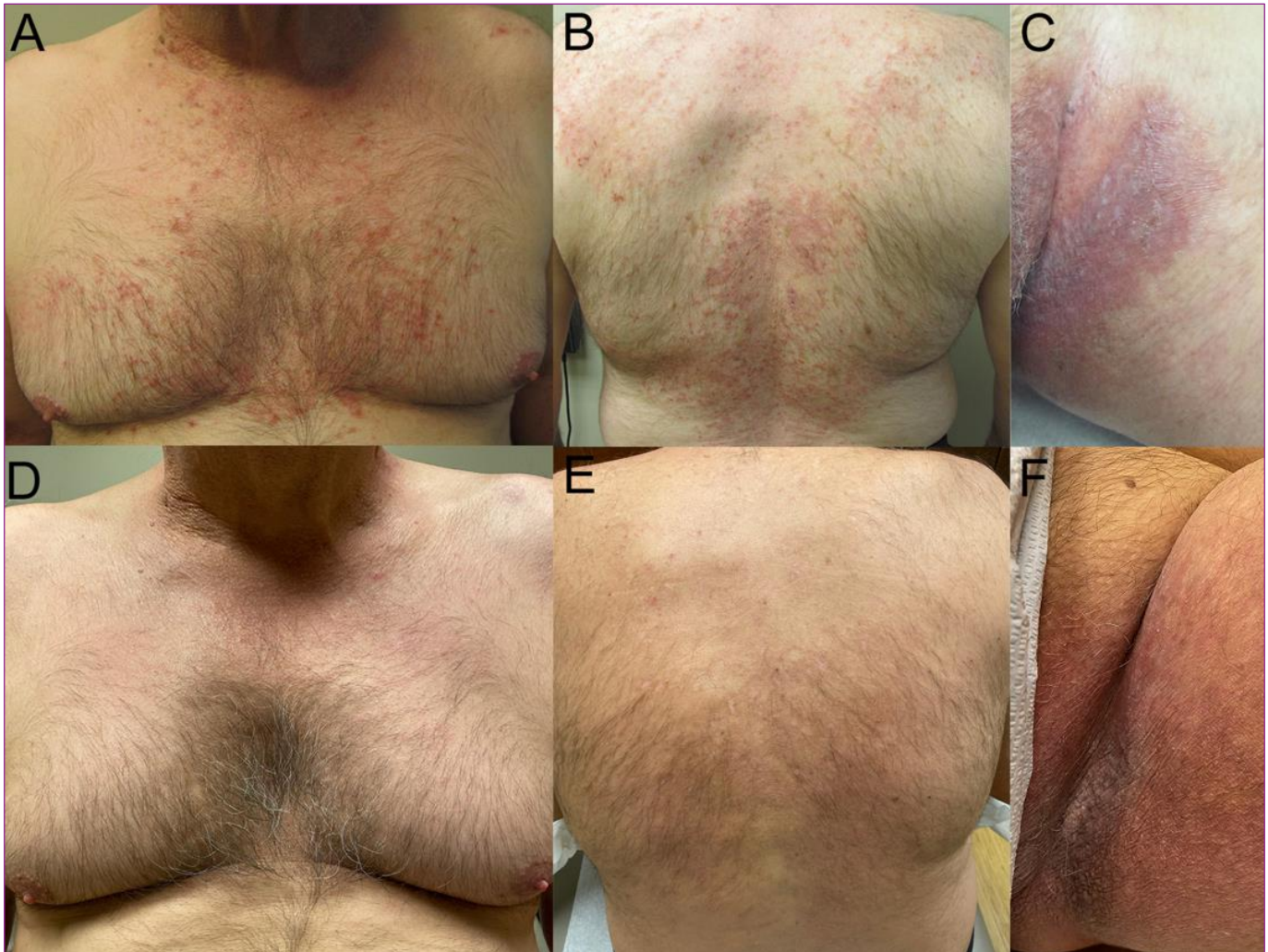
The most effective medications were topicals together with minocycline and prednisone tapers. However, minocycline was not tolerated due to cutaneous pigmentation in areas of HHD, and naltrexone was discontinued due to flaring of HHD with medication. The patient was started on dupilumab loaded with 600mg followed by 300mg every other week. By the first

maintenance dose, he subjectively endorsed 80% clearance of his skin. In his own words, “My skin felt different within 24 hours of taking the first application and I started to notice my skin clearing within three days. I am pain-free for the first time in many, many years.” Improvement remained on subsequent follow-up up to 10 months even with regular activity and sweating.

## DISCUSSION

HHD is caused by the loss of function of the *ATP2C1* gene which is responsible for the expression of  $\text{Ca}^{2+}/\text{Mn}^{2+}$  ATPase (SPCA1) necessary for  $\text{Ca}^{2+}$  trafficking and regulation.<sup>2</sup> Insufficient levels of SPCA1 affect the morphology of the Golgi apparatus (GA) resulting in defective intracellular signaling and post-transcriptional modifications.<sup>2</sup> The overall result is acantholysis as maintaining  $\text{Ca}^{2+}$  stores is vital for cell-cell adhesion. Dysregulated signaling events from the endoplasmic reticulum (ER) to the GA and beyond leads to chronic cellular stress. In turn, keratinocytes respond by producing pro-apoptotic states.<sup>3</sup> The role of the immune system in HHD has been suggested with early success through treatment with calcineurin inhibitors such as cyclosporine as described by Ormerod and Berth-Jones et al., and more recently topical tacrolimus suggesting the involvement of a T cell-dependent mechanism.<sup>4</sup> Notably, an analysis of untreated HHD lesions showed significant infiltration with T-lymphocytes that subsequently decreased after treatment with calcineurin inhibitors.<sup>5</sup> This further implies that immunomodulators may have a role in the pathogenesis of HHD.

Our description of rapid improvement with dupilumab suggests a role for Th2 signaling in the pathophysiology of HHD. Alzahrani et al.’s case series suggest a role for IL-4 and



**Figure 1.** Treatment of refractory Hailey-Hailey disease with dupilumab. Erosive vesicles coalescing into thin plaques on chest, back, and groin at baseline (A-C). Chest, back, and groin three months after treatment with dupilumab (D-F).

IL-13 in intracellular-calcium release via CCL26 and CCR3, an integral part of Th2 cell differentiation.<sup>6</sup> More recently, reports of significant improvement after treatment with dupilumab within a one-year follow-up period, further suggests that the inhibition of the IL-4 and IL-13 pathways may explain the effectiveness of dupilumab in treating HHD.<sup>7</sup> Alternatively, Licata et al suggest that the skin barrier defect and associated acantholysis seen in HHD promotes local inflammation thus making IL-4 a suitable target for dupilumab.<sup>8</sup>

## CONCLUSION

We propose that dupilumab works for HHD due to the significant skin barrier dysfunction, similar to atopic dermatitis, and consider whether inflammation plays an earlier role in the disease. Although used for an off-label purpose, in this case, further studies should assess the clinical response and safety of patients with recalcitrant HHD treated with dupilumab. Additional patient cases being reported may help this orphan disease in terms of insurance coverage and encourage more patients to seek care.

March 2023 Volume 7 Issue 2

**Acknowledgement:** The patient in this case report has provided written informed consent for publication of his case details.

**Conflict of Interest Disclosures:** None

**Funding:** None

**Corresponding Author:**

Geoffrey Potts, MD  
 Department of Dermatology  
 Wayne State University  
 18100 Oakwood Blvd, Suite 300  
 Dearborn, MI 48124  
 Email: gpotts@med.wayne.edu

- JEADV. Published online June 23, 2022.  
 doi:10.1111/jdv.18350.
8. Licata G, Buononato D, Calabrese G, et al. A case of Hailey-Hailey disease successfully treated with dupilumab. *Int J Dermatol*. Published online June 29, 2022. doi:10.1111/ijd.16322.

**References:**

1. Dhitavat J, Fairclough RJ, Hovnanian A, Burge SM. Calcium pumps and keratinocytes: lessons from Darier's disease and Hailey-Hailey disease. *Br J Dermatol*. 2004;150(5):821-828. doi:10.1111/j.1365-2133.2004.05904.x.
2. Micaroni M, Giacchetti G, Plebani R, Xiao GG, Federici L. ATP2C1 gene mutations in Hailey-Hailey disease and possible roles of SPCA1 isoforms in membrane trafficking. *Cell Death Dis*. 2016;7(6):e2259-e2259. doi:10.1038/cddis.2016.147.
3. Shull GE, Miller ML, Prasad V. Secretory Pathway Stress Responses as Possible Mechanisms of Disease Involving Golgi Ca<sup>2+</sup> Pump Dysfunction. *Biofactors Oxf Engl*. 2011;37(3):150-158. doi:10.1002/biof.141.
4. Rabeni EJ, Cunningham NM. Effective treatment of Hailey-Hailey disease with topical tacrolimus\*. *J Am Acad Dermatol*. 2002;47(5):797-798. doi:10.1067/mjd.2002.126217.
5. Tchernev G, Cardoso J. Familial benign chronic pemphigus (Hailey-Hailey Disease): use of topical immunomodulators as a modern treatment option. *Rev Médica Chile*. 2011;139:633-637. doi:10.4067/S0034-98872011000500011.
6. Alzahrani N, Grossman-Kranseler J, Swali R, et al. Hailey-Hailey disease treated with dupilumab: a case series. *Br J Dermatol*. 2021;185(3):680-682. doi:10.1111/bjd.20475.
7. Alamon-Reig F, Serra-García L, Bosch-Amate X, Riquelme-Mc Loughlin C, Mascaró JM. Dupilumab in Hailey-Hailey disease: A case series. *J Eur Acad Dermatol Venereol*