

BRIEF ARTICLE

Calcipotriene 0.005%/Betamethasone Dipropionate 0.064% Foam as a Treatment for Nail Psoriasis: A Case Series

Shifa Akhtar¹, BS, Mariana Perez¹, BA, Jessica Sharma¹, BS, Agnese Canazza², Martin Zaiac^{1,2}, MD

¹ Florida International University, Herbert Wertheim College of Medicine, Miami, FL

² Greater Miami Skin and Laser Center, Mount Sinai Medical Center, Miami Beach, FL

ABSTRACT

Combination topical corticosteroids and vitamin D analog treatments for nail psoriasis are widely used in cream and ointment vehicles, but patients may prefer a foam vehicle due to ease of application and favorable cosmetic appearance. Calcipotriene 0.005%/betamethasone dipropionate 0.064% (Cal/BD) aerosol foam is an FDA approved therapy for plaque psoriasis, but may also be an effective treatment for nail psoriasis in a novel aerosol foam. We present a case series of 3 patients with mild to moderate nail psoriasis who responded positively to treatment with Cal/BD aerosol foam applied 1-2 times daily to affected nails for at least 6 weeks. Reduction of nail plate surface abnormalities and inflammation of the nail folds were assessed with clinical evaluation and dermoscopy, and documented with serial photography. While further research on the efficacy and safety of Cal/BD aerosol foam as a treatment for nail psoriasis is needed, this report suggests its potential as a combination topical vitamin D analogue and high potency steroid in a foam vehicle.

INTRODUCTION

An estimated 80-90% of psoriasis patients develop nail involvement, leading to decreased quality of life secondary to pain, activity restriction, and an increased risk of anxiety and depression.¹ Historically, topical treatments for nail psoriasis have been considered less effective due to limited penetration through the psoriatic nail plate and prolonged duration of use leading to poor patient adherence.² While systemic approaches with newer biologic agents have demonstrated efficacy in the treatment of moderate to severe nail psoriasis, patients with disease limited to the nail may be reluctant to use systemic biologic agents as opposed to topical agents. Though combined approaches with topical vitamin D analogues

and steroids as creams and ointments have been well-documented as effective treatments for mild psoriasis of the nail, there is minimal literature regarding the use and efficacy of calcipotriene/betamethasone dipropionate in a foam vehicle.^{3,4} Calcipotriene 0.005%/betamethasone dipropionate 0.064% (Cal/BD) aerosol foam is indicated for the treatment of plaque psoriasis; we report our experience utilizing it as a treatment for psoriasis of the nail.

CASE SERIES

Three patients were evaluated in the dermatology clinic for psoriasis of the nail and treated with Cal/BD aerosol foam, resulting in positive clinical outcomes.

Case 1:

A 42-year-old male presented with adult-onset, mild changes in nail appearance and texture. Physical exam showed pitting in the left small fingernail, right thumbnail, and right index fingernail plates. A diagnosis of psoriasis of the nail was established, and global/microscopic pictures (executed with FotoFinder medicam dermoscopy) were obtained to document the nail changes at baseline (Fig 1, A). The patient was subsequently prescribed daily Cal/BD aerosol foam. On five- and ten-month follow-up exams, dermoscopy demonstrated a decrease in nail pits and an improvement of nail plate surface abnormalities (Fig 1, B, C).

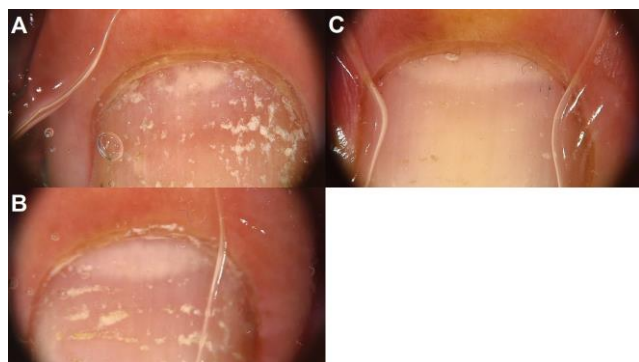

Figure 1. Case 1 **A)** Before treatment **B)** Progressive improvement after five **C)** and ten months of treatment

Case 2:

A 60-year-old female, diagnosed by her previous physician with onychomycosis of the thumb and toenails and treated with terbinafine and efinaconazole for three months, presented to our clinic due to a lack of improvement. Exam demonstrated dystrophic nails involving multiple nail plates. Unilateral curvature of the nail plate, onycholysis, and keratosis of the nail bed were all present (Fig 2, A). Dermoscopy demonstrated nail pitting, erythematous borders, and splinter hemorrhages in the distal nail bed (Fig 2, B, C, D). Terbinafine and efinaconazole were discontinued, and

the patient was started on daily Cal/BD aerosol foam for treatment of nail psoriasis. At six-week follow-up, she noted improved nail appearance but continued to complain of mild to moderate onychodystrophy and discomfort (Fig 2, E). Dermoscopy demonstrated a decrease in psoriatic pits, nail scaling, and erythematous borders (Fig 2, F, G, H). Cal/BD aerosol foam was increased to a twice daily application regimen with enhanced success.

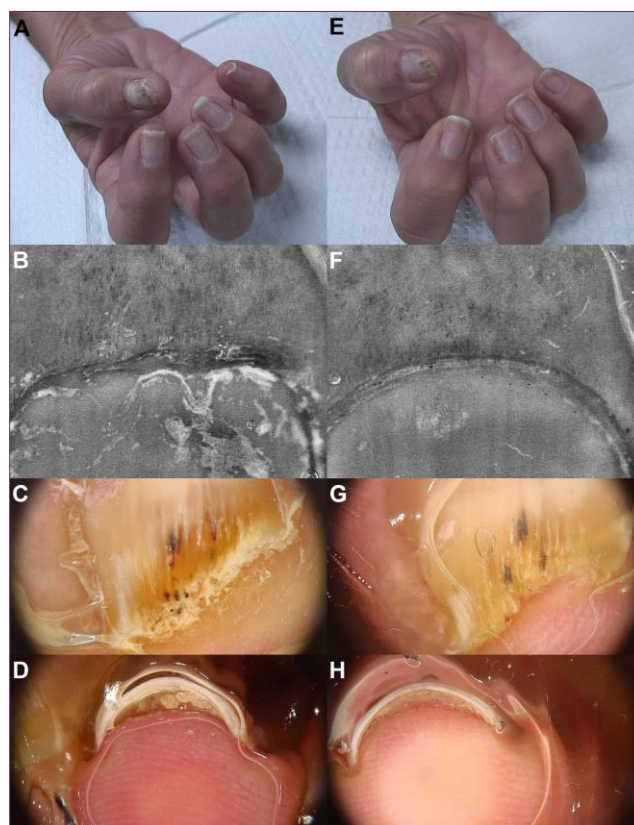


Figure 2 Case 2 **A, B, C, D)** Before treatment **E, F, G, H)** Marked improvement after six weeks of treatment

Case 3:

A 47-year-old female with a history of plaque psoriasis presented to our clinic with mild to moderate discoloration and pitting of the right thumbnail and left small fingernail plates for the past year. Physical exam demonstrated pitting and crumbling of the right thumbnail

and left small fingernail plates (Fig 3, A). Dermoscopy of the right thumbnail plate showed leukonychia, irregular thickening, salmon patches, and hyperkeratosis of the cuticle (Fig 3 B, C). The patient was followed by Rheumatology and pending initiation of a new biologic agent at the time of the visit, having discontinued apremilast due to gastrointestinal side effects. She was given Cal/BD aerosol foam to be applied topically to the affected nails twice daily. At four-month follow-up, the patient was being treated with adalimumab and Cal/BD aerosol foam and noted improvement in nail appearance (Fig 3, D). Dermoscopy demonstrated reduced inflammation in the posterior nail folds as well as decreased nail pitting in the re-growing nails (Fig 3, E, F).

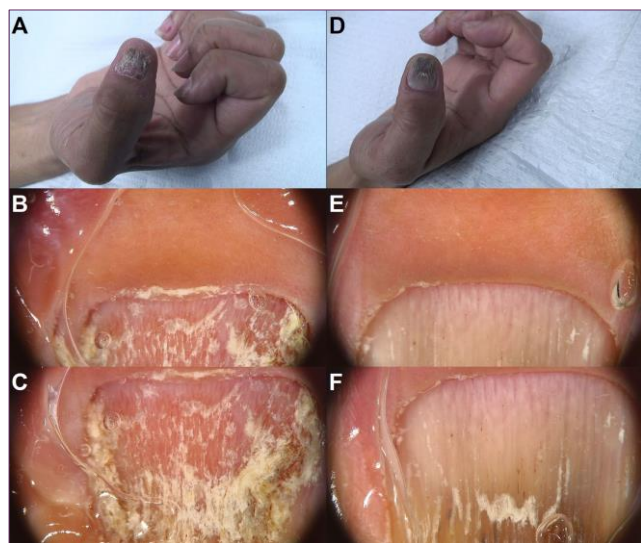


Figure 3. A, B, C) Before treatment D, E, F) Improvement after four months of treatment

DISCUSSION

For the treatment of mild nail psoriasis, topical/intralesional corticosteroid monotherapy, topical vitamin D analog monotherapy, or combination therapy is commonly recommended. Vitamin D is understood to exhibit immunomodulatory and

antiproliferative effects, while corticosteroids exhibit anti-inflammatory effects, thus working synergistically when combined.⁵ The use of different vehicles aside from ointment in the topical treatment of nail psoriasis have been explored. Eight percent clobetasol-17-propionate in a colorless nail lacquer vehicle has produced favorable results, with one study of 15 patients demonstrating a reduction in nail alterations and in the modified Psoriasis Severity Index by 78% compared to baseline.⁶ There are also case reports of refractory nail psoriasis treated successfully with Cal/BD gel, with authors hypothesizing that the low viscosity of the lipophilic gel may reach the subungual gap and the gap beneath the proximal nail folds in affected nails.⁷

While topical therapies combining a corticosteroid and vitamin D analog are established treatments for nail psoriasis, there is scarce literature regarding the use of Cal/BD aerosol foam. Traditionally, ointments were the vehicle of choice, but the rising popularity of different formulations including creams, lotions, nail lacquers, and foams has provided more options for patients and clinicians. While patient adherence to treatment is essential in the successful management of psoriasis, around 40% of psoriasis patients report poor adherence to topical regimens and report that both psoriasis and its treatment interfere with their quality of life.⁸ Notably, patients prefer foam vehicle solutions over creams, gels, and ointments for psoriasis treatment.⁹ Therefore, substitution of the traditional ointment with a foam vehicle may improve adherence and subsequently result in greater positive patient outcomes, but further investigation is needed. The efficacy and safety of Cal/BD foam for plaque psoriasis has been established, with randomized control trials demonstrating tolerability and increased remission time.¹⁰ A preliminary study of

Cal/BD in foam formulation for the treatment of nail psoriasis demonstrated it was well-tolerated and lacked steroid-related adverse reactions, but larger clinical trials are underway to better establish its efficacy and tolerability for this indication.¹¹

CONCLUSION

Our case series demonstrates the potential of Cal/BD aerosol foam as a treatment for nail psoriasis. This can be a desirable option for patients with contraindications to systemic therapy or a preference for topical therapy in a foam vehicle. Further investigation with an adequate sample of patients should be undertaken to better determine its side effects and efficacy.

Conflict of Interest Disclosures: None

Funding: None

Corresponding Author:

Shifa Akhtar, BS
Florida International University
Herbert Wertheim College of Medicine
11200 SW 8th St, AHC-2
Miami, FL, 33199 USA
Phone: (305) 348-0570
Email: sakht008@med.fiu.edu

References:

- de Jong EM, Seegers BA, Gulink MK, Boezeman JB, van de Kerkhof PC. Psoriasis of the nails associated with disability in a large number of patients: results of a recent interview with 1,728 patients. *Dermatology*. 1996;193(4):300-3. doi:10.1159/000246274
- Rigopoulos D, Baran R, Chiheb S, et al. Recommendations for the definition, evaluation, and treatment of nail psoriasis in adult patients with no or mild skin psoriasis: A dermatologist and nail expert group consensus. *J Am Acad Dermatol*. Jul 2019;81(1):228-240. doi:10.1016/j.jaad.2019.01.072
- Rigopoulos D, Gregoriou S, Daniel Iii CR, et al. Treatment of nail psoriasis with a two-compound formulation of calcipotriol plus betamethasone dipropionate ointment. *Dermatology*. 2009;218(4):338-41. doi:10.1159/000202179
- Rigopoulos D, Ioannides D, Prastitis N, Katsambas A. Nail psoriasis: a combined treatment using calcipotriol cream and clobetasol propionate cream. *Acta Derm Venereol*. 2002;82(2):140. doi:10.1080/00015550252948220
- Tan ES, Chong WS, Tey HL. Nail psoriasis: a review. *Am J Clin Dermatol*. Dec 1 2012;13(6):375-88. doi:10.2165/11597000-000000000-00000
- Sánchez Regaña M, Márquez Balbás G, Umberto Millet P. Nail psoriasis: a combined treatment with 8% clobetasol nail lacquer and tacalcitol ointment. *J Eur Acad Dermatol Venereol*. Aug 2008;22(8):963-9. doi:10.1111/j.1468-3083.2008.02679.x
- Takama H, Ando Y, Yanagishita T, Ohshima Y, Akiyama M, Watanabe D. Two cases of refractory nail psoriasis successfully treated with calcipotriol plus betamethasone dipropionate gel. *J Dermatol*. May 2020;47(5):e211-e213. doi:10.1111/1346-8138.15314
- Richards HL, Fortune DG, O'Sullivan TM, Main CJ, Griffiths CE. Patients with psoriasis and their compliance with medication. *J Am Acad Dermatol*. Oct 1999;41(4):581-3.
- Housman TS, Mellen BG, Rapp SR, Fleischer AB, Jr., Feldman SR. Patients with psoriasis prefer solution and foam vehicles: a quantitative assessment of vehicle preference. *Cutis*. Dec 2002;70(6):327-32.
- Lebwohl M, Kircik L, Lacour JP, et al. Twice-weekly topical calcipotriene/betamethasone dipropionate foam as proactive management of plaque psoriasis increases time in remission and is well tolerated over 52 weeks (PSO-LONG trial). *J Am Acad Dermatol*. May 2021;84(5):1269-1277. doi:10.1016/j.jaad.2020.09.037
- Gregoriou S, Sidiropoulou P, Tsimpidakis A, et al. Treatment of nail psoriasis with calcipotriol/betamethasone dipropionate foam versus pulse dye laser: an unblinded, intra-patient, left-to-right prospective study. *J Eur Acad Dermatol Venereol*. Sep 2020;34(9):e519-e520. doi:10.1111/jdv.16426