

BRIEF ARTICLE

Cutaneous Endometriosis: A Case ReportAlan Wong, BS¹; Stefanie Altmann, DO²; Karthik Krishnamurthy, DO²¹Lake Erie College of Osteopathic Medicine, Bradenton, FL²Orange Park Medical Center, Division of Dermatology, Orange Park, FL**ABSTRACT**

Cutaneous endometriosis (CEM) is a rare disease characterized by endometrial glands and/or stroma in the skin. Lesions present as a firm papule or nodule and can be blue, violaceous, red, brown or skin-colored. Patients frequently report cyclical tenderness, swelling and bleeding at the site of the lesion related to their menstrual cycle. CEM presents a diagnostic challenge as lesions are commonly mistaken for a keloid, dermatofibroma, dermatofibrosarcoma protuberans, melanoma or cutaneous metastasis of cancer (e.g., Sister Mary Joseph nodule). A biopsy must be taken to rule out malignancy and treatments include surgical excision and hormonal agents. To our knowledge, just over 100 cases have been reported in the literature. Herein we highlight a case of CEM in a 43-year-old female that presented to dermatology after being overlooked on prior work-up with obstetrics and gynecology. This case highlights the need for dermatologists to be familiar with CEM, as we may be the first clinicians these patients present to for painful cutaneous lesions.

INTRODUCTION

Cutaneous endometriosis (CEM) is defined as the presence of endometrial glands and/or stroma in the dermis or subcutis.^{1,2} CEM primarily affects women of reproductive age and represents 0.5-1% of all ectopic endometriosis.^{2,3} CEM can be classified as primary or secondary, with primary CEM accounting for less than 30% of all cases.¹ The cause of primary CEM is unclear and occurs spontaneously. Although risk factors for developing primary CEM are not clearly defined, age and hormone levels likely play a role since a majority of affected individuals are premenopausal.^{1,2} Secondary CEM, also called scar endometriosis, is believed to occur due to seeding/iatrogenic implantation of endometrial tissue into the skin during abdominopelvic surgeries.^{1,2}

Clinically, CEM presents as a firm papule or nodule averaging 2 cm in diameter. Lesions may be blue, violaceous, red, brown or skin-colored.¹ Patients with CEM usually experience pain, swelling, itching, or bleeding from affected areas of the skin in a cyclical pattern related to the menstrual cycle. The most common location for both primary and secondary CEM is the umbilicus.^{1,2} Other locations for CEM include abdominopelvic scars, episiotomy wounds, and upper extremities.² Diagnosis must be confirmed via histopathologic examination, and treatment options include surgical excision or hormonal therapy.¹

Since symptoms of CEM are limited to the skin and not all women have associated pelvic endometriosis,^{1,2} dermatologists may be the first clinicians that see patients with CEM. As such, it is important for

dermatologists to be able to recognize the characteristic clinical and histologic features of CEM and obtain a thorough history, physical and workup to aid in the diagnosis and guide management.

CASE PRESENTATION

A 43-year-old female presented with a bluish, 1.5 cm fluctuant and tender nodule on the umbilicus that had been present for approximately six months (Figure 1). Upon further questioning, she reported that the lesion was more painful with menstruation and occasionally bled. She also reported a distant surgical history of cesarean section, laparoscopic appendectomy, and umbilical repair. She was evaluated by obstetrics and gynecology for pelvic pain two months prior, and was diagnosed with pelvic endometriosis; however, the umbilical nodule was not evaluated at that time. A 4-mm punch biopsy was performed in our clinic for further evaluation. Histopathology showed endometrial glands and stroma with extravasated red blood cells, consistent with CEM (Figures 2, 3). No signs of atypia or malignancy were observed. Due to the patient's history of cesarean section, the lesion was classified as secondary CEM. The patient was referred to obstetrics and gynecology for surgical excision.

DISCUSSION

CEM presents a diagnostic challenge as lesions are commonly mistaken for keloid, dermatofibroma, dermatofibrosarcoma protuberans, melanoma or cutaneous metastasis of cancer (e.g., Sister Mary Joseph nodule).¹⁻⁵ As studies have shown that 14% of women with CEM in gynecological scars have associated pelvic

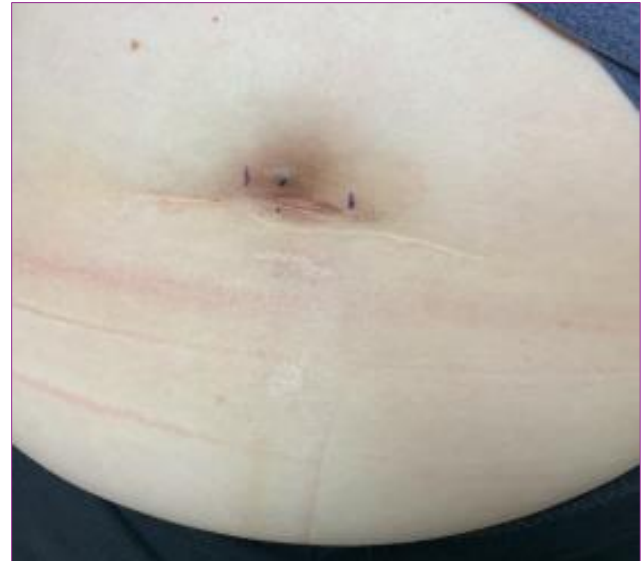

Figure 1. Solitary 1.5-cm bluish nodule at the umbilicus

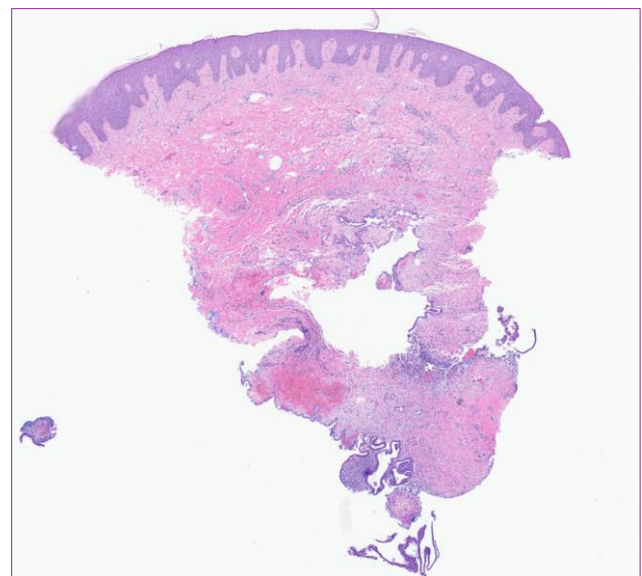


Figure 2. Histopathology showing endometrial glands lined with columnar epithelium, endometrial stroma with dense spindle cells shaped cells, and extravasated red blood cells (H&E, 2x)

endometriosis,⁴ a majority of patients with CEM may present with cutaneous manifestations alone. Thus, dermatologists may be the first clinicians these patients elect to see, and it is crucial to be able to recognize the salient features of CEM.

The cyclical symptoms associated with CEM, is one of the most important clinical features. The pain, swelling and/or bleeding usually correspond with the patient's menstrual cycle and should increase suspicion for CEM. Obtaining a thorough surgical history is also key as it will help classify the lesion as primary or secondary CEM. Patients should also be offered a referral to gynecology if they desire to be evaluated for pelvic endometriosis or have symptoms such as dysmenorrhea or pelvic pain.^{1,2}

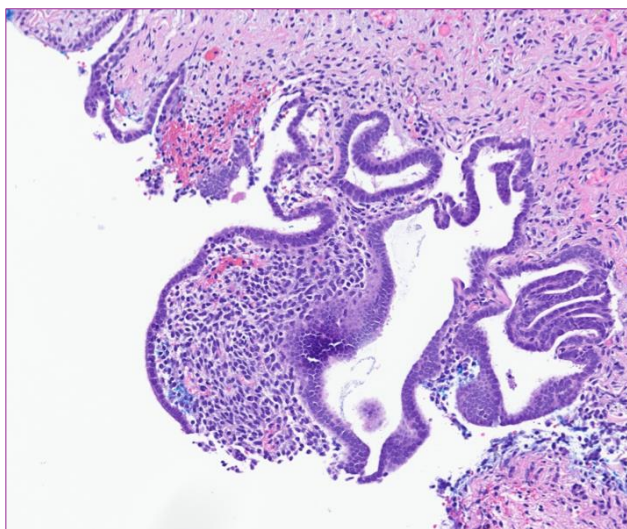


Figure 3. Histopathology showing endometrial glands lined with columnar epithelium, endometrial stroma with dense spindle cells, and extravasated red blood cells (H&E, 20x)

Diagnosis of CEM can be made with either punch or excisional biopsy.¹⁻³ An abdominal ultrasound should be obtained prior to the biopsy if there is a high suspicion for uterocutaneous fistula.^{1,2} In our case, the lesion was well circumscribed with no palpable deep component, and outside any surgical scars, therefore pre-procedure imaging was not obtained prior to biopsy. Of note, excisional biopsy with 1 cm margins is both diagnostic and curative in cases of scar endometriosis.⁴ However, some authors prefer to use 2 mm margins, especially since

the risk of recurrence in relation to surgical margins has not been officially determined.⁵

Histologically, CEM is characterized by three features: endometrial glands composed of columnar epithelium, endometrial stroma characterized by dense spindle shaped cells, and hemorrhage. The tissue must be evaluated for atypia/dysplasia to rule out malignancy. Interestingly, lesions may have marked decidual changes and can mimic a malignant process.⁶ Although it is often not performed in practice, immunohistochemistry can help confirm the diagnosis; endometrial glands frequently stain positive for CD7, estrogen receptors and progesterone receptors.³ The stroma is often strongly positive for CD10.³ Notably, CD10 is particularly helpful if there is a paucity of glands and abundance of stroma in lesions.³ Also, since CD7 stains positively in > 95% of primary endometrial adenoid tumors, it can help distinguish CEM from primary metastatic tumors.³

Finally, the patient should be educated on surgical and hormonal treatment options. Surgical excision with wide margins is considered first line treatment.^{1,2} Perioperative recommendations vary and include performing surgery at the end of the menstrual cycle, as lesions are generally smaller. Adjuvant treatment with preoperative hormonal agents may help to shrink the lesion and reduce symptoms. Additionally, postoperative use of hormonal agents to prevent recurrence could be considered.¹ Prognosis is favorable as recurrence following wide excision is rare.¹⁻⁵ Hormonal therapies include leuprolide, danazol and oral contraceptives, and can be used as monotherapy for patients who do not wish to undergo surgery.^{1,2} Although hormonal treatments can provide symptomatic relief, they are associated with numerous side effects and symptoms of

CEM can return once therapy is discontinued.¹ In the event patients opt for hormonal therapy alone, regular surveillance with histopathology should be considered as there have been reports of malignant transformation in the literature.¹ Overall, malignant transformation of CEM is rare and is estimated to occur in 0.3-1% of secondary CEM cases.⁷ Associated risk factors include advanced age, postmenopausal status, delayed or incomplete excision, clinical recurrence, and endometriotic lesions > 9 cm in diameter.⁷

CONCLUSION

Recognizing CEM is important for dermatologists as we may be the first clinicians to see these patients. CEM presents as a firm, blue/violaceous/brown/red/skin-colored papule or nodule. Cyclical pain, swelling or bleeding relating to the menstrual cycle should arise suspicion in favor of CEM, particularly if the lesion originated at a surgical scar from an abdominopelvic procedure. CEM requires a biopsy to ensure the correct diagnosis and to rule out malignancy. Definitive treatment is surgical excision with wide margins and recurrence after surgery is rare.

Conflict of Interest Disclosures: None

Funding: This research was supported in part by HCA Healthcare or an HCA Healthcare affiliated entity. The views expressed in this publication represent those of the authors and do not necessarily represent the official views of HCA Healthcare or any of its affiliated entities.

Corresponding Author:

Stefanie Altmann, DO
 Division of Dermatology
 Orange Park Medical Center
 2001 Kingsley Ave
 Orange Park, FL 32073
 Phone: 407-414-6556
 Email: Stefanie.altmann@hcahealthcare.com

References:

1. Sharma A, Apostol R. Cutaneous Endometriosis. In: *StatPearls*. Treasure Island (FL): StatPearls Publishing; August 8, 2020.
2. Raffi L, Suresh R, McCalmont TH, Twigg AR. Cutaneous endometriosis. *Int J Womens Dermatol*. 2019;5(5):384-386. Published 2019 Jul 2. doi:10.1016/j.ijwd.2019.06.025
3. Ojong O, Susa J, Weiss E. A solitary brown nodule on the umbilicus. *JAAD Case Rep*. 2020;6(10):1024-1026. Published 2020 Aug 14. doi:10.1016/j.jdc.2020.08.010
4. Tatli F, Gozeneli O, Uyanikoglu H, et al. The clinical characteristics and surgical approach of scar endometriosis: A case series of 14 women. *Bosn J Basic Med Sci*. 2018;18(3):275-278. Published 2018 Aug 1. doi:10.17305/bjbms.2018.2659
5. Din AH, Verjee LS, Griffiths MA. Cutaneous endometriosis: a plastic surgery perspective. *J Plast Reconstr Aesthet Surg*. 2013;66(1):129-130. doi:10.1016/j.bjps.2012.05.012
6. DeClerck BK, Post MD, Wisell JA. Cutaneous decidualized endometriosis in a nonpregnant female: a potential pseudomalignancy. *Am J Dermatopathol*. 2012;34(5):541-543. doi:10.1097/DAD.0b013e3182473172
7. Fargas Fàbregas F, Cusidó Guimferrer M, Tresserra Casas F, Baulies Caballero S, Fàbregas Xauradó R. Malignant transformation of abdominal wall endometriosis with lymph node metastasis: Case report and review of literature. *Gynecol Oncol Case Rep*. 2014;8:10-13. Published 2014 Jan 5. doi:10.1016/j.gynor.2013.12.003