

Complete Response of Primary Penile Tumor With Induction Paclitaxel, Ifosfamide, and Cisplatin (TIP) Chemotherapy

Logan Zemp,^{✉1} Jad Chahoud,¹ Peter A. Johnstone,² Philippe E. Spiess¹

¹Department of Genitourinary Oncology, H. Lee Moffitt Cancer Center & Research Institute, Tampa, United States

²Department of Radiation Oncology, H. Lee Moffitt Cancer Center & Research Institute, Tampa, United States

The patient was a 53-year-old male who presented to Moffitt Cancer Center with a fungating lesion of the ventral penis and scrotum which was biopsy proven to be well-differentiated squamous cell carcinoma, invasive into at least the lamina propria, and unknown human papillomavirus (HPV) (Figure 1A). Presentation was delayed because of lack of health insurance. The penile lesion was mobile and inguinal lymph node (iLN) enlargement was not appreciated on physical examination. Staging CT and MRI imaging identified tumor effacement of the corpus spongiosum (Figure 1B), no evidence of iLN, pelvic, or distant metastases.

The patient was counselled on radical penectomy due to concern for \geq cT2 disease, but he adamantly refused penectomy despite guideline directed counselling[1]. The case was presented at Multidisciplinary tumor board (MDT) who favored penectomy, but patient preference was considered, and wide local excision with suprapubic catheter placement and staged penile urethroplasty after a period of observation to ensure adequate local control was discussed and presented to the patient. He refused.

Additional MDT discussions led to recommendation for induction paclitaxel, ifosfamide, and cisplatin (TIP) chemotherapy due to limited treatment options. The patient underwent 4 cycles of TIP chemotherapy without major adverse events resulting in a complete response (Figure 1C and 1D). The patient underwent 28 fractions of external beam radiation to the iLNs. At most recent follow-up he has no evidence of disease.

These clinical images document the complete response of a large primary penile tumor with TIP chemotherapy alone and importance of multidisciplinary care.

Reference

- Clark PE, Spiess PE, Agarwal N, Biagioli MC, Eisenberger MA, Greenberg RE, et al. Penile cancer: Clinical Practice Guidelines in Oncology. *J Natl Compr Canc Netw*.2013;11(5):594-615.

Key Words

Penile cancer, chemotherapy, radiotherapy, interdisciplinary communication

Competing Interests

None declared.
Patient Consent: Obtained.

Article Information

Received on October 18, 2022
Accepted on October 22, 2022
Soc Int Urol J. 2023;4(2):150–152
DOI: 10.48083/GVTL9492

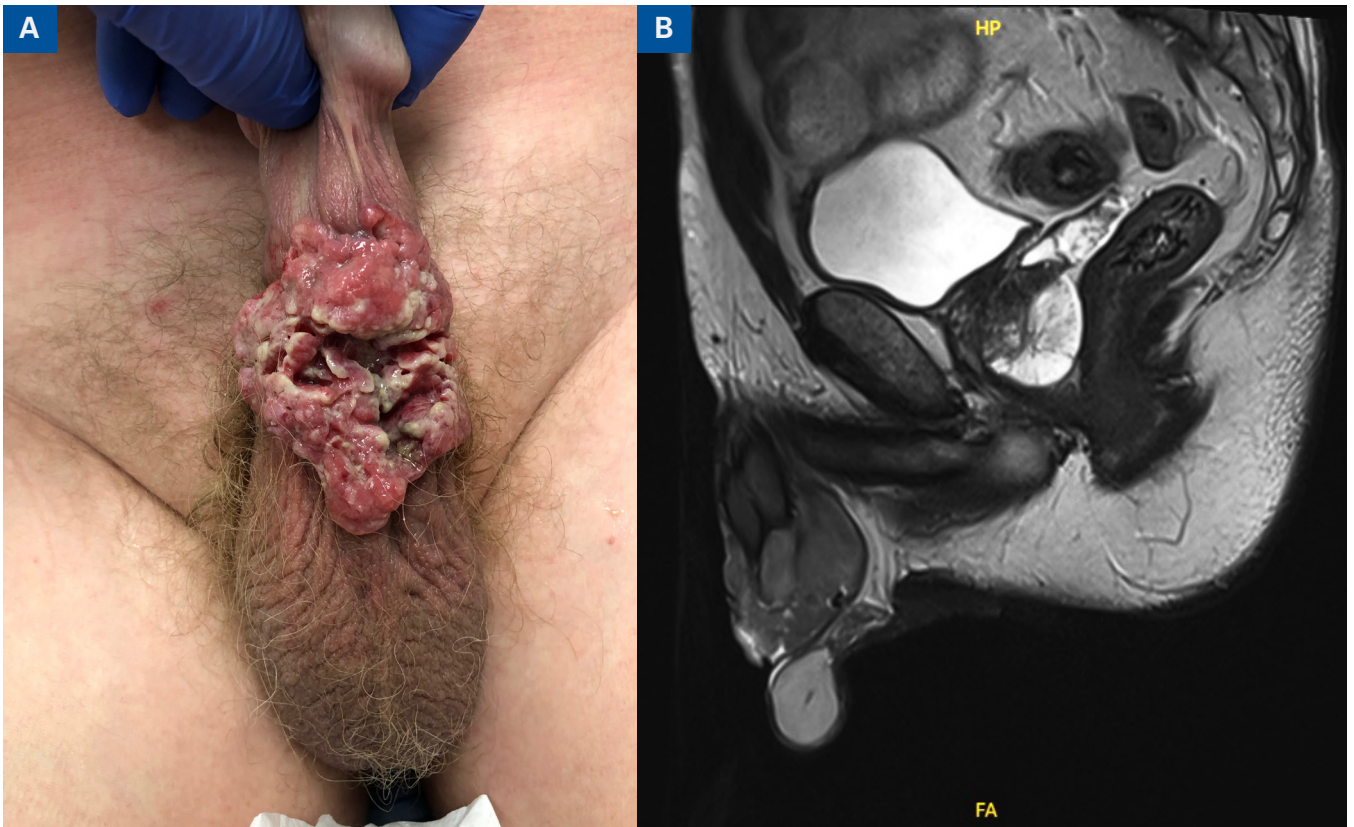
FIGURE 1.

Representative photo of the penile lesion

A) On initial presentation

B) Pre-treatment sagittal and axial MRI demonstrating penile mass with effacement of the corpus spongiosum

INITIAL PRESENTATION



- C) Penile lesion status post 3 cycles paclitaxel, ifosfamide, and cisplatin (TIP) Chemotherapy
D) Post-treatment MRI images with resolution of primary penile tumor

STATUS POST TIP CHEMO

