

# Malakoplakia Causing Poor Bladder Compliance and Bilateral Hydroureteronephrosis

✉ Cecile T. Pham,<sup>1,2</sup> Melanie Edwards,<sup>3</sup> Amanda S.J. Chung,<sup>1,2</sup> Venu Chalasani<sup>1,2</sup>

<sup>1</sup>Department of Urology, Northern Beaches Hospital, Frenchs Forest, Australia <sup>2</sup>North Shore Urology Research Group, St Leonards, Australia

<sup>3</sup>Department of Anatomical Pathology, Douglass Hanley Moir Pathology, Macquarie Park, Australia

An 81-year-old female presented with lower urinary tract symptoms (LUTS) including frequency, urgency and urge incontinence. She had a 2-year history of recurrent urinary tract infections (UTI) with *Escherichia coli* of varying susceptibility. Background history included rheumatoid arthritis treated with long-term corticosteroids, and stage-4 chronic kidney disease due to hypertensive nephrosclerosis.

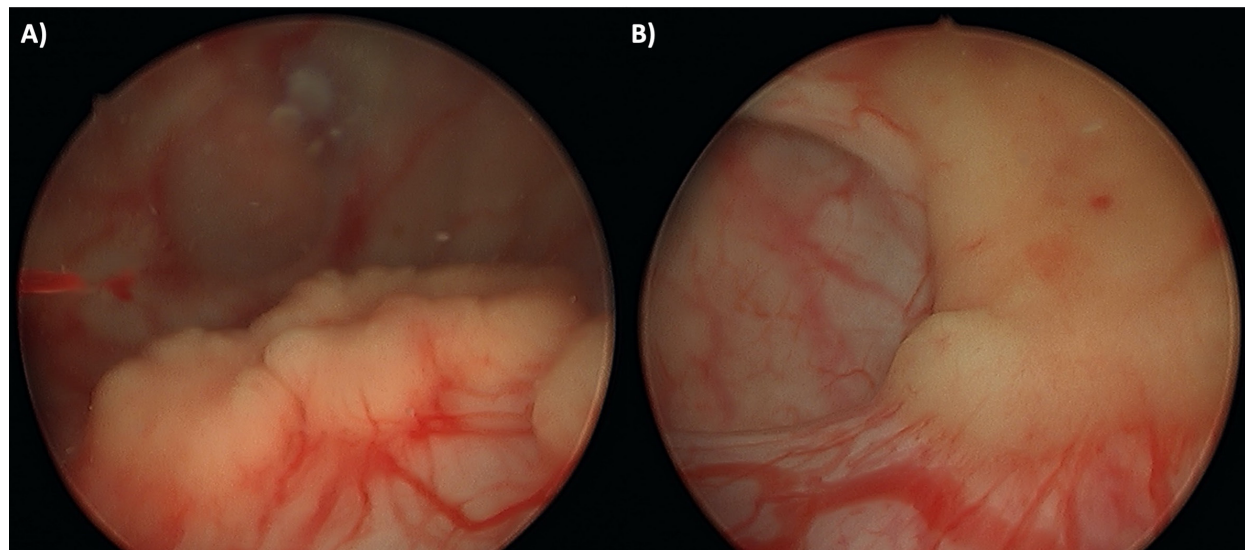
Non-contrast CT imaging showed severe bilateral hydroureteronephrosis to the level of the vesicoureteric junction and circumferential bladder wall thickening. The patient had a creatinine level of 221  $\mu\text{mol/L}$  and eGFR rate of 18mL/min/1.73m<sup>2</sup>. Cystoscopy

revealed diffuse erythema and white-yellow nodules (Figure 1). Histopathological examination of bladder biopsies demonstrated numerous Michaelis-Gutmann bodies, pathognomonic for the rare chronic inflammatory condition malakoplakia (Figure 2)[1–5]. There was no evidence of dysplasia or malignancy. Urodynamic assessment revealed increased bladder sensation and poor bladder compliance with impaired detrusor contractility.

Malakoplakia is usually associated with recurrent UTI, particularly *Escherichia coli*, *Staphylococcus aureus*, *Proteus*, and *Klebsiella*[4]. The patient was commenced on trimethoprim/sulfamethoxazole 150/100mg daily

## FIGURE 1.

Cystoscopy showing (A) malakoplakia nodules in the bladder and surrounding a severely dilated ureteric orifice (B)



### Key Words

Malakoplakia, urinary tract infections, urinary bladder, lower urinary tract symptoms

### Competing Interests

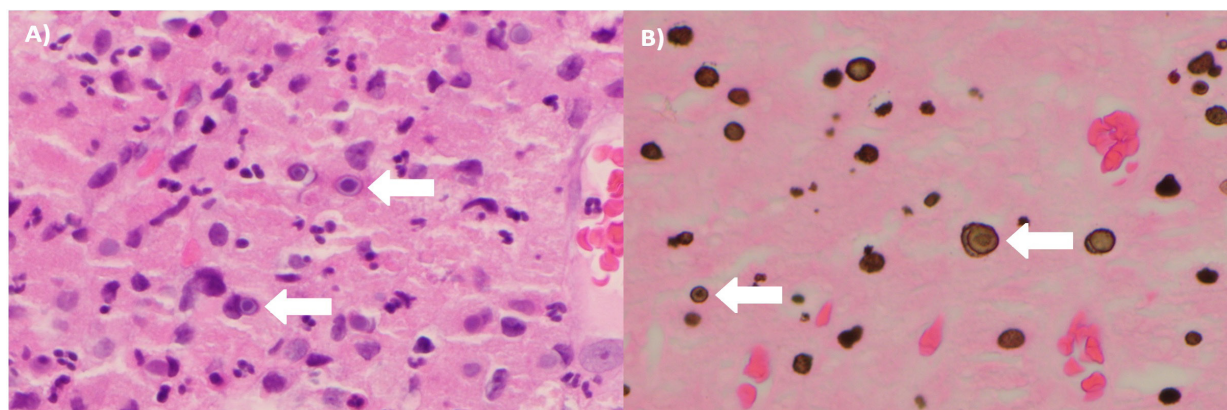
None declared.  
Patient Consent: Obtained.

### Article Information

Received on December 3, 2021  
Accepted on December 11, 2021  
Soc Int Urol J.2021;3(4):281–282  
DOI: 10.48083/QFCW5582

**FIGURE 2.**

Histopathological images at x40 magnification with white arrows demonstrating the Michaelis-Gutmann bodies on (A) H&E stain and (B) von Kossa calcium stain



prophylaxis, which was switched to cephalexin 500mg daily prophylaxis due to poor tolerance. She was also commenced on methenamine hippurate, supplemental vitamin C, and completed a course of Uromune for UTI prophylaxis.

The nodules had largely resolved on progress cystoscopy four months later. At this time, she was treated with

intravesical antibiotic wash using gentamicin 480mg diluted in 1L 0.9% sodium chloride.

This case demonstrates that malakoplakia can cause obstructive uropathy. It serves as a reminder to consider malakoplakia as a differential, particularly in women with recurrent UTI and immunosuppression.

## References

1. Kogulan PK, Smith M, Seidman J, Chang G, Tsokos M, Lucey D. Malakoplakia involving the abdominal wall, urinary bladder, vagina, and vulva: case report and discussion of malakoplakia-associated bacteria. *Int J Gynecol Pathol.*2001;20:403-406. doi: 10.1097/00004347-200110000-00016
2. Bylund J, Pais VM Jr. A case of acute renal failure caused by bilateral, multifocal malacoplakia lesions of the bladder and ureters. *Nat Clin Pract Urol.*2008;5(9):516-519. doi:10.1038/ncpuro1173
3. Sanchez LM, Sanchez SI, Bailey JL. Malacoplakia presenting with obstructive nephropathy with bilateral ureter involvement. *Nat Rev Nephrol.*2009;5(7):418-422. doi: 10.1038/nrneph.2009.86
4. Cavallone B, Serao A, Audino P, Di Stasio A, Tiranti D, Vota P. Bilateral hydronephrosis with renal failure caused by malacoplakia. *Urologia.*2017;85(1):36-37. doi: 10.5301/uj.5000268
5. Stamatou K, Chelioti E, Tsavari A, Koulia K, Papalexandrou A, Efthymiou E, et al. Renal failure caused by malakoplakia lesions of the urinary bladder. *Nephrourol Mon.*2014;6(4). doi: 10.5812/numonthly.18522