

Evaluating the design modifications of an intramedullary forearm nail system: a cadaver study

Henry S Pretorius,*^{ORCID} Marilize C Burger, Nando Ferreira

Division of Orthopaedic Surgery, Department of Surgical Sciences, Faculty of Medicine and Health Sciences, Stellenbosch University, Cape Town, South Africa

*Corresponding author: hsp359@sun.ac.za

Citation: Pretorius HS, Burger MC, Ferreira N. Evaluating the design modifications of an intramedullary forearm nail system: a cadaver study. *SA Orthop J* 2022;21(1):12-15. <http://dx.doi.org/10.17159/2309-8309/2022/v21n1a1>

Editor: Dr Frans Birkholtz, University of Pretoria, Pretoria, South Africa

Received: June 2021

Accepted: October 2021

Published: March 2022

Copyright: © 2022 Pretorius HS. This is an open-access article distributed under the terms of the Creative Commons Attribution Licence, which permits unrestricted use, distribution and reproduction in any medium, provided the original author and source are credited.

Funding: No funding was received for this study.

Conflict of interest: The authors declare no conflict of interest. All research related to design and manufacture of the intramedullary nail system was done in conjunction with ImplantCast GmbH (Buxtehude, Germany). Prototypes were produced and provided for research purposes at no cost. All research-related costs were borne by Stellenbosch University. A royalty agreement between Stellenbosch University and ImplantCast GmbH (Buxtehude, Germany) was negotiated in the event of the design eventually being used commercially.

Abstract

Background

Current orthopaedic practice requires a forearm nail that is length and rotationally stable and which can restore functional anatomy. A forearm nailing system was designed based on clinical need. This nailing system features unique designs and locking holes that offer a larger approach and escape angle for ease of interlocking. The aim of the present study was to test the prototype and evaluate the design changes in cadaver bones.

Methods

A cross-sectional cadaveric study, including ten cadavers with normal forearm anatomy (n = 20 forearms) was conducted. Both forearms of the cadavers were used to evaluate the locking times and exposure time during i) insertion; ii) locking; and iii) removal of the nails, resulting in the evaluation of a total of 40 procedures. All nails were assessed for insertions of interlocking screws.

Results

The nail was successfully inserted into 38 bones. Inserted nails were available for locking (n = 38), and all locking attempts at both driving ends (n = 38, 100%), as well as the non-driving ends (n = 76, 100%), were successful. Freehand locking at the non-driving end of the nail (38 cases, 76 locking holes) took a median of 44.5 seconds (interquartile range [IQR] 33.0–59.0), while the number of exposures ranged from 2 to 12 with a median of 5.5 exposures (IQR 4.0–8.0). The freehand locking procedure's exposure time was 0.09 minutes (IQR 0.07–0.23).

Conclusion

The proposed forearm intramedullary nail design modifications allowed for successful implantation, interlocking and removal of nails in both radius and ulna cadaver bones, with acceptable radiation exposure.

Level of evidence: Level 5

Keywords: radius and ulna intramedullary nail, locked forearm nail, forearm fractures

Introduction

Current orthopaedic practice requires a forearm nail that is length and rotationally stable and which can restore functional anatomy. Restoring forearm motion is vital to regaining full upper limb function following radius and ulna fractures. The anatomical relationship of the radius and ulna allows the forearm to function as a joint, and this motion contributes significantly to the versatility of the human hand. To maintain this motion and restore forearm function, most fractures involving either bone or involving the proximal or distal radioulnar joint will usually need surgical fixation.^{1,2}

The gold standard of management in adult forearm fractures is compression plate fixation for simple fractures and bridge plating for comminuted fractures.³ Locked intramedullary nails have been shown to have comparable results but have mostly fallen out of favour and have been removed from the market for various reasons, including difficulty with the placement of interlocking screws.⁴⁻⁷ The problem with traditional forearm nails is the freehand locking at the non-driving end of the nail that may be challenging to execute. The interlocking hole size, soft tissue envelope and proximity of the radial nerve make this a challenging procedure, even in experienced hands. In a recent study by Blažević et al., good results have been reported with a

locking forearm nail, but the publication failed to describe the non-driving end locking, which appears to have been performed from lateral in the radius as per the clinical pictures.⁸

Locking in the proximal radius is performed through the supinator muscle, in close proximity to where the posterior interosseous nerve transverses the muscle. It can either be penetrated, entangled or suffer thermal damage, which will result in nerve fallout that may be temporary or permanent. Several authors reported up to an 11% incidence of radial nerve damage during proximal radius locking.⁹⁻¹⁰ Köse et al., in their nail design, omitted locking at the non-driving end of the radius due to the perceived risk of injury to the radial nerve.¹¹ Bansal showed no damage to the radial nerve in 19 cases by using a different approach to the radius neck depending on the locking hole position.¹²

Fluoroscopy exposure times for the locking of intramedullary devices is another concern and vary widely in published reports.¹³⁻¹⁸ During interlocking of femoral nails, Suhm et al. reported exposure times of 108 seconds, while Müller et al. noted screening times in excess of 4 minutes during freehand locking for the same procedure.^{19,20} In turn, Weckbach and Bansal reported forearm fluoroscopy times for locking at between 4.4 and 14 minutes and 3.5 minutes, respectively.^{12,21}

Currently, only one forearm nailing system is commercially available in our geographic area; as this nail is only locked at the driving end, these devices lack rotational stability. The nail has some design features that make it impractical for use in specific fracture configurations. The nail diameter is too small and lacks the internal cortical grip to stabilise the radius of curvature of the forearm bones. This may lead to an anatomically straight radius which subsequently increases the risk of non-union.²¹ The 20 mm nail length increments also make the accurate restoration of length unstable fracture patterns challenging, as the surgeon must rely on subchondral abutment to provide length stable fixation.

We undertook the challenge of designing a modified forearm nailing system that improves nail insertion and interlocking ergonomics. Unique design features include longitudinal surface flutes that allow pressure release during nail insertion and newly designed locking holes that offer a larger approach and escape angle for ease of interlocking and potentially reducing radiation exposure. The length increments were also reduced to 10 mm with a nail size of 4.5 mm (Figure 1).

This study aimed to evaluate the design modifications of this forearm nailing system in ten cadavers. Specific objectives were to: i) assess the number of attempts to achieve locking, which is relevant to the ease of locking; ii) measure the screening time required during locking, and evaluate exposure; iii) measure the total screening time; and iv) assess the ease of removal of the nail.

Material and methods

A cross-sectional cadaveric study was conducted to evaluate the design modifications of the forearm nail. Ethical approval was obtained prior to the commencement of this study. Two experienced orthopaedic trauma surgeons performed all insertion procedures. Interlocking was done for all inserted nails, with both surgeons locking an equal number of nails.

Ten formaldehyde-preserved cadavers were included, with specific inclusion criteria being skeletal maturity (> 18 years) and previously uninjured forearm bony anatomy. The forearms were X-rayed with the image intensifier to preclude previous trauma. The forearm bones of both upper limbs were used to evaluate the insertion, locking and removal of the nails, resulting in the evaluation of a total of 40 procedures. The ability to open the canal, ream and complete insertion of the nail was documented.

Radius nails were pre-bent to a radius of curvature of 569 mm, while ulna nails were pre-bent to 10°.²³ The entry point for all the




Figure 1. Novel nail design illustrating product sizes, flutes, screws and non-driving end locking with 35° approach angle as well as nails bent to the correct curvature for each bone

radius nails was the distal ridge of Lister's tubercle, and the radial canal was opened with a 6 mm entry drill. The medullary canal was reamed with a 5 mm hand reamer to accommodate the 4.5 mm diameter nail. The nail was attached to the jig and advanced with the forearm in supination to a depth where the locking holes were in the radial neck proximal to the biceps tuberosity. An anterior incision was made over the radial neck in supination, and blunt dissection was used to reach the bone. A radiolucent plastic drill sleeve was used to protect the soft tissue during drilling. Freehand locking was done through both holes using a fluoroscopic image intensifier (Figure 2). All nails were locked, through the jig, at the driving end (Figure 3).

Ulna nails used the entry point at the olecranon's posterior aspect, using a 6 mm drill. The canal was prepared with a 5 mm reamer followed by nail insertion to the distal ulnar metaphysis depth. A dorsal incision was made over the distal ulna with the forearm in pronation, and a radiolucent plastic drill sleeve was used to protect the soft tissue during drilling. Freehand locking was done through both holes using a fluoroscopic image intensifier. All nails were locked, through the jig, at the driving end (Figures 2 and 4).

The time for each locking attempt was recorded. A preliminary image intensifier scout view was taken, and an incision was made over the locking holes. The drill was placed onto the bone, and another image intensifier view was taken to ascertain the drill tip's position. The timer for locking was then started, and all exposures,

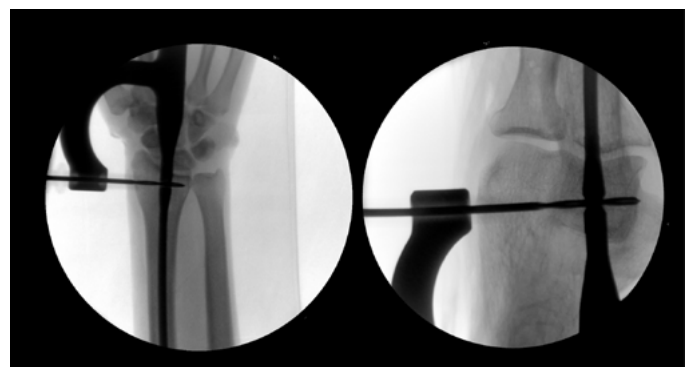

Figure 2. Jig locking in radius and ulna

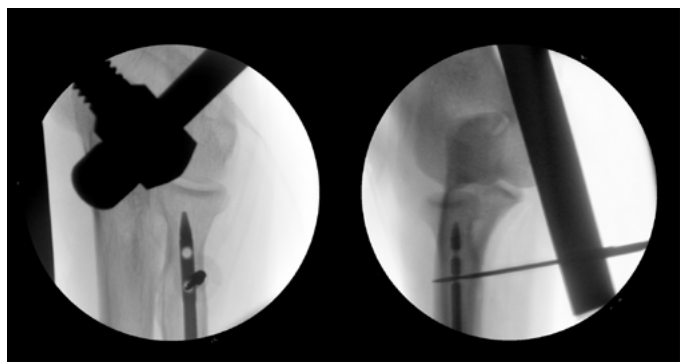


Figure 3. Proximal radius locking with drill successfully traversing the bone and the locking hole

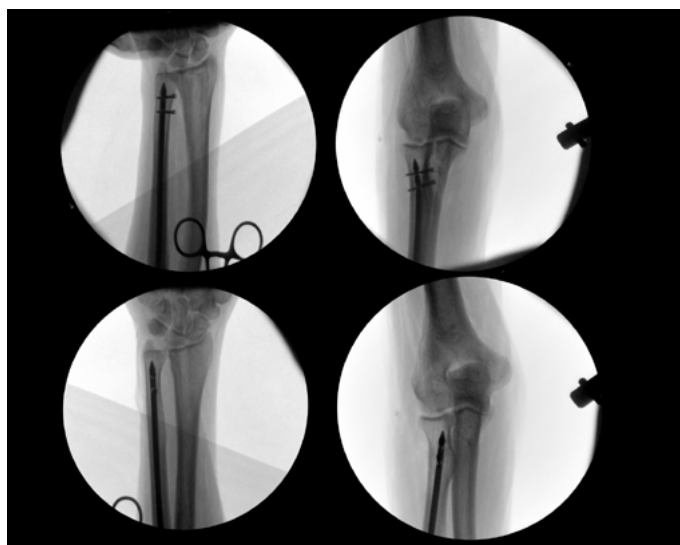

Figure 4. Locking screws placed at the non-driving end of the ulna and radius shown in an AP and lateral plane. Screws are placed from volar in full supination for the radius and from dorsal in a fully pronated ulna.

including the second scout view, were recorded. The timer was only stopped once the drill was passed through the opposite cortex and confirmed with fluoroscopy (Figure 3). The number of locking attempts was recorded, and the timer continued until the locking was successfully accomplished. Screws were passed through the nail for confirmation of locking (Figure 4). The number of exposures and total screening time of each attempt was recorded in minutes. All nails were removed after insertion, with the ability to remove the nail being recorded.

Statistical analysis

Data was analysed using STATISTICA (v13, TIBCO Software). Data is described as means \pm standard deviations with 95% confidence intervals or medians with interquartile ranges (IQR). Categorical data is described as frequencies, with the count indicated in parentheses. No hypothesis testing was performed considering the proof-of-concept nature of this investigation.

Results

The entry point was exposed, and the 6 mm drill was successfully inserted in all cases ($n = 40$, 100%) (Table I). The shaft was reamed successfully in 95% of cases ($n = 38$), and the nail was successfully inserted into these bones. Complications arose in two cases (5%), where the medullary canal was too narrow in one case, and the reamer broke inside the canal in the other.

All nails that were successfully inserted were available for locking ($n = 38$). All locking attempts at both the driving end ($n = 38$, 100%)

Table I: Overview of procedure success

Procedure (n)	Successful	Unsuccessful
Entry point (40)	100.0 (40)	0.0 (0)
Shaft ream (40)	95.0 (38)	5.0 (2)
Jig locking (38)	100.0 (38)	0.0 (0)
Free locking (76)	100.0 (76)	0.0 (0)
Nail removal (38)	100.0 (38)	0.0 (0)

Table II: Overview of time and exposure of freehand locking attempts

	Median (IQR) (n = 76)	Range
Time (s)	44.50 (33.00–59.00)	14.00–112.00
Exposures (n)	5.5 (4.0–8.0)	2.00–12.00
Exposure (minutes)	0.09 (0.07–0.13)	0.03–0.23

IQR: interquartile range

as well as the non-driving end ($n = 76$, 100%) were successful (Table I). In three instances (4%), comprising two ulna locking holes and one radial locking hole, two attempts were required to achieve locking. Nails were successfully removed in all cases ($n = 38$, 100%) (Table I).

Freehand locking at the non-driving end of the nail (38 cases, 76 locking holes) took a median of 44.5 seconds, while the number of exposures required ranged from 2 to 12 with a median of 5.5 exposures (Table II). The median total exposure time for the freehand locking procedure was 0.09 minutes (Table II).

Discussion

Designing a forearm nail that is length and rotationally stable and can restore functional anatomy is challenging, and many aspects must be considered. Contemporary forearm nail design has no reliable way to control rotation or length, and the restoration of the native anatomy can be challenging. This study aimed to evaluate the design modifications of a forearm nailing system in a cadaver study.

The successful implanting of nails in all cases where the bones could be reamed shows an acceptable implant diameter. This will require further testing in patients to establish if this is true for the broader population. The two cases where the canal of the radius was not amenable for the procedure included only a single case where the radius canal was too small for the reamer. This may be due to normal anatomical variations or dominance as the contralateral side was nailed easily. The other case was amenable to a nail, but the reamer broke, and the nail could not be inserted. This may be related to design issues for the reamer which have been addressed. Considering the small sample size ($n = 10$ cadavers) where the anatomy of both forearms is expected to be symmetrical, this was not an unusual finding. This study has shown that the nail size might potentially fit into most trauma patients; if the nail does not fit into the patient's radius or ulna, an alternative treatment will be required.

Locking of both holes at the non-driving end was achieved in all cases where insertion of the nail was possible, highlighting that the new screw hole design may make insertion of these screws easier. The screw hole has a wider recess on the outside of the nail, pushing the drill towards the hole. Evaluating the locking attempts helps to establish if the hole was missed and does not relate to the time as a careful surgeon may spend more time selecting the spot for drilling and only have one attempt. The complexity of locking is clinically so relevant that the noticeable absence of its description by Blažević et al. of his locking procedure or direction is concerning,

with only one minor radial nerve injury when the literature reports at 11%.⁸ Contemporary available nail designs do not afford the ability to interlock at the non-driving end of the nail, potentially resulting in fractures fixed in a shortened position or intraoperative length being lost if the nail does not abut the subchondral bone at the non-driving end. Rotational control may also be insufficient with the currently available implants.

Iatrogenic radial nerve injury is another concern,^{8,12,22} specifically with the insertion of locking screws in the neck of the radius. The use of radiolucent drill sleeves worked well to mitigate any soft tissue incarceration during drilling. In the clinical setting, this may help prevent radial nerve injury.

Limiting radiation exposure is an increasingly important consideration during orthopaedic procedures.^{14,15,17} Investigations by Kim et al. reported fluoroscopy times between 240 and 840 seconds for nails, and 78 to 162 seconds for plating of forearm fractures.²³ In this series, cases included both locking nails and non-locking nails, and screening time was measured for the entire procedure. Similarly, screening time for femoral or tibial nails has been reported to range between 180 and 360 seconds.^{16,18,19} In the current series, a maximum exposure time during locking was 0.23 minutes (13 seconds), mostly in agreement with the previous reports. The relatively short locking times in the current study could be attributed to the surgeons' experience in performing this procedure and the dimensions of the new locking hole, including a wide entry and exit angle, both of which may have added to the ease of locking. The exposures ranging between 2 and 12 seconds indicates the difficulty in accurately aligning the drill with the interlocking hole. The aim was to lock the nail with acceptable exposure times knowing that further exposure would occur for the rest of the procedure.

All the nails were removed successfully after the procedure was done and the jig disengaged. The locking bolt was easily inserted into the nail and the nail was easily removed. This is important as, if there is an issue with the nail, the instrumentation can be used to remove the nail.

The study's main strength was the ability to illustrate that the forearm nail fits into most forearms in the present study and that the locking can be achieved in a timeous fashion without excessive radiation exposure. A limitation of this study was the inability to test the radius of curvature of the nail and its ability to restore the anatomy of a fractured radius with the use of intact forearms. In addition, the nature of a cadaver study does not lend itself to investigate injury to the nerve and vascular structures, the stability of the bones for union and functional outcome. Furthermore, the fact that anatomically normal bones were used in this study naturally lends itself to easier procedures, which might result in reduced time requirements.

We have been able to evaluate 76 potential locking holes, but the limited number of cadavers is also a limitation that can be corrected with a clinical study. Therefore, clinical evaluation is recommended for future research investigating the use of this nail in forearm fractures to evaluate efficacy in terms of providing length and rotational stability and union and function in radius and/or ulna fractures.

Conclusion

The proposed forearm intramedullary nail design modifications allowed for successful implantation, interlocking and removal of nails in both radius and ulna cadaver bones, with acceptable radiation exposure.

Ethics statement

The authors declare that this submission is in accordance with the principles laid down by the Responsible Research Publication Position Statements as developed at the 2nd World Conference on Research Integrity in Singapore, 2010. Prior to commencement of the study, ethical approval was obtained from the following ethical review board: Stellenbosch University Health Research Ethics committee, (N19/09/097).

Declaration

The authors declare authorship of this article and that they have followed sound scientific research practice. This research is original and does not transgress plagiarism policies.

Author contributions

HSP: study conceptualisation, data capture, data analysis, manuscript preparation, manuscript revision and final draft preparation

MCB: data analysis, manuscript revision

NF: study conceptualisation, manuscript revision and final draft preparation

ORCID

Pretorius HS  <https://orcid.org/0000-0002-7419-0885>

Burger MC  <https://orcid.org/0000-0003-2831-4960>

Ferreira N  <https://orcid.org/0000-0002-0567-3373>

References

1. Rehman S, Sokunbi G. Intramedullary fixation of forearm fractures. *Hand Clin.* 2010;26(3):391-401. <https://doi.org/10.1016/j.hcl.2010.04.002>.
2. Moss JP, Bynum DK. Diaphyseal fractures of the radius and ulna in adults. *Hand Clin.* 2007;23(2):143-51. <https://doi.org/10.1016/j.hcl.2007.03.002>.
3. Bizarro J, Regazzoni P. Principles of fracture fixation Learning outcomes The four AO principles.1-12. <https://aotrauma.aofoundation.org>.
4. Zhao L, Wang B, Bai X, et al. Plate fixation versus intramedullary nailing for both-bone forearm fractures : a meta-analysis of randomized controlled trials and cohort studies. *World J Surg.* 2017;41(3):722-33. <https://doi.org/10.1007/s00268-016-3753-1>.
5. Saka G, Saglam N, Kurtulmuş T, et al. New interlocking intramedullary radius and ulna nails for treating forearm diaphyseal fractures in adults: a retrospective study. *Injury.* 2014;45 Suppl 1:16-23. <https://doi.org/10.1016/j.injury.2013.10.040>.
6. Saka G, Kurtulmuş T, Saglam N, et al. The treatment of adult isolated ulna diaphysis fractures with intramedullary Ulna A Nail. *Injury.* 2012;43(Sept):16-23.
7. Gagan K, Sharma R. Elastic intramedullary nailing: an alternative in elderly osteoperotic forearm fractures. *Int J Orthop Traumatol Surg Sci.* 2017;3(1):441-46.
8. Blažević D, Benčić I, Čuti T, et al. Intramedullary nailing of adult forearm fractures: Results and complications. *Injury.* 2021;52 Suppl 5:S44-48. <https://doi.org/10.1016/j.injury.2020.11.012>.
9. Zhang XF, Huang JW, Mao HX, Chen WB, Luo Y. Adult diaphyseal both-bone forearm fractures: A clinical and biomechanical comparison of four different fixations. *Orthop Traumatol Surg Res.* 2016;102(3):319-25. <https://doi.org/10.1016/j.otsr.2015.11.019>.
10. Zhang B, Chang H, Yu K, et al. Intramedullary nail versus volar locking plate fixation for the treatment of extra-articular or simple intra-articular distal radius fractures: systematic review and meta-analysis. *Int Orthop.* 2017;41(10):2161-69. <https://doi.org/10.1007/s00264-017-3460-z>.
11. Köse A, Aydın A, Ezirmik N, et al. Alternative treatment of forearm double fractures: new design intramedullary nail. *Arch Orthop Trauma Surg.* 2014;134(10):1387-96. <https://doi.org/10.1007/s00402-014-2058-9>.
12. Bansal H. Intramedullary fixation of forearm fractures with new locked nail. *Indian J Orthop.* 2011;45(5):410-16. <https://doi.org/10.4103/0019-5413.83760>.
13. Rashid MS, Aziz S, Haydar S, Fleming SS, Datta A. Intra-operative fluoroscopic radiation exposure in orthopaedic trauma theatre. *Eur J Orthop Surg Traumatol.* 2018;28(1):9-14. <https://doi.org/10.1007/s00590-017-2020-y>.
14. Van der Merwe B. Radiation dose to surgeons in theatre. *S Afr J Surg.* 2012;50(2):26-29. <https://doi.org/10.7196/sajs.965>.
15. Çeçen GS, Gülabi D, Pehlivanoglu G, et al. Radiation in the orthopedic operating theatre. *Acta Orthop Traumatol Turc.* 2015;49(3):297-301. <https://doi.org/10.3944/aott.2015.14.0250>.
16. Köse A. Intramedullary nailing of adult isolated diaphyseal radius fractures. *Turkish J Trauma Emerg Surg.* 2015;22(2):1-8.
17. Blattert TR, Fill UA, Kunz E, et al. Skill dependence of radiation exposure for the orthopaedic surgeon during interlocking nailing of long-bone shaft fractures: a clinical study. *Arch Orthop Trauma Surg.* 2004;124(10):659-64. <https://doi.org/10.1007/s00402-004-0743-9>.
18. Lo NN, Goh PS, Khong KS. Radiation dosage from use of the image intensifier in orthopaedic surgery. *Singapore Med J.* 1996;37(1):69-71.
19. Suhm N, Messmer P, Zuna I, Jacob LA, Regazzoni P. Fluoroscopic guidance versus surgical navigation for distal locking of intramedullary implants: A prospective, controlled clinical study. *Injury.* 2004;35(6):567-74. [https://doi.org/10.1016/s0020-1383\(03\)00312-7](https://doi.org/10.1016/s0020-1383(03)00312-7).
20. Müller LP, Sufferer J, Wenda K, Mohr W, Rommens PM. Radiation exposure to the hands and the thyroid of the surgeon during intramedullary nailing. *Injury.* 1998;29(6):461-68. [https://doi.org/10.1016/s0020-1383\(98\)00088-6](https://doi.org/10.1016/s0020-1383(98)00088-6).
21. Weckbach A, Blattert TR, Weisser C. Interlocking nailing of forearm fractures. *Arch Orthop Trauma Surg.* 2006 Jul;126(5):309-15. <https://doi.org/10.1007/s00402-006-0122-9>.
22. Köse A, Aydın A, Ezirmik N, et al. A comparison of the treatment results of open reduction internal fixation and intramedullary nailing in adult forearm diaphyseal fractures. *Turkish J Trauma Emerg Surg.* 2006;23(3):235-43. <https://doi.org/10.5505/tjtes.2016.66267>.
23. Kim SB, Heo YM, Yi JW, Lee JB, Lim BG. Shaft fractures of both forearm bones: The outcomes of surgical treatment with plating only and combined plating and intramedullary nailing. *Clin Orthop Surg.* 2015;7(3):282-90. <https://doi.org/10.4055/cios.2015.7.3.282>.