

Degenerative leiomyopathy

Z Henning, MB ChB

S M le Grange, MB ChB, MMed (Surg), CPS (SA)

R S du Toit, MB ChB, MMed (Surg), FCS (SA)

Department of Surgery, Universitas Hospital, and University of the Free State, Bloemfontein

Degenerative leiomyopathy (DL) is a distinctive form of acquired degenerative visceral myopathy of uncertain aetiology. It occurs mainly in Africa and results in intestinal pseudo-obstruction (IP). Thirty-nine patients from the Western Cape region of South Africa have been reported.¹ Characteristic clinical features included a chronic, insidious history of repeated attacks of abdominal distension, pain and vomiting. Marked gaseous distension with atony and IP, especially of the colon, was noted on X-ray films. Megacolon was the most common radiological feature, but pseudo-obstruction extended proximally into the small intestine in some patients with advanced disease. In the majority of cases the condition was progressive and eventually affected the entire gastrointestinal (GI) tract.¹ We present a single case of a 9-year-old girl with this condition.

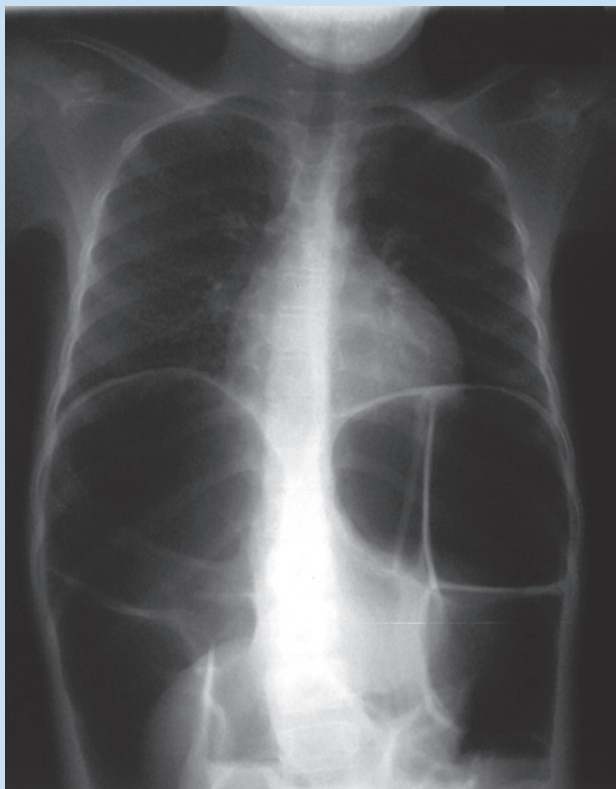


Fig. 1. Chest X-ray of 9-year-old Sotho girl.

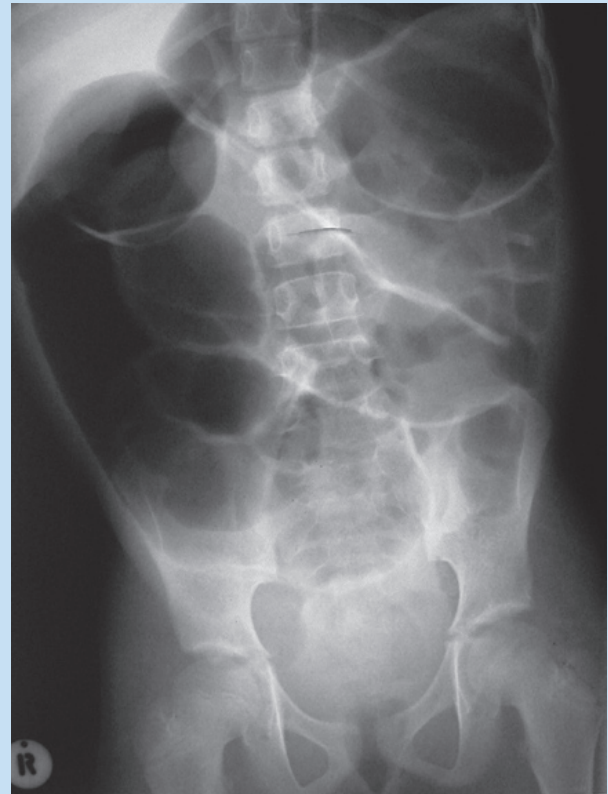


Fig. 2. Abdominal X-ray of 9-year-old Sotho girl.

Case report

A 9-year-old Sotho girl was referred to the casualty department of a regional hospital with a longstanding history of abdominal pain, intermittent vomiting and constipation. The mother had consulted a number of doctors for a diagnosis and treatment, without success. There was no history of any other diseases, allergies or previous surgery. She had never been treated by a traditional healer. There was no family history of any diseases. Her maternal grandfather is a Xhosa.

The patient was a thin girl with severe abdominal distension. On examination the abdomen was soft, non-tender, with no masses or organomegaly palpable. The abdomen percussed tympanic and bowel sounds were diminished. Rectal examination was normal. Her full blood count and biochemistry were normal. Abdominal X-rays showed severe gas-trapping in both small bowel and colon (Figs 1 and 2).

Further management entailed open, full-thickness bowel biopsies. At laparotomy malrotation was noted, as well as distended small and large bowel. Three full-thickness biopsies were taken. The child had 'prolonged ileus' post-operatively and Rae's mixture was initiated (5 ml tds) with good effect.

The histopathology showed fibrotic muscularis propria and no visible smooth-muscle fibres. Nerves and ganglion cells were normal. These findings fit in with degenerative leiomyopathy.

Discussion

Degenerative leiomyopathy (DL) is a distinctive non-familial myopathy degeneration without mechanical causes of obstruction. It affects mostly Africans of the south, east and central parts, but patients from other ethnic groups have been identified. Aetiology is still unknown, but smooth-muscle toxin appears to be the likely pathogenic agent. Toxins administered through cultural practices (herbal enemas containing mostly dichromates) may be an important cause. An infective cause remains an intriguing, if less possible cause. *Trypanosoma cruzi* is blamed as a possible cause.¹ DL rarely affects other family members. A genetic predisposition is needed.² DL, versus hollow-visceral myopathy, presents in an older group of children, and only rarely in the first year of life. Mean age at presentation is 9½ years.¹

Clinical presentation is a very long history of increasing abdominal distension. Initially the megacolon is confined to the anorectal junction. It then progresses to the rest of the large bowel, as well as small bowel. It eventually affects the entire GI tract and results in poor intestinal motility and malnutrition. Progressive abdominal distention, megacolon and marked gaseous distension may result in an acute presentation. The primary target, however, is the large bowel. Involvement of the urinary bladder is seen in the later stages of the disease.¹

Diagnosis is based on a distinctive clinical presentation of typical radiological findings and histology (degeneration of smooth muscle).¹

Treatment at this stage is palliative. No regimen of lasting value proves to be effective. In the acute pseudo-obstruction phase, decom-

pression of the bowel with nasogastric suctioning and colonic irrigation may be effective. Long-term bowel rest and parenteral nutrition have no long-term success. Medical treatment involves regular rectal irrigations, occasional laxatives and prokinetic agents (cisapride, neostigmine, prostigmine). A low residue diet and broad-spectrum antibiotics are indicated if bacterial overgrowth is suspected. Surgical resection has been discouraged because of the progressive nature of the disease. A gastrostomy and/or caecostomy can be done to deflate the bowel, but a colostomy has no beneficial effect and has a tendency to prolapse.¹

We found one case report in the literature of a 9-year-old boy with pseudo-obstruction, who was treated with rectal cisapride (8 mg/kg/24h) and neostigmine (0.04 mg/kg/24h). He went into remission for 9 months. Intravenous cisapride (0.15 mg/kg) returned bowel movement in the acute phase.³

Conclusion

The prognosis of this condition is poor. These patients are faced with the prospect of continuous obstructive symptoms and severe malnutrition, which eventually lead to their demise, usually in their late teens.⁴

1. Moore SW, Schneider JW, Kaschula RDC. Non-familial visceral myopathy: clinical and pathologic features of degenerative leiomyopathy. *Pediatr Surg* 2002; **18**: 2-6.
2. O'Neill J jr. *Paediatric Surgery*, 5th ed. St Louis: Mosby, 1998: 1416.
3. Cohen NP, Booth IW, Parashar K, Corkery JJ. Successful management of idiopathic intestinal pseudo-obstruction with cisapride. *Pediatr Surg* 1988; **23**: 229-230.
4. William J, Byrne MD, Cipel L, et al. Chronic idiopathic intestinal pseudo-obstruction syndrome in children – clinical characteristics and prognosis. *Pediatr Surg* 1977; **90**: 585-589.

You know a great opportunity when you see it.

You've got Middlemore written all over you.

Radiologists

Auckland, New Zealand

The Auckland region is renowned as a natural playground, boasting New Zealand's most cosmopolitan city, Auckland. There's every reason for you and your career to feel at home in the city of sails with Counties Manukau District Health Board.

Radiologists choose to work at CMDHB for many reasons. It might be the completion of our brand new department, providing you with a modern superbly equipped department. Or maybe it's the friendly can-do nature of the Counties Manukau staff. Or may be it's the training and opportunities for Radiologists to further their career's

We are currently seeking motivated Radiologists to fill Diagnostic and Interventional Radiology positions.

So if this sounds like the move you have been waiting for then hesitate no further. We will provide relocation assistance, including airfares and accommodation, and also help with immigration and registration.

So what are you waiting for to find out more please contact Renee Darby Candidate Care Consultant on 00 64 21 531 940 or email renee.darby@healthalliance.co.nz

Position Number: C00231

COUNTIES MANUKAU DISTRICT HEALTH BOARD
A Community Partnership



www.jobpulse.co.nz/cmdhb

