

# Pelvic hemangiopericytoma: a case report

**P Szkup**  
MD

**R Saadia\***  
FRCS

**G Schlaphoff**  
MBBCh

Department of Radiology and \*Surgery,  
Baragwanath Hospital, University of the  
Witwatersrand, Johannesburg.

## Abstract

*A large pelvic hemangiopericytoma causing intestinal obstruction is reported.*

## Case report

A 33-year-old African male was admitted to Baragwanath Hospital with intestinal obstruction. Emergency laparotomy revealed a large pelvic soft tissue mass occupying most of the pelvic cavity. A sigmoid loop colostomy was performed. Biopsy of the mass was not performed due to severe hypertension which developed intraoperatively. During the first week following surgery, the patient presented with hypertensive episodes and was investigated for pheochromocytoma with negative results. The open biopsy performed two months later (patient was discharged from the hospital for personal reasons) revealed a hemangiopericytoma. CT scan of the abdomen and pelvis showed a large soft tissue mass with significant post contrast enhancement and areas of necrosis within the mass (Figure 1). There was also a dilatation of both ureters and bilateral early hydronephrosis. Angiogram performed via the transfemoral route showed a large

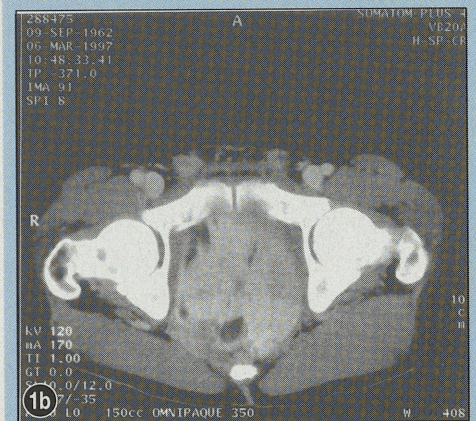
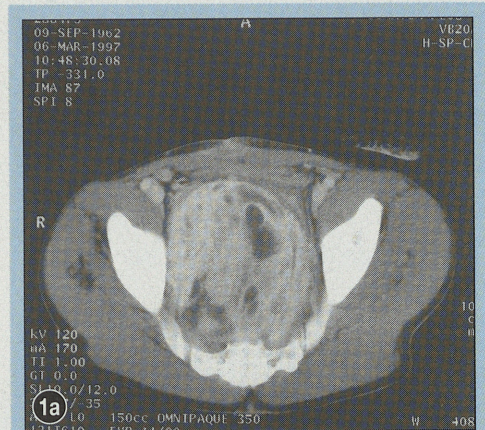

Figure 1a and b: Post contrast CT scan of the pelvis showing highly vascular tumour with multiple small areas of necrosis within the tumour.

highly vascular pelvic mass, multiple small arterial feeders originating from the anterior division of the right internal iliac artery and dense tumour stain (Figure 2). In view of planned surgical removal of the mass, transarterial embolization of the tumour was performed via the left transfemoral route. Successful embolization of all the feeders was achieved by using a 250-700 microns PVA (Contour - ITC) and by placement of four standard steel coils (Cook) (Figure 3). CT scan of the pelvis performed 24 hours following embolization showed a marked decreased vascularity of the mass and large areas of

# Pelvic hemangiopericytoma: a case report

from page 21

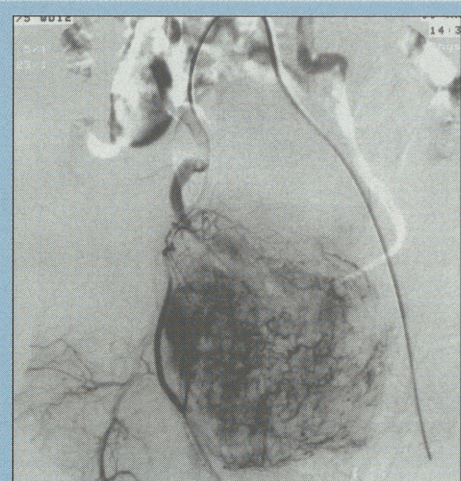

Figure 2: Selective angiogram of the right internal iliac artery showing multiple small arterial feeders and dense tumour stain.

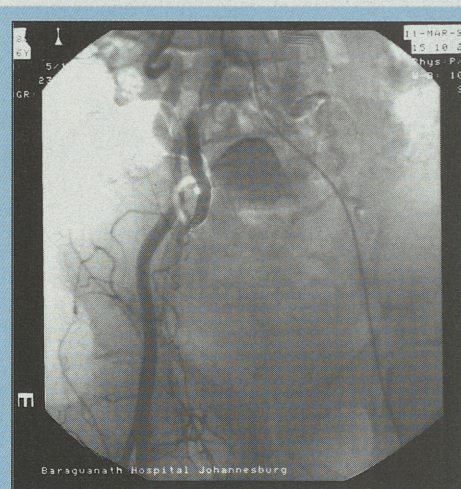


Figure 3: The right common iliac artery angiogram following embolization showing complete occlusion of all the arterial feeders.

necrosis (Figure 4). The patient was taken for surgery but the tumour was found to be inoperable. He was referred for palliative radiotherapy.

## Discussion

Hemangiopericytoma is a rare, highly vascular neoplasm comprising approximately 1% of all vascular tumours.<sup>1</sup> It was first described by Stout and Murray in 1942 and is composed mainly of pericytes, contractile cells normally found surrounding

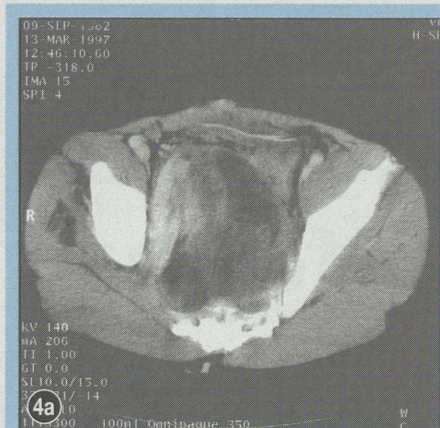


Figure 4a and b: Post contrast CT scan of the pelvis 24 hours following endovascular embolization. There is a marked decreased vascularity of the tumour and large areas of necrosis within it.

capillaries and post capillary venules.<sup>1,2,3</sup> It is a tumour of adult life and is rare in children. The tumour occurs in both sexes with equal frequency.<sup>2</sup>

Because of its origin, hemangiopericytoma has been reported in all parts of the body including: bone, head and neck, peritoneal and thoracic cavity but is most common in the lower extremities especially the thigh, pelvis and the retroperitoneum.<sup>1,2</sup>

Glomus tumour is closely related to the hemangiopericytoma but represents a different type of differentiation of pericytes and should be regarded as a separate and independent entity.<sup>2,4</sup> Meningeal hemangio-

pericytoma, often called "malignant or angioblastic meningioma", is still a controversial meningeal neoplasm. Ultrastructural studies support both pericytic and meningothelial origin.<sup>2,4</sup>

The x-ray features of hemangiopericytoma are non-specific and consist of deep-seated, well circumscribed soft tissue mass displacing neighbouring structures. Calcifications are very rare. Hemangio-pericytoma originating from the bone may present as an osteolytic lesion in the metaphysis and/or a subperiosteal large blowout lesion similar to an aneurysmal bone cyst. Angiogram of hemangiopericytoma may show a vascular mass with multiple arterial feeders, spider-shaped arrangement of vessels encircling the tumour, small corkscrew arteries and dense tumour stain.<sup>2</sup>

The WHO International Histological Classification of soft tissue tumours includes both benign and malignant forms of hemangiopericytoma.<sup>5</sup>

While most hemangiopericytomas are benign (some can show locally aggressive behaviour), some are malignant.<sup>6</sup> Malignant hemangiopericytoma is usually recognizable by its increased mitotic rate, immature tumour cells and foci of haemorrhage and necrosis.

Most malignant types of hemangiopericytomas metastasized via blood stream within a period of five years after the initial diagnosis.<sup>2,7</sup> The lung and bones are the most frequent metastatic sites.<sup>2,7</sup>

Surgical removal of the tumour is a treatment of choice, preferably with preoperative endovascular embolization.<sup>1</sup>

The effectiveness of radiation therapy for this neoplasm has not