

# The Pathogenesis and Radiological Features of Hut Lung

Authors

**Eric D Bateman**

MBChB, MD, FRCP, DCH  
Associate Professor and Head  
Respiratory Clinic  
Groote Schuur Hospital and  
University of Cape Town

**David Stickells**

MBChB, DP OBST (SA), FCP(SA)  
Registrar

**Hillel Goodman**

FRCR, FFRad(D)(SA)  
Principal Specialist Radiologist

In 1967 the term "Transkei silicosis" was proposed by Palmer and Daynes for a form of domestically-acquired pneumoconiosis found in women from the rural Transkei and Ciskei which radiologically was indistinguishable from silicosis seen in South African gold miners.<sup>1</sup> The source of silica was thought to be from quartz-containing grinding rocks used for preparing the daily standard meal of ground maize. Post-mortem histology on two cases confirmed the appearance of silicosis, and a small epidemiologic study of healthy young nurses in the Transkei confirmed early changes of pneumoconiosis in approximately 7%.<sup>1</sup> Subsequently, on the basis of findings in a larger and more detailed case collection conducted in our clinic involving the study of clinical presentation, lung physiology, bronchoalveolar lavage cell counts and histological appearance of lung biopsies, we concluded that although silicosis may account for some of the changes in some patients with this clinical entity, it appears that inhalation of non-quartz containing dust and smoke from bio-mass fuelled fires might be of greater significance in the aetiology.<sup>2</sup> The more general term "hut lung" was therefore suggested. Recognition of this condition is clearly impor-

tant in distinguishing it from other forms of interstitial lung disease, most notably disseminated or miliary tuberculosis, and sarcoidosis, and from a public health standpoint, it is a preventable disease leading to significant complications and mortality. This paper will highlight aspects of the pathogenesis and radiological features of this condition.

## Pathogenesis

The concept of dust diseases (pneumoconiosis) occurring in settings other than the confines of the workplace is being increasingly recognised. Silica particles may be found in the lungs of persons living in deserts,<sup>3</sup> and have even been found in Egyptian mummies.<sup>4</sup> Although silicosis is rare in this setting, cases of severe silicosis and even progressive massive fibrosis have been found in inhabitants of Himalayan villages exposed to dust storms.<sup>5</sup> Outdoor exposure to dusty environments such as tractor ploughing in the Free State<sup>6</sup> and farming activities in rural Canada have also been shown to cause disease.<sup>7</sup> Silica is the best recognised fibrogenic dust in these studies, but several lines of evidence suggest that silica alone may not be responsible for the nodules seen in hut lung.

1. Although respirable free silica can be identified in the ground maize, estimates of silica particles in the lung are low, even within nodules.<sup>2</sup>
2. A small field study in which atmospheric silica was sampled by means of personal samplers on subjects grinding with sandstone (100% quartz), confirmed that the concentration of respirable quartz in surrounding air was low, and that the cumulative time-weighted exposure was well below that recommended for industry and mines. Such levels would not be expected to cause pneumoconiosis, and certainly not life-threatening disease.<sup>2</sup>
3. Similar radiological and pathological appearances have been found in the lungs of

to page 5

# The Pathogenesis and Radiological Features of Hut Lung

women who have not ground maize and from others living elsewhere in South Africa.<sup>2</sup>

It should be noted however that unlike exposure in industry, domestic exposure begins at a very young age. It is possible that previously considered safe doses of silica delivered to infants or adolescent children might be pathogenic. Infants of mothers who grind are frequently bound on the mother's back or lie at her side, and girls take part in the family chores from their early teens.

Smoke from bio-mass fuelled fires (coal, wood, dung or plant material) contains carbon black and a range of other particulate material which is retained in the lungs and is visible bronchoscopically both free within the airways and submucosa. Pathology specimens confirmed the blackening of lung tissue with focal aggregates of carbonaceous material, and even anthracotic nodules. A common practice in rural traditional dwellings is to cook inside a hut (rondavel) which has no central chimney, and in cold weather family members sleep around the fire for warmth. A field study has confirmed exceedingly high smoke concentrations under these conditions.

The role of tuberculosis in patients with hut lung is difficult to define. A large proportion of patients show features compatible with healed tuberculosis raising the question of which came first, and whether calcified hilar glands represent silica exposure or are the result of tuberculosis infection. It is also possible that, as in gold miners pneumoconiosis, patients with hut lung have increased susceptibility to tuberculosis. No satisfactory epidemiologic data is available to provide answers to these questions. Pipe-smoking by rural Transkei women is not uncommon and tobacco smoke particles may also play a role in the pathogenesis.<sup>2</sup> It is therefore likely that hut

lung is the result of a mixture of dusts, delivered to the lung in women in pursuing a traditional rural lifestyle.

The prevalence of hut lung has not been established, but as lifestyle changes occur (including the design of huts, the provision of chimneys in dwellings, changing patterns of cooking and use of fuels, and increased reliance on commercially ground maize), the incidence of this disease can be expected to diminish or disappear. If employed alone, the previously suggested provision of maize grinders at local stores to replace grinding between rocks in the home is unlikely to eliminate this condition.<sup>1</sup>

## Clinical presentation

Patients are frequently asymptomatic or are X-rayed because of upper respiratory tract symptoms relating to acute infections. Many are picked up during contact tracing for tuberculosis. A minority have symptoms compatible with chronic bronchitis with variable degrees of dyspnoea. Severe cases have features of cor pulmonale. One-third of patients in our series were smokers and a similar proportion had historical or X-ray evidence of previous tuberculosis, several without microbiological confirmation.<sup>2</sup>

## Chest radiology

Chest radiographic changes range from diffuse fine rounded regular nodules resembling miliary tuberculosis to extensive fibrosis resembling progressive massive fibrosis (Figures 1a and 2a). The majority have nodules of varying size and density. The profusion scores (ILO-UICC scoring system for pneumoconiosis) range from 1/1-3/3 changes. All zones of the lung are usually involved although not uniformly, but progressive massive fibrosis usually affects upper lobes and is surrounded by characteristic traction bullae.

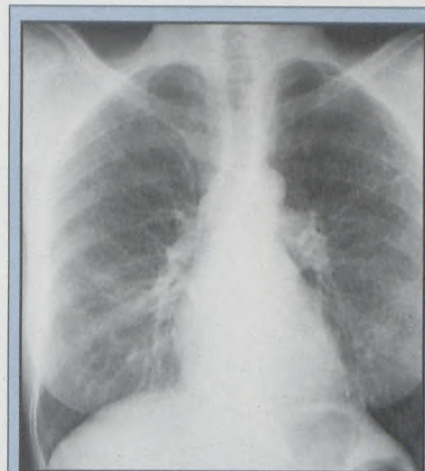

Figure 1a: Chest radiograph of a 59-year old woman with hut lung showing the diffuse fine nodular interstitial pattern with loss of vascular clarity.

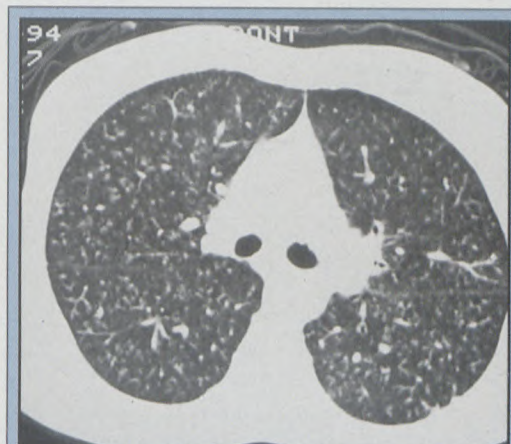


Figure 1b: HRCT lung views of the patient shown in 1a confirming the presence of evenly distributed centrilobular nodules in profusion. Fissures are not thickened and bronchovascular markings are normal.

## High resolution CT scanning

We have recently investigated the appearance of hut lung on high resolution CT scan and have confirmed a high incidence of areas of localised scarring compatible with tuberculosis, particularly in the lung apices and frequently associated with calcified hilar adenopathy. Egg-shell calcification as found in silicosis has not been observed. Localised areas of bronchiectasis suggest previous tuberculous or non-tuberculous pneumonia complicated by

# The Pathogenesis and Radiological Features of Hut Lung

scarring. The varying density and size of the nodules is uniform and indistinguishable from the appearances of miliary tuberculosis or of nodular sarcoidosis (Figures 1b and 2b). However, the beaded pattern along bronchovascular markings which is characteristic of sarcoidosis has not been observed. We have concluded however that the CT appearances of hut lung are indistinguishable from these other two conditions, and for this reason HRCT is not viewed as an essential investigation in such cases.

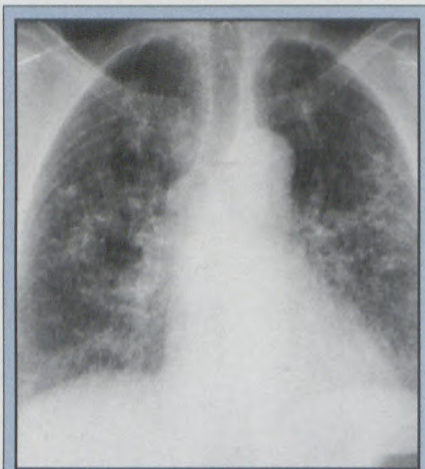

Figure 2a: Chest radiograph of a 63-year old woman with hut lung. Nodules are of variable size and less profuse in the apices. Vascular clarity is lost.

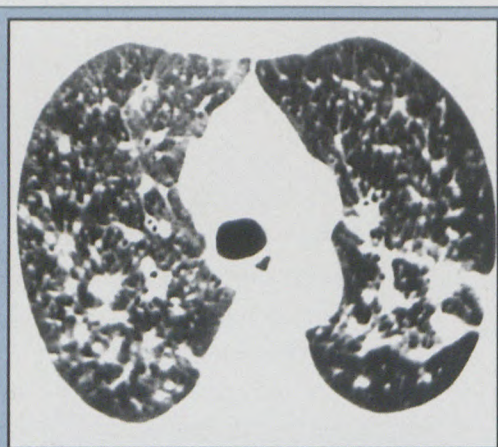


Figure 2b: HRCT views of the lungs of the patient in 2a. A diffuse centrilobular distribution is seen with slight bronchial wall thickening. Irregular spiculated nodules of varying size are evident, some possibly representing bronchovascular markings. Interlobular lines are thickened.

## Diagnosis

Fibreoptic bronchoscopy with transbronchial biopsies is of greater value for confirming the diagnosis. Segmental large volume (200ml) bronchoalveolar lavage (BAL) is of some value in distinguishing hut lung from tuberculosis and sarcoidosis. In sarcoidosis lymphocyte percentages in the BAL fluid are generally elevated (>11%). Similar elevations in lymphocyte numbers are present in a large proportion of patients with miliary tuberculosis, but also in a minority of patients with hut lung. A common feature in hut lung is the large proportion of macrophages that contain inorganic inclusions and appear black under light microscopy. Total cell numbers are not elevated and the proportions of other inflammatory cells are not increased.<sup>2</sup>

## Conclusions

The concept of domestically acquired pneumoconiosis is not unique to South Africa, but several practices of rural lifestyle commonly practiced in South Africa contribute to the epidemic here. These include cooking with bio-mass fuels on open fires in poorly ventilated huts, grinding maize between quartz-containing rocks, pipe smoking and possibly tuberculosis. The incidence of the disease should decline over coming decades, but it remains an important diagnosis to consider in patients with interstitial lung disease, and requires differentiation from sarcoidosis, miliary tuberculosis and other diseases. Although most cases are mild, it might predispose to tuberculosis, and is often associated with areas of bronchiectasis which give rise to chronic or intermittent symptoms. Respiratory failure and death are probably rare but recognised complications. Although the HRCT has been used to define the

spectrum of changes in patients with hut lung, it does not provide an alternative to fibreoptic bronchoscopy for confirming the diagnosis.

## References

1. Palmer PES, Daynes WG. Transkei silicosis. *SAfr Med J* 1967;41:1182-8.
2. Grobbelaar JP, Bateman ED. Hut lung: a domestically acquired pneumoconiosis of mixed aetiology in rural women. *Thorax* 1991;46:334-340.
3. Hirsch M, Bar-Ziv J, Lehmann E, Goldberg GM. Simple siliceous pneumoconiosis of Bedouin females in the Negev desert. *Clin Radiol* 1974;25:507-10.
4. Tapp E, Curry A, Anfield C. Sand pneumoconiosis in an Egyptian mummy. *BMJ* 1975;ii:276.
5. Norboo T, Angchuk PT, Yahya M et al. Silicosis in a Himalayan village population: role of environmental dust. *Thorax* 1991;46:341-3.
6. Dubovsky H. Pneumoconiosis and tractor ploughing. *Medical Proceedings* 1968;14:56-59.
7. Green FHY, Yoshida K, Fick G, Paul J, Hugh A, Green WF. Characterization of airborne mineral dusts associated with farming in rural Alberta, Canada. *Int Arch Occup Environ Health* 1990;62:423-30.