

An unusual wig masquerading as calcific neurocysticercosis

WFC van Gelderen

FFRad(D)(SA)

*Consultant Radiologist, Taranaki Base Hospital,
New Zealand*

A 26-year-old black woman, who had been involved in a motor vehicle accident, was referred for radiography of the skull (Figure 1). X-rays did not demonstrate any signs of bony injury, but did reveal multiple rounded opacities related to the cranial vault, initially thought possibly to be due to calcific neurocysticercosis or alternatively multiple sclerotic bony metastases.

When the patient was examined clinically by the reporting radiologist, she was found to be wearing a most impressive and very realistic black wig with strands of hair woven around

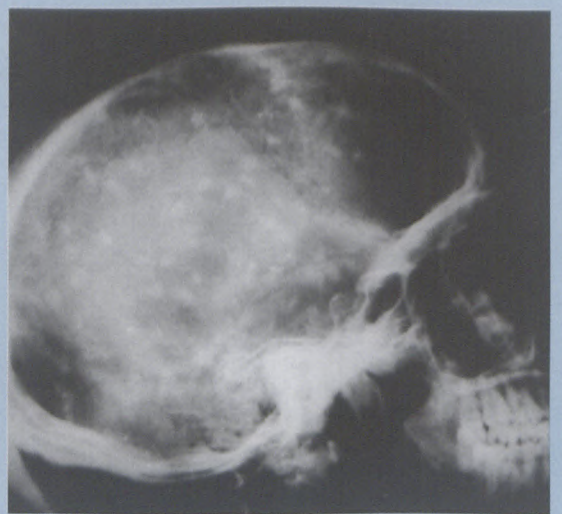


Figure 1: Lateral radiograph of the skull demonstrating multiple small opacities simulating calcific neurocysticercosis but due to tufts of hair within a wig seen end-on.

small hooks within the confines of the wig. These small hooks, containing tight knots of hair, were responsible for the multiple cranial opacities when seen end-on.

**Clinical
Magnetic
Resonance
Society**

**AMA/PRA Category 1 Accredited Course
Category A CE (ASRT) Accredited Course
1999 CMRS Annual Society Meeting**

DATE: June 24-27, 1999

VENUE: Disney's Yacht & Beach Club
Resorts, Lake Buena Vista, Florida, USA

TOPIC: Clinical Magnetic Resonance
Imaging

ATTENDEES: Physicians and
Radiologic Technologists

TECHNICAL EXHIBITS

CONTACT:

Caren Theuring

Clinical Magnetic Resonance Society

800-823-2677, 513-221-0070

Fax: 513-221-0825

Email: cmrs@one.net