

# Introduction to MR $H^1$ spectroscopy

**P Corr**

**MBChB, FFRad(D)SA, FRCR,  
MMed(UCT)**

*Professor and Head: Department of  
Radiology, University of Natal, Durban*

## Introduction

Single voxel MR spectroscopy (MRS) of hydrogen protons is a useful investigation to characterize lesions of the central nervous system. Imaging findings of mass lesions in the brain are often non-specific. Contrast enhancement indicates breakdown of the blood brain barrier and is often useful in diagnosing certain mass lesions such as meningiomas. However, many ring enhancing lesions such as abscesses, granulomas and tumours cannot be differentiated using CT or MR imaging. Single voxel spectroscopy of hydrogen protons can establish the chemical spectrum of masses and assist in their characterization.

## Methods

MRS is essentially the same process as MR imaging, only the presentation of the data obtained is different.<sup>1</sup> In MR imaging the signal obtained in the time domain is used to produce a two-dimensional image, in MRS the signal in the time domain is used to produce a frequency domain spectrum of the molecules in the

voxel.  $H^1$  protons resonate at 63.86 MHz at 1.5 T. Chemical bonds in and between molecules exist in the form of electron clouds around protons. These electron clouds have their own magnetic moment thus changing the net resonant frequency of each nucleus from its neighbour. This is called chemical shift and is the foundation of MRS. Chemical shifts are measured relative to the peak position of a reference chemical. In the brain the reference is N acetyl group of N acetyl aspartate (NAA), one of the brain's major constituents. This reference is set at 2 ppm.

Molecules that can be detected by MRS are:<sup>1</sup>

- Methyl groups  $CH_3$  - found in fatty acids, N acetyl aspartate, lactate
- Methylene groups  $CH_2$  - found in fatty acids, glutamate, creatine and glycerol
- Methyne group from alcohols found in glucose and myoinositol
- Vinyl or olefinic protons of unsaturated fatty acids

The concentration of most molecules in cells are very small while the concentration of water is very large by comparison, in the region of 10 000 to 100 000 larger. Therefore the MR spectrum is totally dominated by water and the other molecules cannot be detected. Suppression of the water spectra is necessary to visualise the other molecules by MRS. Water is suppressed by two different methods: chemical shift selective method (CHESS) or water elimination Fourier transform method.

To identify the metabolites or molecules in a single voxel, two methods are used. Stimulated echo acquisition mode (STEAM) and point resolver spectroscopy method (PRESS) can be used. Both have their advantages and

to page 13

from page 12

disadvantages. STEAM is particularly useful for detecting the spectra of fatty acids and amino acids in small concentrations while PRESS is more accurate for detecting larger metabolite concentrations such as lactate, choline and N acetyl aspartate. We use the Probe software from GE Medical Systems which is semi-automated. We find it works best using the PRESS technique where there is a better signal to noise ratio than STEAM. The voxels are 8cm<sup>3</sup> in size (2x2x2 cm). Magnetic field homogeneity is essential for good MRS. Inhomogeneity leads to molecules having slightly different spin dephasing and broadening of the spectra. This makes it difficult to differentiate spectra from different metabolites. Care must be taken in placing the voxels on the brain scan. If the voxel is too close to the skull or ventricles, field homogeneity is affected. The choice of time to echo (TE) is critical as it determines which metabolites are detected. Amino acids, long chain fatty acids and myoinositol are best detected at a short TE around 20 msec while choline and NAA and lactate at a long TE of around 270 msec. Lactate has a double peak at TE of 135 msec and 270 msec due to a phenomenon called J coupling.

## Normal spectrum (Figure 1)

NAA is the main peak at 2 ppm. This is due to the acetyl group and is a measure of neuronal density and viability.<sup>2</sup> Any pathological process where neurones die will decrease the NAA peak. The next largest peak is due to creatine. This is a marker of energy metabolism within neurones and is diminished in malignant tumours. It is found at 3.03 ppm. Choline at 3.2

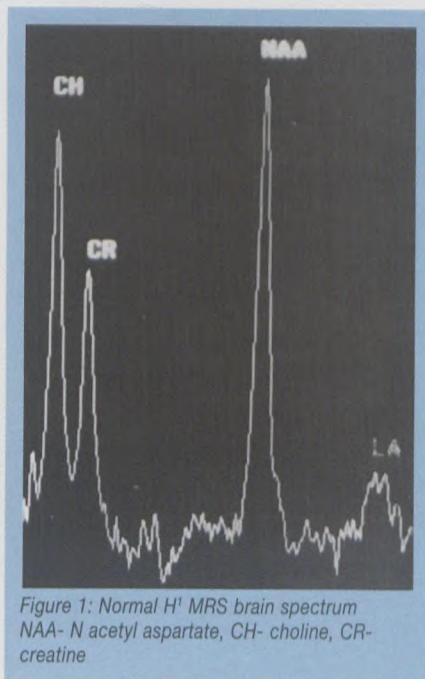


Figure 1: Normal H<sup>1</sup> MRS brain spectrum  
NAA- N acetyl aspartate, CH- choline, CR- creatine

ppm is a building block of neuronal cell membranes and is an indicator of cell membrane turnover. It is increased in all tumours. Lactate is detected at 1.32 ppm. Normally lactate is not found. Lactate is present in anaerobic glycolysis where there is reduced blood oxygen and is seen when lesions outgrow their blood supply or if there is ischaemia. With STEAM, metabolites with short relaxation times such as myoinositol at 3.56 ppm and alanine can be detected. They are involved in neurotransmitter production.

## Multiple volume MRS

Multiple volume MRS is used to determine spectra from multiple voxels in the brain. This is also called chemical shift imaging (CSI). This allows comparison of spectra for multiple regions of a tumour especially on treatment. This is in one,

two and three dimensions and both PRESS and STEAM methods can be used.<sup>3</sup>

## Applications of single voxel MR spectroscopy (MRS)

MRS using the single voxel technique is useful in characterising intracerebral masses. We have used it successfully in patients with AIDS to determine whether lesions were inflammatory or neoplastic before considering treatment. Neoplasms will cause an elevated choline peak due to increased cell membrane production but decreased N acetyl aspartate and

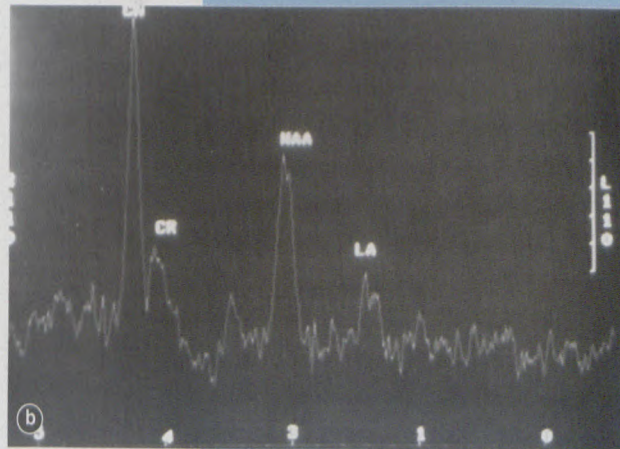
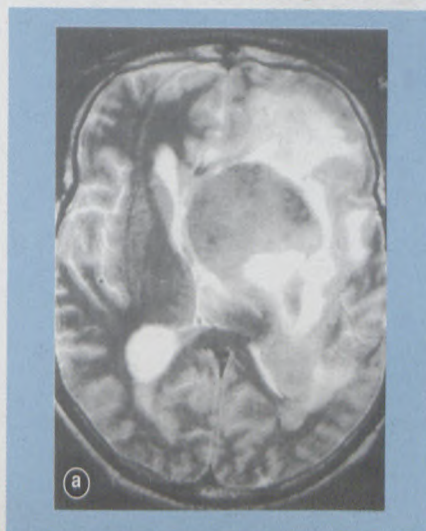


Figure 2a, b: Single voxel H<sup>1</sup> spectroscopy of non-Hodgkin's lymphoma of the left basal ganglia demonstrates an elevated choline peak and diminished NAA and creatine

from page 13

creatine peaks from destruction of neurones. Occasionally elevated lactate peak in areas of ischaemia are detected within the tumour. Choline peaks are highest in tumours with high cellularity such as lymphoma and primitive neuroectodermal tumours such as medulloblastoma (Figure 2). MRS is useful in evaluating tumour response to radiotherapy or chemotherapy by monitoring peaks. MRS in particular can distinguish between recurrent tumour and gliosis.<sup>4</sup> Recurrent tumour will

demonstrate elevated choline peaks while gliosis will show depression of all metabolite peaks.

Inflammatory lesions will have decreased NAA and creatine levels and increased lactate from anaerobic glycolysis. Both tuberculomas, pyogenic and toxoplasma abscesses often have markedly elevated lactate

## Conclusions

MRS is a relatively new technique that provides additional information that is useful in the treatment of many patients with brain tumours, inflammatory diseases, metabolic disorders and demyelination.

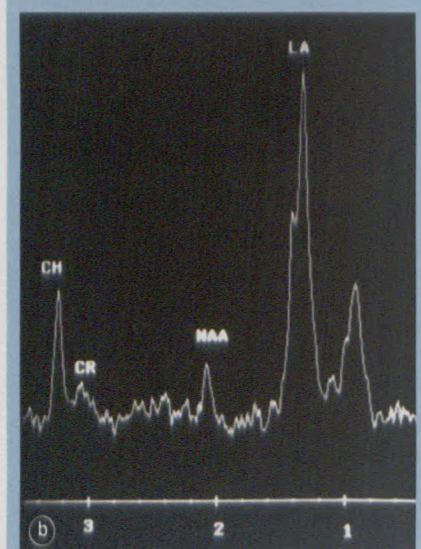
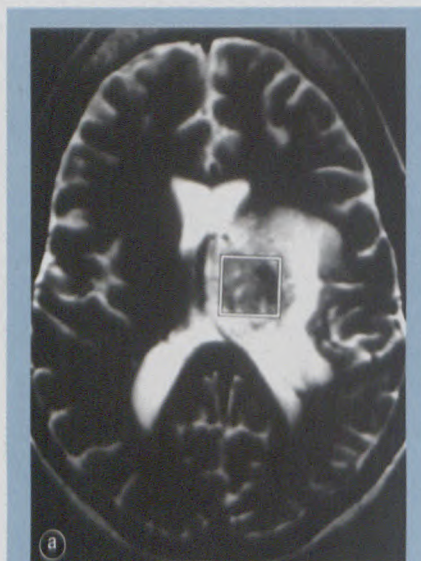


Figure 3a, b: Single voxel H<sup>1</sup> spectroscopy of a left basal ganglia tuberculoma demonstrates a markedly elevated lactate peak and diminished NAA and choline peaks using PRESS technique

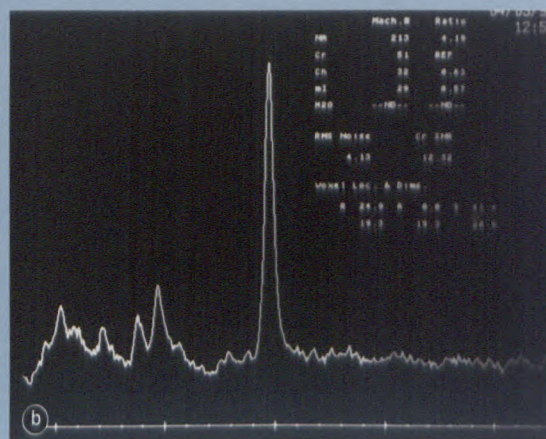
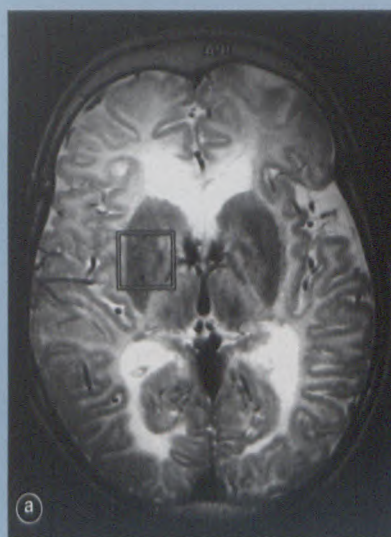


Figure 4a, b: Single voxel H<sup>1</sup> spectroscopy of a 9-year-old child's brain with advanced Canavan's Disease with marked white matter hyperintensity and cerebral atrophy. MRS shows markedly elevated NAA peak typical of this disorder

peaks (Figure 3).<sup>5</sup> Tuberculomas also have elevated levels of lipids and fatty acids, best detected on STEAM sequences. Recent work shows that MRS is useful for differentiating cerebral abscesses from necrotic tumour.<sup>6</sup>

MRS has an important role in the diagnosis and monitoring the treatment response in certain metabolic brain disorders in children. These include disorders of lipid metabolism such as adrenal leukodystrophy, mitochondrial disorders (Leigh's Disease), and white matter disorders (Canavan's Disease)<sup>7</sup> (Figure 4).

## References

1. Kwok L. Localised MR spectroscopy. *Neuroimaging Clin of N America* 1999;8:713-731.
2. Castillo M, Kwok L. Proton MR spectroscopy of common brain tumours. *Neuroimaging Clin of N America* 1999;8:733-752.
3. Salibi N, Brown M. In: *Clinical MR spectroscopy*. 1998. John Wiley, New York.
4. Castillo M, Kwok L. Proton MR spectroscopy of common brain tumours. *Neuroimaging Clin N America* 1998;8:733-752.
5. Cecil K, Lenkinski R. Proton MR spectroscopy in inflammatory and infectious brain disorders. *Neuroimaging Clin N America* 1998;8:863-880.
6. Grand S, Passaro G, Ziegler A, et al. Necrotic tumour vs brain abscess: importance of amino acids detected at H<sup>1</sup> spectroscopy- initial results. *Radiology* 1999;213:785-793.
7. Wang Z, Zimmerman R. Proton MR spectroscopy of paediatric brain disorders. *Neuroimaging Clin N America* 1998;8:781-807.