

Barium peritonitis with barium entering the lymphatic system

S. Andronikou
FC Rad Diag (SA)

C. Welman
MBChB

E. Kader
MBChB

Department of Paediatric Radiology,
University of Cape Town and Institute of Child
Health, Red Cross War Memorial Children's
Hospital, Rondebosch, Cape Town

Corresponding author
S. Andronikou
Department of Paediatric Radiology
Red Cross War Memorial Children's
Hospital
Cape Town
7700

Telephone: 021-6585442
Fax: 021-6585101
E-mail: docsav@mweb.co.za

Abstract

Barium is still widely used in developing countries for gastrointestinal investigation because it is cheap and relatively safe. Most institutions however favour low-osmolar non-ionic contrast media for performance of childhood diagnostic enemas. These are relatively expensive and many developing countries reserve their use for cases where perforation is suspected. We present a case where barium leaked into the peritoneum during an enema investigation where no initial features of perforation were present. The added unique complication of barium entering the

thoracic lymphatic system was noted. This complication was not found in a review of current literature.

Key words

Barium enema, low-osmolar non-ionic contrast media, complications.

Case report

A 10-day-old neonate was delivered prematurely at 29 weeks gestation weighing 1060 grams. He was referred to the radiology department for a barium enema examination with the diagnosis of small bowel atresia. The clinical evaluation revealed abdominal distention and plain film radiology showed proximally dilated small bowel with absent distal gas. No features of bowel perforation were present on this series. The objective of the study was to demonstrate any co-existing colonic strictures as these are difficult to assess at laparotomy. Barium is still used as a contrast medium for enemas, when no bowel perforation is suspected, in countries where there are cost constraints on the use of low-osmolar non-ionic agents. The examination showed no colonic strictures, but barium flowed freely into the peritoneal cavity from the ileocaecal junction. The patient was taken immediately to laparotomy. The surgeon found a necrotic terminal ileum and a large amount of free barium in the peritoneal cavity. Small bowel resection and re-anastomosis was performed and vigorous peritoneal washout was undertaken. Subsequent chest and abdominal radiographs (Figures 1 and 2) demonstrated

to page 16

DON'T COME TO OUR BANK

We would much rather come and see you.

MLS Bank, as South Africa's only specialist Medical Bank, enables you to concentrate on building a profitable practice by bringing the bank to you and telling you about the wide range of specialised products and services we offer. So, if you are looking for Equipment, Vehicle, Home, Project or Practice Financing, backed by a quarter of a century of experience and know-how in medical and dental markets, contact our Client Service Line on 0860 205060 - when it's convenient to you, of course.



MLS BANK

We bring the bank to you

from page 14

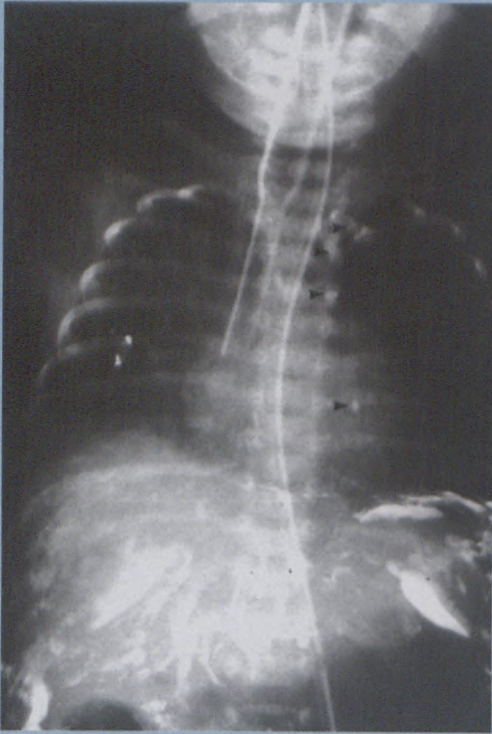


Figure 1: Post-operative anterior-posterior chest radiograph demonstrates barium coating the peritoneal surface and located as several foci along the left sternal border (arrowheads).

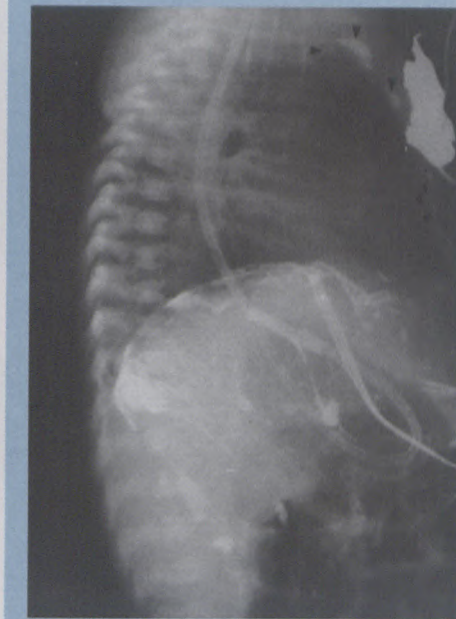

Figure 2: Post-operative lateral chest radiograph confirms the retrosternal position of the barium (arrowheads) in keeping with its drainage via the internal thoracic lymphatic chain.

barium tracking along the retrosternal part of the chest and at the thoracic duct. This represented barium entry into the internal thoracic chain of lymph nodes. At the time of this report the patient's condition was stable.

Discussion

Bowel perforation is reported to occur in 0.02-0.04% of patients undergoing barium investigations of the large bowel.¹ In the USA adult litera-

ture, 500 perforations during barium enema examination have been reported in a year, but these figures were obtained over 30 years ago.² Most perforations are a result of the catheter tip at the ano-rectal portion of the bowel.¹ Fatal complications have been described and some collective series report a figure of 50% mortality. Others claim such figures are outdated and give lower figures such as 20% mortality. Some authors report even lower mortality due to more effective and efficient staff training.³⁻⁵

Williams *et al* outline the recognised complications of intraperitoneal bowel perforation during barium enema investigations. These include intravascular volume depletion, sepsis, adhesions and peritoneal fibrosis. Other reported complications are intramural intravasation, barium impaction, allergic reaction and cardiac arrhythmia.¹ We have found no reports in the current literature of barium entering the lymphatic system after intraperitoneal spill and this is reported as a unique feature.

References

1. Williams *et al*. Recognition and prevention of barium enema complications. *Curr Probl Diagn Radiol* 1991; 20(4): 123-151.
2. Cordon *et al*. Rectal perforation during barium enema. Report of a case. *Dis Colon Rectum* 1988; 31(7): 563-569.
3. Rimarenko *et al*. Fatal complications related to diagnostic barium enema. *Am J Forensic Med Pathol* 1988; 9(1): 78-84.
4. Grobmeyer *et al*. Barium peritonitis. *Am Surg* 1984; 50(2): 116-120.
5. Hardy *et al*. Survival after colonic perforation during barium enema examination. Modified radical surgical debridement. *Dis Colon Rectum* 1983; 26(2): 116-118.
6. Eklof *et al*. Barium peritonitis. Experience of five paediatric cases. *Paediatr Radiol* 1983; 13(1): 5-9.