

Magnetic resonance features of intracranial tuberculosis in children

S Andronikou

MBBCh (Wits), FCRadDiag, FRCR (Lond)

E Kader

MBChB

C J Welman

MBChB

*Department of Paediatric Radiology,
University of Cape Town and Institute of Child
Health,*

*Red Cross Children's Hospital,
Rondebosch, Cape Town*

Corresponding author

Dr Savvas Andronikou

*Department of Paediatric Radiology, University of
Cape Town and Institute of Child Health, Red Cross
Children's Hospital, Rondebosch, Cape Town, 7700*

Tel: (021) 658-5422. Fax: (021) 658-5101.

E-mail: docsav@mweb.co.za

Abstract

Intracranial tuberculosis in children is seen as either parenchymal tuberculous lesions or tuberculous meningitis (TBM). This article demonstrates the MR features of TBM and the two varieties of tuberculous (TB) granulomata. Gummatous granulomata (tuberculomata) comprise 90% of presenting intracranial TB lesions. They have a characteristic low signal on T2-weighted sequences that differentiates them from other commonly encountered ring-enhancing lesions such as neurocysticerci. TB abscesses are very rare and have the same

features as pyogenic abscesses. Features of TBM include hydrocephalus, basal meningeal enhancement and basal ganglia infarctions.

Introduction

The Western Cape has one of the highest incidences of intracranial TB in the world. This may take the form of TBM where the patient presents with a decreased level of consciousness, cranial nerve palsies and hemiplegia.¹ In contrast, intracranial granulomata usually manifest with seizures.² This article demonstrates the MR imaging features of these forms of intracranial TB.

Discussion

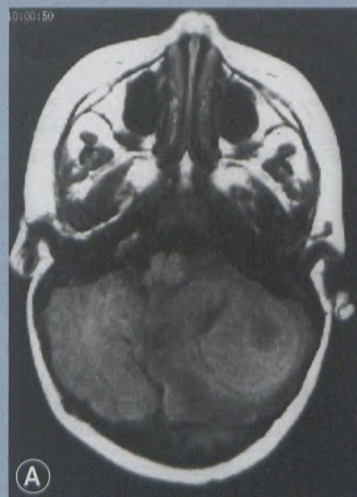
In areas endemic for intracranial TB, neurocysticercosis may also be endemic² and is regarded as a more common cause for childhood seizures. The management of these two entities differs and it is therefore crucial to differentiate between them,² especially as current anti-TB therapy has significant side-effects. Not only is MRI more sensitive in detecting lesions, but it is also able to differentiate the more common type of TB granuloma from a neurocysticercus.

Tuberculomata (gummatous granulomata) comprise approximately 90% of intracranial TB lesions and are hypointense on T2-weighted sequences¹⁻⁵ (Figure 1). Neurocysticerci, in contrast, are T2 hyperintense.^{2,4} The T2 imaging characteristics are, however, not pathognomonic of TB, as syphilis² and densely cellular neoplasms such as germinomas and P-NETs (medulloblastomas) can

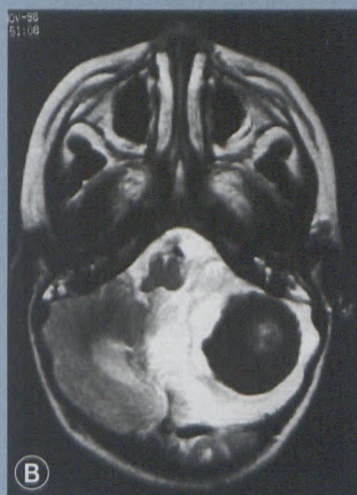Magnetic resonance features of intracranial tuberculosis in children

from page 10

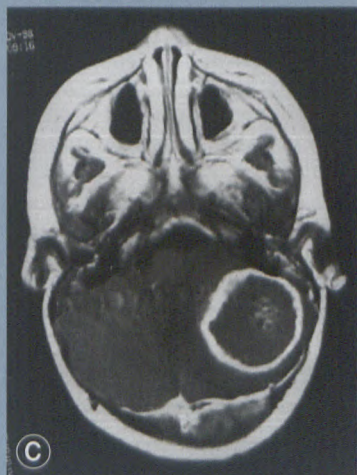
Figure 1: Gummatous granuloma/tuberculoma



a. T1-weighted MR shows a left-sided cerebellar lesion that is isointense to brain

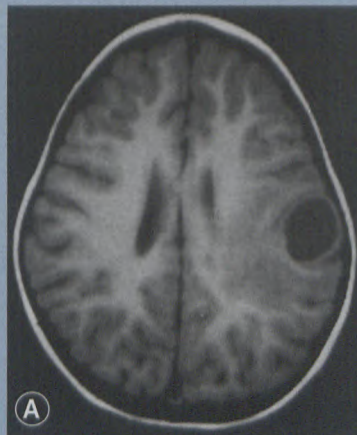


b. T2-weighted image shows a lesion that is hypointense to brain and is surrounded by high-signal oedema

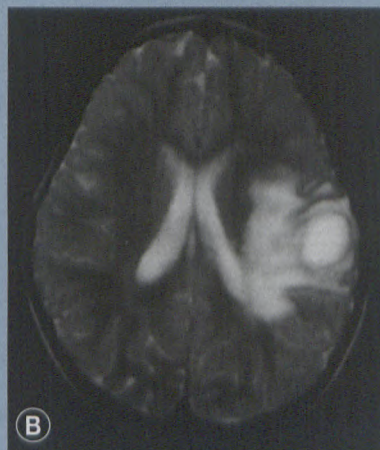


c. T1-weighted post-gadolinium MR shows ring enhancement of the lesion

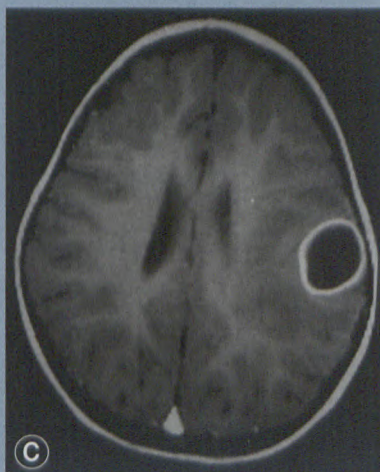
Figure 2: Tuberculous abscess



a. T1-weighted image shows a left parietal lesion that is hypointense to brain



b. T2-weighted MR shows a lesion that is hyperintense to brain with surrounding high signal representing oedema



c. T1-weighted post-gadolinium image shows ring enhancement of the lesion

also be hypointense on T2-weighted images.⁶ The latter entities, however, can frequently be excluded, as they have additional imaging characteristics

and do not show typical ring enhancement with gadolinium.

TB abscesses are relatively rare (Figure 2). Pathologically they contain liquefied or caseous material that differentiates them from the gummatous material seen in tuberculomata (gummatous granulomata).^{2-5,7} They are inseparable on MR imaging from neurocysticerci, cystic neoplasms and fungal and pyogenic abscesses, which are all T2 hyperintense.¹⁻⁵

Granulomata may occur in clusters or may exist simultaneously in multiple sites.⁵ When granulomata abut the meningeal surface, they may rupture into the meninges and cause TBM² (Figure 3).

The classic triad of TBM is basal meningeal enhancement, hydrocephalus and basal ganglia infarction.² The most consistent finding in TBM is hydrocephalus.^{1,2,8} Basal meningeal enhancement is often very pronounced (Figure 4a), but can also be seen in bacterial meningitis and may sometimes be absent in confirmed cases of TBM.¹ Angiitis of the small vessels passing through the inflamed meninges can lead to infarctions in the basal ganglia region (Figures 4b and 4c). It is these infarcts that determine the morbidity and mortality associated with TBM.^{1,2,5} MRI is more sensitive than CT in detecting basal meningeal enhancement as well as the infarctions. The infarcts have a low signal on T1 and are T2 hyperintense, while tuberculomata are isointense on T1 and hypointense on T2. Tuberculomata are only found in 10% of cases of TBM.²

Conclusion

MRI can differentiate TB granulomata from neurocysticerci and other ring-enhancing lesions. This has a significant impact on therapy and avoids

to page 12

Magnetic resonance features of intracranial tuberculosis in children

from page 11

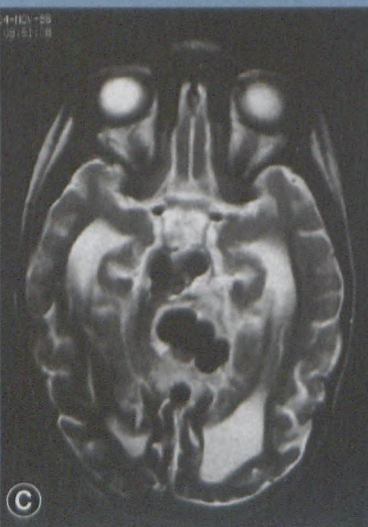
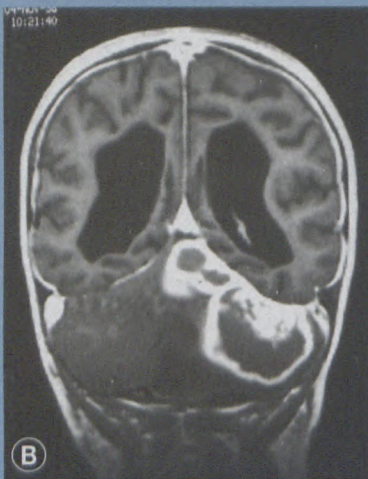
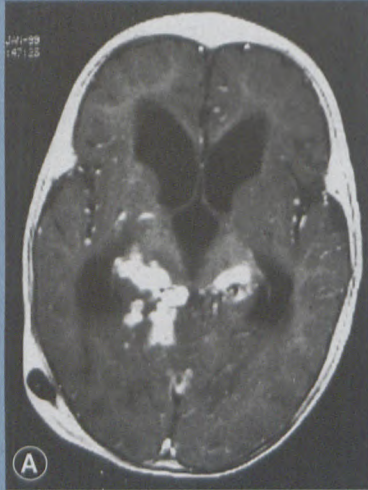
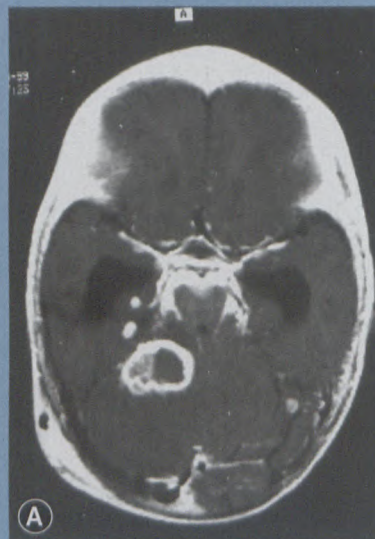


Figure 3: Clusters and multiple granulomata: Clusters of granulomata are seen abutting the basal meninges

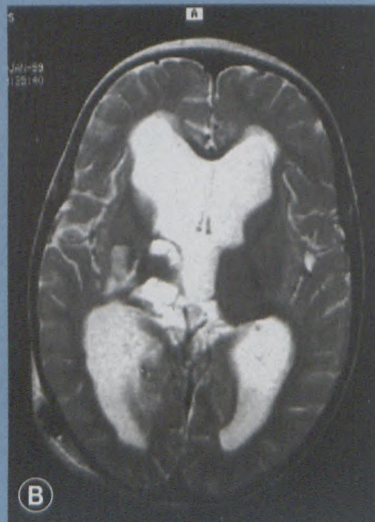the unnecessary use of potentially harmful medication. The detection of TBM and associated infarcts is improved.

In our population, where the incidence of TB is very high, the clinical suspicion of intracranial TB, in the appropriate clinical setting, is always high. It is important to note that there is no single diagnostic feature of in-

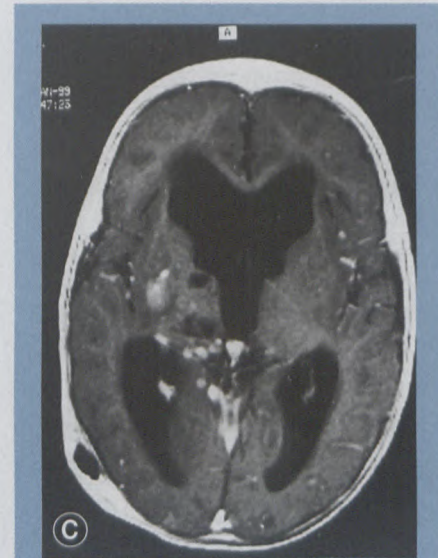
Figure 4: TBM and its complications



a. T1-weighted post-gadolinium MR demonstrates basal meningeal enhancement, dilated temporal horns indicating hydrocephalus and a cerebellar tuberculoma



b. T2-weighted image demonstrates hydrocephalus and areas of infarction in the right basal ganglia region



c. T1-weighted post-gadolinium MR demonstrates hydrocephalus and basal ganglia infarcts

tracranial TB and the diagnosis should be based on a combination of imaging characteristics, clinical findings and laboratory data.²

Acknowledgements

We would like to thank Helen Tomazos and Medical Graphics for their help in the preparation of this article.

References

1. Schoeman J, Hewlett R, Donald P. MR of childhood tuberculosis meningitis. *Neuroradiology* 1988; 30: 473-477.
2. Jamieson DH. Imaging intracranial tuberculosis in childhood. *Pediatr Radiol* 1995; 25: 165-170.
3. Gupta RK, Pandey R, Khan EM, Mittal P, Gujral RB, Chhabra DK. Intracranial tuberculomas: MRI signal intensity correlation with histopathology and localised proton spectroscopy. *Magn Reson Imag* 1993; 11: 443-449.
4. Gupta RK, Jena A, Singh AK, Sharma A, Puri V, Gupta M. Role of magnetic resonance (MR) in the diagnosis and management of intracranial tuberculosis. *Clin Radiol* 1990; 41: 120-127.
5. Salgado P, Del Brutto OH, Talamaso O, Zenteno MA, Rodriguez-Carbajal J. Intracranial tuberculoma: MR imaging. *J Neuroradiology* 1989; 31: 299-302.
6. Barkovich AJ. *Pediatric neuroimaging*. Baltimore: Lippincott-Raven. 1996: 331, 397.
7. Whitener DR. Tuberculous brain abscess. *Arch Neurol* 1978; 35: 148-155.
8. Waecker Jr NJ, Connor JD. Central nervous system tuberculosis in children: A review of 30 cases. *Pediatr Infect Dis J* 1990; 9: 539-543.