

A case of popliteal artery entrapment

P A Scheepers

MB ChB

N Khan

MB BS, FCRad (D) SA

W J N Vermeulen

MB ChB

*Department of Diagnostic Radiology
Medical University of Southern Africa*

This case report involves a 31-year-old fit, active man who was an enthusiastic runner. He had no history of smoking. The patient presented with a 3-year history of gradual-onset, progressive pain and numbness in both lower legs and feet when running. He had tried changing running gear, cutting down on his distances and even resting for a period of time. A sports physician diagnosed bilateral compartment syndrome. Biokinetics proved futile and the patient was booked for bilateral decompressions of the anterior compartments. Following the procedure he had a year's remission. Over the next 2 years his symptoms worsened to the extent that he had trouble climbing stairs and walking on the golf course. A vascular surgeon requested a conventional angiogram which showed normal popliteal arteries in the neutral position (Fig. 1) but total occlusion of both popliteal arteries with plantar flexion (Fig. 2). A diagnosis of popliteal artery entrapment was made and the patient was booked for decompression.

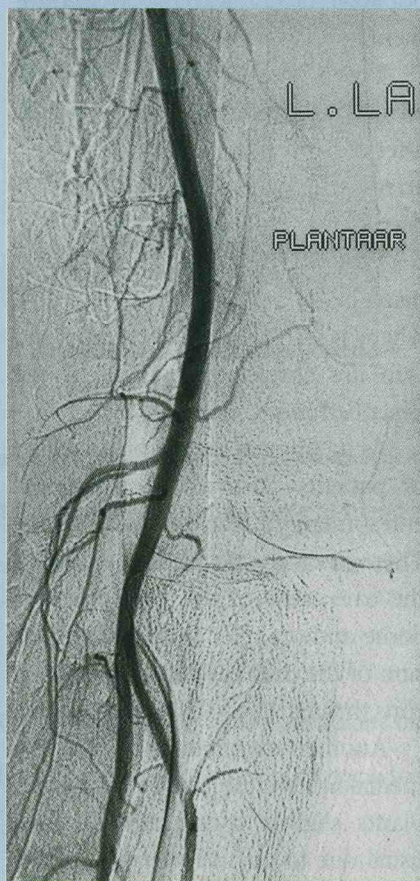


Fig. 1. Conventional angiography showing normal flow in the popliteal artery in the neutral position.

Embryology

At 5½ weeks gestation the gastrocnemius muscle develops from the muscular blastema and grows from the calcaneus cephalad to implant on the femoral epicondyles. The lateral head attaches first to the lateral epicondyle. The medial head lags behind and grows medially to attach itself higher than the lateral head on the medial epicondyle.

During this time the popliteal artery develops from the union of the

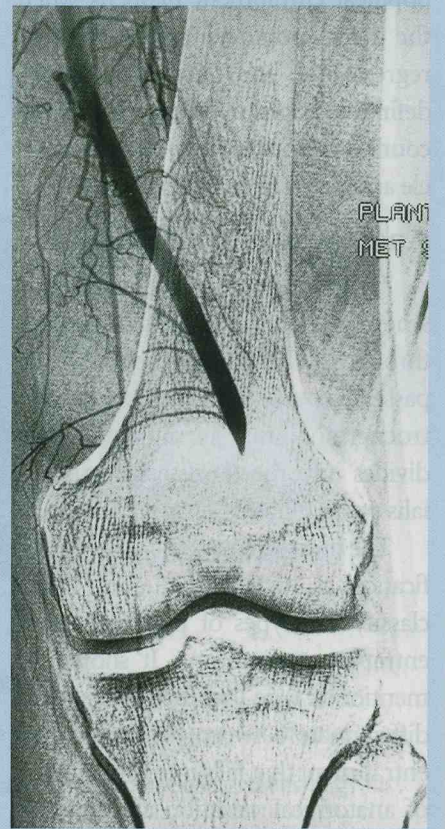


Fig. 2. Conventional angiography showing complete cut-off of the popliteal artery during forced plantar flexion.

terminal end of the sciatic artery called the deep popliteal artery and the superficial popliteal artery. The part of the deep popliteal artery that develops posterior to the popliteus muscle regresses. The superficial popliteal artery unites with the remainder of the deep popliteal artery to form the definitive popliteal artery at the knee.¹

Anatomical variations arise when the migration of the medial head of the gastrocnemius from lateral to medial in the popliteal fossa catches the developing popliteal artery. If the true popliteal artery is already formed when the medial head develops and moves medially it can take the popliteal artery with it. Variations of this cause the different types of popliteal entrapment. Another type of

popliteal entrapment happens when the deep popliteal artery fails to regress and ends up forming the definitive popliteal artery which then courses anterior to the popliteus muscle and can lead to the entrapment.¹

Anatomical classification

The popliteal artery originates when the femoral artery passes through the adductor canal. It then passes through the heads of the gastrocnemius and terminates as it divides into the tibialis anterior, tibialis posterior and peroneal arteries.

The literature uses the same classification as Rich and Hughes.² They classify five types of popliteal artery entrapment syndrome. It should be mentioned here that firstly we should differentiate between popliteal artery entrapment that falls into the category of anatomical variation and another group that has no apparent anatomical variation. This is termed functional popliteal artery entrapment, which will be discussed later.

Type 1. The popliteal artery is already completely formed when the medial head migrates to the medial epicondyle. The popliteal artery is swept medially. The medial head of the gastrocnemius inserts in its usual position but the popliteal artery then runs medial and deep to the medial head.

Type 2. The migration of the medial head is partially restrained by an already formed popliteal artery. This results in a more lateral insertion of the medial head with a popliteal artery that runs closer to its usual path but still medial and deep to the medial head of the gastrocnemius muscle.

Type 3. The popliteal artery forms at the same time as the migration of the medial head of the gastrocnemius.

This results in a popliteal artery that courses within the medial head of the gastrocnemius. The medial head of the gastrocnemius muscle now has an accessory head or slip of muscle fibre that runs laterally and straddles the popliteal artery leading to entrapment.

Type 4. As discussed previously we are dealing here with a persistent axial artery forming the definitive popliteal artery which now runs anterior or deep to the popliteus muscle.

Type 5. This entity is not recognised by all authors but is described where both the popliteal artery and vein are entrapped by any of the described mechanisms.^{1,3,4}

As mentioned there is also a group of patients classified as functional entrapment of the popliteal artery. There is much speculation regarding the true cause of this phenomenon. Some authors refer to it as compression of the distal popliteal artery as it runs through the soleal muscle sling.

Another explanation is that the medial head of the gastrocnemius implants slightly more laterally than usual due to normal variation of the migration process. A popliteal artery with a normal course would then run in very close proximity to the medial head of the gastrocnemius which inserts almost on the posterior aspect of the medial epicondyle. This has been supported by evidence that almost half of the totally asymptomatic population will have partial or total occlusion of the popliteal artery with extremes of plantar flexion or dorsiflexion against resistance. An athlete or physically active person who does a lot of lower leg exercise would then get hypertrophy of the medial head and that could lead to entrapment.^{3,4}

These findings raise an interesting point. In the case under discussion the patient's symptoms were probably misdiagnosed as compartment syndrome, which is much more common. The above findings suggest that the reverse can also happen. In fact the authors of the studies in my references have been criticised by some for diagnosing popliteal entrapment where in fact the patient could have compartment syndrome. This is discussed again below.

Imaging

A diagnosis of popliteal artery entrapment can be confirmed with: Doppler scan ankle pressures, pulse volume recordings, duplex Doppler scanning, computerised tomography (CT), CT angiography, magnetic resonance imaging (MRI), MR angiography, and conventional angiography.

When performed properly, angiography remains the gold standard. With the first three imaging modalities the principle remains more or less the same. They are all used to demonstrate the presence versus absence of flow in the dorsalis pedis or tibialis posterior arteries during manoeuvres that tighten the gastrocnemius muscles such as knee extension, dorsiflexion of the ankle or active plantar flexion against resistance.

On Doppler ultrasound one may also be able to detect a thrombus in the popliteal artery if the patient presents with acute limb ischaemia. This can be the result of undiagnosed popliteal entrapment due to damage to the intima. Even those patients who do not present with acute limb ischaemia have been shown to present with a filling defect at the time of angiography. Obviously these young and active patients can develop a very

rich collateral supply.

In the case of the patient under discussion Doppler ultrasound and then conventional angiography were used to confirm the diagnosis. After access through the femoral artery contrast injections were done in both femoral arteries at rest and then with active plantar flexion, as shown in Figs 1 and 2. The picture shows occlusion of the popliteal artery during plantar flexion (Fig. 2).

CT and MRI or angiography may be done but both of these modalities are not used as often due to factors such as cost and accessibility.

This is unfortunate because especially MRI will demonstrate anatomical variation very well.⁵ In cases where anatomical variation is not demonstrated with these modalities we could then assume a functional entrapment. We would also be able to evaluate for any signs of a filling defect using these modalities.

If there are no signs of anatomical variation or a thrombus in the popliteal artery we need to reassess and make sure we are not dealing with compartment syndrome. One can then suggest further investigation such as measuring the pressures in the compartment under strain.³

Treatment

Once the diagnosis of popliteal artery entrapment is confirmed

surgery is indicated. Chronic untreated popliteal artery entrapment can lead to intimal damage of the popliteal artery with thrombosis and possible acute limb ischaemia. Surgical treatment is based on the condition of the popliteal artery. If there is no damage to the intima and thromboses present the procedure of choice is decompression of the popliteal artery.

If a type 1, 2 or 3 entrapment is found during operation the entire medial head of the gastrocnemius muscle, both the muscular and the tendinous portions will be divided as well as any other fibrous bands or muscle slips.

If no anatomical variation or a functional entrapment is found during operation the medial head of the gastrocnemius is cut sparing the tendon. Thus only the muscular portion is divided.

If there is any damage to the intima or there is a thrombus found in the popliteal artery a popliteal artery bypass is done with a medial approach to facilitate saphenous vein harvesting.^{4,5}

Discussion

Popliteal artery entrapment should always be included as a differential diagnosis in a patient under the age of 40 years who presents with symptoms of claudication.

Invariably these patients will come to us for any of the imaging modalities, especially for angiography. If you don't find any other cause or claudication views with plantar flexion or dorsiflexion of the foot will be a useful addition.

Although at present magnetic resonance angiography (MRA) is still expensive it should be kept in mind as an excellent imaging modality for this condition. It can give a lot of information regarding the anatomical variation as well the condition of the popliteal artery.

Lastly it should be kept in mind that if the evidence for a suspected popliteal artery entrapment is not conclusive, compartment syndrome can give similar symptoms and is much more common than popliteal artery entrapment.

References

1. White RA, Hollier H. Entrapment syndromes. In: Donayre CE, White R, Hollier H, eds. *Vascular Surgery: Basic Science and Clinical Correlations*. Philadelphia: JB Lippincott, 1994: 207-214.
2. Rich NM, Hughes CW. Popliteal artery and vein entrapment. *Am J Surg* 1967; **113**: 696-698.
3. Rutherford RB. Popliteal artery entrapment. In: Fowl RJ, Kempezenski RF, Whelan TJ, eds. *Vascular Surgery*. Philadelphia: WB Saunders, 1995: 889-894.
4. Levien LJ, Veller MG. Popliteal artery entrapment syndrome: More common than previously recognized. *J Vasc Surg* 1999; October: 588-596.
5. Moore WS. Nonatherosclerotic vascular disease. In: Ahmed M, Abou-Zamzam jun, Edwards JM, Porter JN, eds. *Vascular Surgery: A Comprehensive Review*. Philadelphia: WB Saunders, 1998: 132-134.