

# A case of idiopathic hypertrophic pachymeningitis

**C Minné**

MB ChB, Dip Emerg. Care (SA)

**N Khan**

MB BS, FCRad (D) SA

Department of Diagnostic Radiology  
Medical University of Southern Africa

## Introduction

Hypertrophic cranial pachymeningitis (HCP) is a rare disease marked by localised or diffuse thickening of the dura mater. The aetiology is unclear, but several factors have been identified as possible causes. The most common causes include infections and granulomatous diseases. Less common causes include meningeal carcinomatosis and idiopathic HCP. Most patients present with a main complaint of headache.<sup>1-3</sup> Other symptoms and signs are quite variable.

## Case report

A 31-year-old male patient presented at the neurology clinic with a 4-week history of visual aura (bright flashes of light), followed by complex partial seizures with secondary generalisation. He also complained of right-sided recurrent headaches of 3 months' duration, which were worse at night and of throbbing nature. There was no associated vomiting. Visual acuity was impaired (both eyes 20/25). No other systemic symptoms could be elicited. Examination revealed brisk deep tendon reflexes in

all the limbs. Fundoscopy was normal and no other cranial nerve palsies could be demonstrated. Other systems were normal and no skin lesions could be found. There was also no lymphadenopathy detected.

## Blood test results

Full blood and differential count, glucose, urea, creatinine and electrolytes were all normal. HIV, rapid plasma reagin (RPR) and treponema pallidum haemagglutination (TPHA) tests were non-reactive. Serum angiotensin converting enzyme (ACE) was low at 3 U/l (range 8 - 52 U/l). Toxoplasma immunoglobulin G (IgG) and immunoglobulin M (IgM), and cryptococcal serology were all negative.

## Cerebrospinal fluid (CSF) test results

The appearance of the CSF was clear and colourless. Biochemistry and CSF ACE were normal. Four lymphocytes and four erythrocytes were seen under microscopy, and no polymorphs or bacteria could be found. Cryptococcal latex and Indian ink tests were negative, as were tests for *Neisseria meningitidis* A, C, Y, W135 and streptococcus pneumoniae. No parasites were seen. Cultures yielded no growth. No malignant cells were identified.

## Chest X-ray

Chest X-ray was normal with no evidence of hilar lymphadenopathy.

## Computed tomography (CT) scan of the brain

A CT scan of the brain was requested to exclude the possibility of a space-occupying lesion. The CT scan showed multiple areas of localised dural thickening, which were hyperdense on the precontrast study (Fig. 1). These enhanced markedly after contrast administration (Fig. 2). The areas of involvement included the anterior and posterior falx cerebri, tentorium cerebelli and dura mater over the right parieto-occipital and frontal lobes. An area of white matter hypodensity could be seen in the right occipital lobe adjacent to the area of thickened dura mater (Figs 1 and 2). The diagnosis of HCP was considered, with the possible differentials being infection, neurosarcoidosis and dural carcinomatosis.

## Magnetic resonance imaging (MRI)

The dura mater overlying the right parieto-occipital area, anterior and posterior parts of the falx cerebri as well as right tentorium showed very low signal on T2-weighted (Fig. 3) and FLAIR sequences. The T1

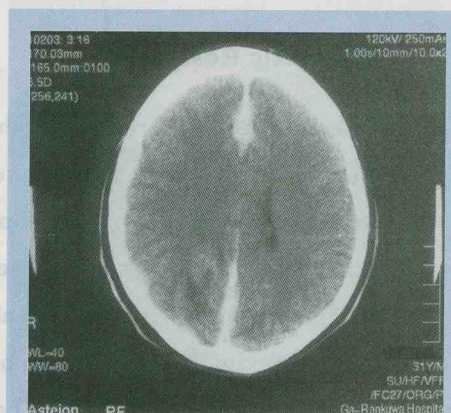


Fig. 1. Non-enhanced CT brain scan showing thickened hyperdense falx cerebri and dura mater overlying the right occipital and parietal areas as well as bifrontally. A hypodense area can be seen in the right occipital lobe.

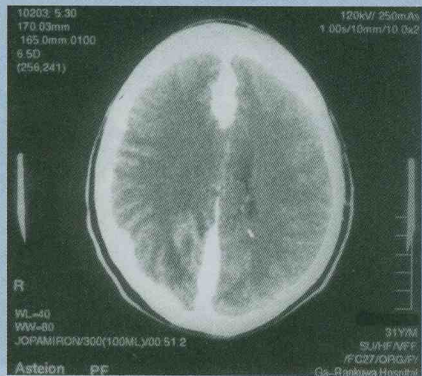


Fig. 2. Post-contrast CT brain scan at the same level as Fig. 1 demonstrates dense enhancement of the affected dura.

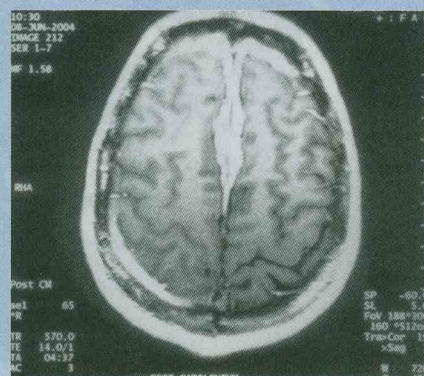


Fig. 5. Axial post-gadolinium T1-weighted image demonstrates the dense enhancement of the suspicious areas noted in Fig. 4.

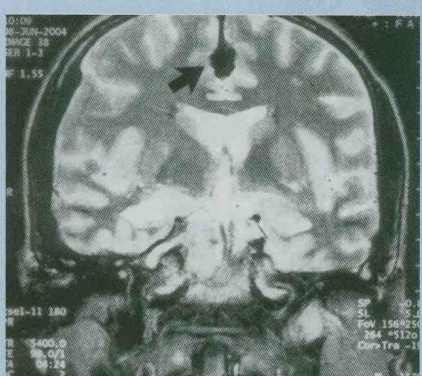


Fig. 3. Coronal T2-weighted sequence demonstrating the very low signal of the thickened falx cerebri and tentorium on the right.

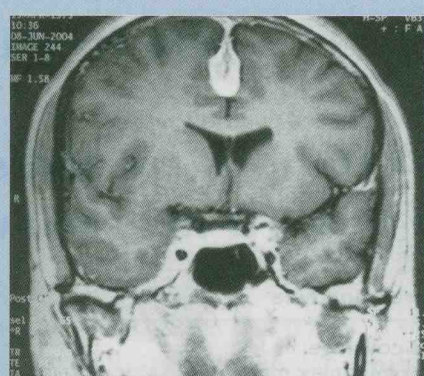


Fig. 6. Post-gadolinium T1 sequence coronal image showing dense peripheral enhancement compared with the centre.

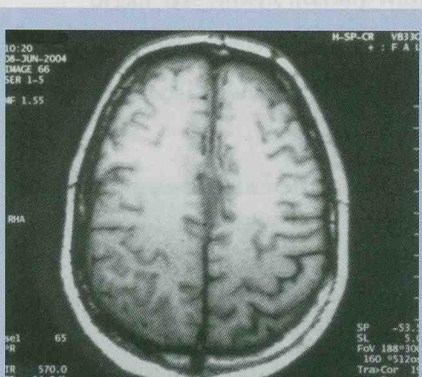


Fig. 4. Axial T1-weighted image shows possible hypointense thick falx which is almost iso-intense to the cortex.

sequence of these areas was iso-intense to the cortex (Fig. 4). No CSF was noted in these areas. The periphery of these lesions showed dense enhancement post contrast on T1

weighted images compared with the central portions (Figs 5 and 6). The medial aspect of the right occipital lobe showed high signal in the cortical/subcortical distribution on T2-weighted sequences and on FLAIR images. This same area was hypointense on the T1 sequence.

## Surgery

A biopsy was taken via a right posterior parieto-occipital craniotomy.

A yellowish-grey thick rubber-hard process was found, and was seen extending through the dura onto the adjacent bone. No underlying bone invasion was noted. The small veins draining to the straight sinus were encased by hard fibrotic tissue. Tissue was sent for microscopy, culture and

sensitivity (MCS) and histological examination.

## Histological examination

Histological examination revealed extensive fibrosis and large aggregates of lymphocytes. Plasma cells and elongated histiocytes were also noted in the lymphocyte infiltrate. A few scattered poorly formed granulomas were seen without caseating necrosis.

A diagnosis of idiopathic HCP was made and the patient was put on oral prednisone. His symptoms improved. After 2 months of treatment a CT scan was repeated, which showed a definite improvement.

## Discussion

Patients with idiopathic HCP can present with a variety of symptoms, but chronic headache is the most common complaint. Other signs and symptoms often include cranial nerve palsies (depending on the site of the pathology), ataxia, vision loss, and seizures. Signs of raised intracranial pressure, i.e. papilloedema and broad-based gait are seen when complications occur.

Idiopathic HCP is a diagnosis of exclusion. Thickening of the dura mater has quite an extensive differential diagnosis (Table I).

Meningioma-en-plaque is usually quite localised.<sup>1,4</sup> An angiogram usually shows that blood supply is from the meningeal arteries. The MRI picture can be variable but is usually not as markedly hypointense on T2 as seen with idiopathic pachymeningitis. In our patient dural involvement was quite extensive and showed very low signal on T2 and FLAIR images.

Dural carcinomatosis<sup>1,5-7</sup> is a very rare form of metastatic disease. It can be crescentic in shape and gives the appearance of thickened dura, which

**Table 1. Differential diagnosis for dural thickening**

| Disorder                 | Aetiology   |
|--------------------------|---|
| Infections               | <i>Mycobacterium tuberculosis</i> , syphilis, fungal (Cryptococcus, Histoplasma, Coccidioidomyces), cysticercosis, human T-cell lymphotropic virus I, Lyme disease. |
| Neoplasms                | Benign: meningioma-en-plaque, primary intracranial plasmacytoma, fibroma<br>Malignant: dural carcinomatosis, lymphoma, metastases in adjacent skull                 |
| Haematogenous disorders  | Lymphomatosis   |
| Systemic disorders       | Wegener's granulomatosis, sarcoidosis, Sjögren's syndrome, Behçet's syndrome, rheumatoid arthritis, multifocal fibrosclerosis                                       |
| Intracranial hypotension | Spontaneous, post-spinal fluid drainage   |
| Idiopathic               | Idiopathic hypertrophic cranial pachymeningitis   |
| Congenital               | Mucopolysaccharidoses   |
| Other                    | Chronic subarachnoid haemorrhage, dural arteriovenous malformation, cranial irradiation   |

enhances markedly. T1 and T2-weighted images usually have an intermediate signal in dural carcinomatosis, where idiopathic HCP usually shows a markedly hypointense signal.

Fibromatous disease of the dura<sup>1</sup> should also be considered because of its MRI picture, although it is very rare and is mostly a well circumscribed intracerebral mass which may or may not be related to the meninges. MRI shows centrally decreased and peripheral hyperintense signal on T2-weighted sequence. In idiopathic HCP the dural edge may show a hyperintense signal, due to the inflammatory process, with a central hypointense signal.

Neurosarcoidosis is one of the more frequent diagnoses made when dural thickening is seen.<sup>2,3-5,8,9</sup> Sarcoidosis causes non-necrotising granulomas. Up to 5% of sarcoid patients develop neurosarcoidosis. Basilar leptomeningeal enhancement is the most common CT finding with hydrocephalus. Hypodense areas are some-

times seen in the periventricular white matter. An iso- or hyperdense mass, which enhances markedly post contrast can sometimes be found over the convexity, although then a plasmacytoma should be part of the differential diagnosis. An angiogram usually shows an avascular mass. The MRI picture could be variable with either hyper-, iso- or hypointense signal, but nearly half have periventricular high-signal lesions on T2-weighted sequences. Slightly more than one-third of patients present with multiple parenchymal lesions, about the same number of patients have leptomeningeal enhancement (nodular or diffuse).<sup>7</sup> Ten per cent show a solitary intra-axial mass, and 5% could have a solitary extra-axial mass.<sup>7</sup> In five to ten per cent of cases the hypothalamus or pituitary stalk is affected. Other possible presentations include hydrocephalus, lacunar infarcts, and vasculitis.<sup>7</sup> An elevated ACE level could help in the diagnosis of sarcoidosis. The Kveim skin test is the most sensi-

tive of the uninvase tests, but it might not be available. A biopsy might be the only way to diagnose neurosarcoidosis. A skin or lymph node biopsy might save the patient from an open craniotomy. In our patient's case the biopsy still left us in the dark, with poorly formed granulomas and no other tell-tale signs, thus sarcoidosis could neither be confirmed nor excluded.

Chronic granulomatous infections, i.e. cryptococcus,<sup>3</sup> histoplasma, coccidioidomyces, mycobacterium, syphilis,<sup>3,8</sup> and tuberculosis (TB)<sup>3, 5, 7, 8</sup> could also cause thickening of the dura. TB pachymeningitis is seen mostly at the base of the skull.

Syphilitic pachymeningitis can be seen in primary and tertiary forms.<sup>1,5,7,8</sup> It is often seen in association with subdural haematomas due to repeated head injuries secondary to falls, and is known as pachymeningitis haemorrhagica interna. Granulomas occur in the periosteal layer but can affect the dura. Adhesion of the dura to the leptomeninges is common, giving a thick dense membrane.

Wegener's granulomatosis<sup>3,5,7-9</sup> usually involves nasopharyngeal or sinus inflammation and vasculitis of other organs is almost always present.<sup>5</sup> The most common central nervous system sign is peripheral neuropathy. The patient should be treated aggressively with corticosteroids and cyclophosphamide.<sup>5</sup> Although our patient had an incidental mucocoele in the right maxillary sinus he did not have any signs of vasculitis in other organs.

Multifocal fibrosclerosis<sup>2,3,5,7</sup> patients often have multisystem involvement. Common syndromes here are Riedel thyroiditis, mediastinal fibrosis, retroperitoneal fibrosis, sclerosing cholangitis, episcleritis, testicular

fibrosis, subcutaneous fibrosis, and orbital pseudotumour. This process may extend intracranially, frequently from an orbital pseudotumour.

Radiological findings of HCP are characteristic but not diagnostic. Unenhanced CT usually shows thickened hyperdense dura (the process may be linear, nodular or both), typically seen along the tentorium, falx, ridge of the tentorium, base of skull<sup>1,9</sup> and prepontine cistern. The dura mater enhances markedly post contrast. Gadolinium-enhanced MRI is more sensitive for HCP than contrast-enhanced CT. MRI shows hypointense lesions on T1 and T2-weighted images.<sup>1,4,9</sup> On a T2 sequence the hypointense thickened meninges may be bordered by a thin margin of hyperintensity.<sup>1,9</sup> The hypointense areas correlate with dense fibrosis and the hyperintense margin with inflammatory cell infiltrate.<sup>1,9</sup> T1 gadolinium-enhanced MRI shows abnormal enhancement of the affected dura. White matter hypodensity that could be seen on CT in our case may be secondary to dural sinus infiltration by the inflammatory process with subsequent ischaemia. Follow-up MRI can be utilised to monitor the effect of treatment and progress of the disease.

Special investigations that can be done include: erythrocyte sedimentation rate (ESR) (usually increased in idiopathic HCP), TPHA, venereal disease research laboratory test (VDRL), serum electrophoresis (monoclonal gammopathy seen in idiopathic HCP), calcium, ACE (could be raised in sarcoidosis and thus help to exclude HCP), serology to exclude fungal infections, c- and p-antineutrophil cytoplasmic antibodies (ANCA), rheumatoid factor and anti-nuclear antibodies. CSF tests might reveal an elevated protein and white blood cells,

predominantly lymphocytes. A Kveim skin test can help to exclude sarcoidosis. A biopsy may be the ultimate course, which commonly reveals fibrosis and chronic inflammatory infiltrates, including lymphocytes, plasma cells, histiocytes, epithelioid cells and occasionally granulomas.<sup>10</sup> A chest radiograph can help to diagnose sarcoidosis and TB.

Macroscopically the most common appearance is a diffuse yellowish thickening of the dura mater.<sup>1</sup> Microscopically, fibrosis is seen with an infiltrate of chronic inflammatory cells such as lymphocytes, plasma cells, and eosinophils.<sup>1,2,3,9</sup> There could be some degree of arachnoid and pia mater involvement. The brain is microscopically not involved.

Complications include hydrocephalus (due to obstruction of flow of CSF and possibly decreased absorption into venous sinuses), venous sinus thrombosis, occlusion of intracranial vasculature (due to angitis or compression),<sup>9</sup> and cerebral oedema,<sup>10</sup> as seen in our patient.

Treatment with high-dose corticosteroids, for example 60 - 80 mg prednisone per day, is still the mainstay but adding azathioprine or methotrexate can allow tapering of the steroids.<sup>10</sup> Surgical excision may be required to relieve compression.

## Conclusion

This case of HCP illustrates the dilemma clinicians might experience. As mentioned, the radiological picture is characteristic, but the aetiology might be elusive with negative serology and a biopsy that could fit with any granulomatous disease (except TB), and no features that could suggest a more definite diagnosis. Idiopathic HCP is a diagnosis of exclusion but so is sarcoidosis. Part of the problem is

the lack of non-invasive diagnostic tests for sarcoidosis and some of the other rare granulomatous diseases. The diagnosis of idiopathic hypertrophic cranial pachymeningitis was made because there were no features that supported sarcoidosis and all serology tests were negative.

## Acknowledgements

The authors would like to thank Dr M E Moagi and Professor C H van der Meyden from the Neurology Department of Dr George Mukhari Hospital/MEDUNSA Complex, for their help in acquiring the necessary information.

## References

1. Martin N, Masson C, Henin D, Mompoin D, Marsault C, Nahum H. Hypertrophic cranial pachymeningitis: Assessment with CT and MR imaging. *American Journal of Neuroradiology* 1989; **10**: 477-483.
2. Berger JR, Snodgrass S, Glaser J, Post MJD, Norenberg M, Benedetto P. Multifocal fibrosclerosis with hypertrophic intracranial pachymeningitis. *Neurology* 1989; **39**: 1345-1349.
3. Masson C, Henin D, Hauw JJ, Rey A, Raverdy P, Masson M. Cranial pachymeningitis of unknown origin. *Neurology* 1993; **43**: 1329-1334.
4. Ranoux D, Devaux B, Lamy C, Mear JY, Roux FX, Mas JL. Meningeal sarcoidosis, pseudomeningioma, and pachymeningitis of the convexity. *J Neurol, Neurosurg Psychiatry* 1992; **55**: 300-303.
5. Mamelak AM, Kelly WN, Davies RL, Rosenblum ML. Idiopathic hypertrophic cranial pachymeningitis. *J Neurosurg* 1993; **79**: 270-276.
6. Zajicek JP, Scolding NJ, Foster O, et al. Central nervous system sarcoidosis — diagnosis and management. *QJM* 1999; **92**: 103-117.
7. Osborn AG, Blaser SI, Salzman KL. Pocket radiologist brain top 100 diagnoses. In: Osborn AG, ed. *Meninges*. Salt Lake City, Utah: Amirsys, 2003: 213 - 221.
8. Moore AP, Rolfe EB, Jones EL. Pachymeningitis cranialis hypertrophica. *J Neurol Neurosurg, Psychiatry* 1985; **48**: 942-944.
9. Tanaka M, Suda M, Ishikawa Y, Fujitake J, Fujii H, Tatsuoka Y. Idiopathic hypertrophic cranial pachymeningitis associated with hydrocephalus and myocarditis: Remarkable steroid-induced remission of hypertrophic dura mater. *Neurology* 1996; **46**: 554-556.
10. Kupersmith MJ, Martin V, Heller G, Shah A, Mitnick HJ. Idiopathic hypertrophic pachymeningitis. *Neurology* 2004; **62**: 686-693.