

# Amoebic liver abscess with pleuro-pulmonary complications and enlarged gallbladder

**M H Modishi**

MB ChB, MMed (Diag) Rad

**S Ahmad**

MB BS, FCRad (D) SA

Department of Diagnostic Radiology  
Medical University of Southern Africa

## Introduction

The complications of amoebic liver abscess can be due to intravesical rupture into the gallbladder, rupture into the pericardium which is rare and almost always fatal, or rupture into the peritoneum or duodenum with formation of hepatoduodenal fistula and pleuropulmonary complications, namely pleural effusion, empyema, atelectasis and abscess.

The usual presentation of amoebic liver abscess may be acute in nature with severe right hypochondrial pain and pulmonary symptoms, or it can be silent.

## Case report

A 72-year-old female patient, a known diabetic on treatment, was referred to our hospital with the diagnosis of acute cholecystitis. The patient gave a 3-week history of right upper-quadrant pain and vomiting and there was a past history of peptic

ulcer disease for which she had been treated. On clinical examination the patient was found to have right hypochondrial tenderness with guarding. No rebound tenderness was elicited and the vital signs were within normal limits. The blood results from the peripheral hospital showed leucocytosis with a white cell count of 12.6 (normal value 4 - 10). The patient was booked for emergency ultrasound on clinical suspicion of acute cholecystitis. A routine chest X-ray was done which showed right-sided pleural effusion with relaxation atelectasis (Fig. 1). Ultrasound showed an anechoic, well-defined lesion with internal echoes in the right lobe of the liver, and the gallbladder was dilated with intracavitary thin fibrous strands. The wall thickness was normal and no fluid collection was noted around or in the gallbladder fossa. At this stage the radiological differential diagnosis included liver abscess with possible rupture into the gallbladder. A computed tomography (CT) scan was suggested. Axial 10 x 10 mm cuts were done pre and post contrast, from the dome of the diaphragm to the pelvic brim. One hundred millilitres of intravenous Jopamiron was injected at a rate of 2 - 3 ml/s through a power injector. Oral

Gastrografin was given to opacify the bowel. CT scan confirmed a hypodense lesion measuring 16 cm x 9 cm in the right lobe of the liver with post-contrast rim enhancement (Fig. 2). There were no dilated ducts. The gallbladder was dilated. The portal vein and splenic vein were patent. Inflammatory changes were noted around the hepatic flexure, ascending colon and the caecum (Fig. 3). No ascites or lymphadenopathy were noted. The right-sided pleural effusion with relaxation atelectasis was also confirmed (Fig. 4). The diagnosis of possible amoebic liver abscess complicated by rupture to the gallbladder was made at that stage. Ultrasound-guided abscess drainage was done and approximately 300 ml of pus was drained. The specimen was negative for both Gram-positive and-negative organisms and the culture was sterile. No parasites were seen and the hydatid hooklets were not observed. The drain was left *in situ*. Serial ultrasound later showed the progressive resolution of the abscess. The patient was put on intravenous Flagyl and gentamicin and improved markedly. She was discharged on oral treatment.

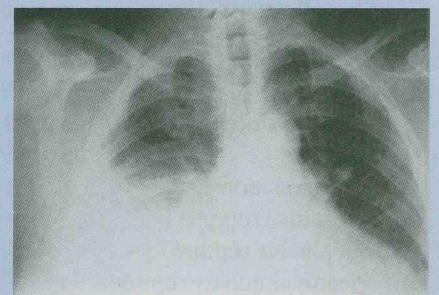


Fig. 1. Right-sided pleural effusion with relaxation atelectasis.

## Discussion

Amoebic liver abscess is common in tropical regions and developing

# CASE REPORT

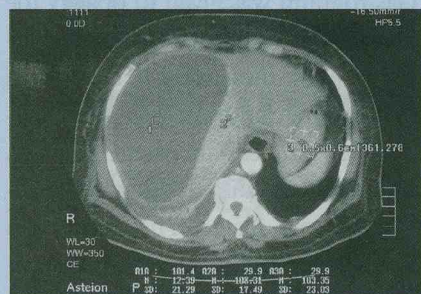


Fig. 2. Hypodense lesion in the right lobe of the liver.

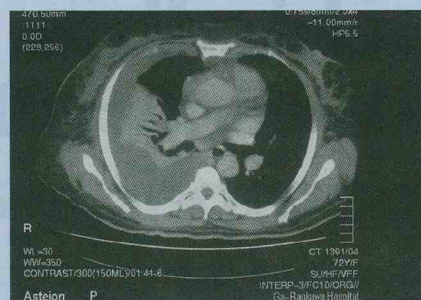


Fig. 4. Right-sided pleural effusion with relaxation atelectasis.

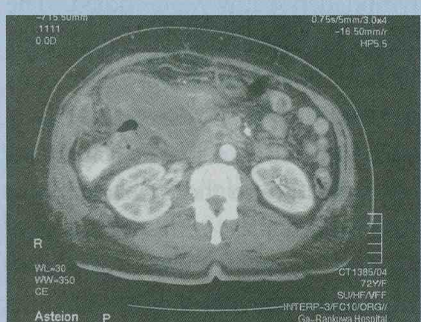


Fig. 3. Inflammatory changes noted around the hepatic flexure, ascending colon and caecum.

countries. It is caused by *Entamoeba histolytica*, which is a protozoan parasite. It lives and develops in the colon. The caecum is the primary site affected<sup>1</sup> and in 15% of cases it

spreads to the liver.<sup>1</sup> The usual presentation is liver abscess.<sup>2</sup> The liver is the commonest extra-intestinal organ to be involved. The right lobe of the liver is commonly affected.<sup>3</sup> Amoebic liver abscess can be complicated by rupture into the pericardium, which is rare.<sup>4</sup> It can also rupture into the pleural cavity.<sup>3</sup>

According to Ramachandran *et al.*<sup>3</sup> the chronological sequence (Table I) of amoebic liver abscess can be uncomplicated with or without hepatomegaly. The hepatomegaly can be generalised or localised. It can also be complicated. Complications can be local like pericardial rupture,<sup>3,4</sup> sub-

prenc rupture and pleuropulmonary rupture.<sup>3</sup> Intraperitoneal and intravesical rupture into the stomach and gallbladder may also occur, as in our patient. Complications of amoebiasis are associated with high morbidity and mortality and early diagnosis is important for both management and follow-up.<sup>2</sup> Leucocytosis occurs in 60% of cases,<sup>3</sup> and alkaline phosphatase is raised in more than 50% of cases.<sup>3</sup> The indirect haemagglutination test /indirect fluorescent test are used for diagnosis together with stool examinations.<sup>1-4</sup> Acid-fast bacilli (AFB) is negative and the culture is sterile.<sup>5</sup> A negative result for the stool test, pleural fluid, sputum, and pus does not exclude amoebiasis.<sup>5</sup> The amoeba usually resides in the periphery of the cyst wall.<sup>6</sup> Although the indirect haemagglutination test is the most sensitive test, a positive test for indirect haemagglutination alone does not mean that the patient has amoebiasis. Care should be taken to exclude neoplasms such as hepatocellular carcinoma.<sup>6</sup>

Table I. Sequence of events in amoebic liver abscess according to Ramachandran *et al.*<sup>3</sup>

Complication	Non-complicated	Complicated local	Complicated distant
Hepatomegaly	+	+	+
Focal	+	+	+
Generalised	+	+	+
Sinuses	+		
Skin ulceration	+		
Pericardial rupture	-	+	
Subphrenic rupture	-	+	
Pleuropulmonary rupture	-	+	
Frank rupture, e.g. local peritonitis, chronic peritonitis, leakage	-	+	
Intravesical rupture, e.g. stomach, gallbladder	-	+	
Brain abscess, lung abscess			+

+ Present, - Absent.

## Conclusion

Sonar and CT scan and the above-mentioned laboratory investigations should be used to supplement each other. In our patient the sterile culture and response to antibiotics favoured the diagnosis of amoebiasis.

## References

1. Eiseinburg R. *Gastrointestinal Radiology. Pattern of Approach*. 3rd ed. Philadelphia: Lippincott-Raven, 1996: 316-317.
2. Siddiqui MN, Rizvi SB, Ahmed M, Rizvi IH. Amoebic liver abscess complicated by hepato-duodenal fistula. *Clinical Radiology* 1992; **46**: 142-143.
3. Ramachandran S, Goonatilake HD, Induruwa PA. Syndromes in amoebic liver abscess. *Br J Surg* 1976; **63**: 220-225.
4. Mondragon-Sanchez R, Cortes-Espinoza T, Sanchez-Cisneros R, Parra-Silva H. Rupture of an amoebic liver abscesses in to the pericardium. *Hepatogastroenterology* 1994; **41**: 585-588.
5. Vicker PJ, Bohra RC, Sharma GC. Hepato-pulmonary amebiasis. *Int Surg* 1982; **62**: 427-429.
6. Lebolt Scot A, Jurado R, Healy GR, Shulman JA. Hepatocellular carcinoma simulating amoebic liver abscess. *Am J Gastroenterol* 1985; **80**: 639-642.

# A case of renal artery stenosis — FMD or atherosclerosis, a diagnostic dilemma

**N Khan**

MB BS, FCRad (D) SA

**J Z Makama**

MB ChB

Department of Diagnostic Radiology  
Medical University of Southern Africa

A 22-year-old female patient was referred from a peripheral hospital with a 1-year history of uncontrolled hypertension. The laboratory findings showed normal urea and creatinine levels.

The left kidney was not visualised on excretory urography. Renal ultrasound showed a small left kidney measuring 69 mm in length with a cortex of 0.7 mm. Captopril scintigraphy showed a small left kidney with

poor perfusion and suboptimal excretion. These findings were suggestive of renovascular hypertension, and a renal angiogram was suggested. The aortogram (Fig. 1) and a selective left renal arteriogram (Fig. 2) showed marked smooth stenosis of the proximal left renal artery, with no beading. No post-stenotic dilatation was noted. Perfusion to the left kidney was reduced. The right renal artery was normal (Fig. 3). There were no signs of involvement of the abdominal aorta and its branches. Balloon angioplasty of the left renal artery was attempted without appreciable success. Due to intractable hypertension the patient underwent a left nephrectomy. No complications were encountered postoperatively, the blood pres-

sure dropped to 100/60 mmHg, and the patient remained normotensive until discharged.

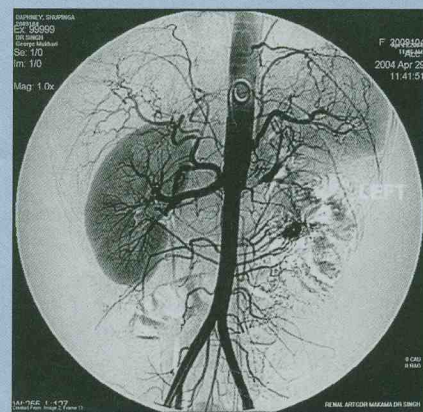


Fig. 1. Abdominal aortogram showing smooth narrowing of the left renal artery.

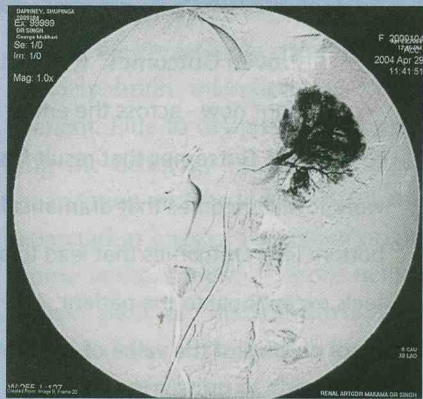


Fig. 2. Selective left renal arteriogram showing renal artery stenosis and a small left kidney.