

Physiotherapy in a Whiplash Injury: A Case Report

ABSTRACT:

Study Design: Case Report

Objectives: To describe physiotherapy intervention in an individual with a suspected whiplash injury.

Background: The patient was a 29-year old male with complaints of neck pain and tightness following a motor vehicle accident.

Methods and Measures: The focus of the case study is physiotherapy assessment and intervention in a stage II whiplash injury.

Results: Following intervention, positive changes occurred in outcome measures such as pain, work status and activities of daily living.

Conclusion: Physiotherapy intervention is successful in addressing whiplash associated disorders.

Van Eck C,
PT, DPT, OCS, COMT, FAAOMPT
B Physiotherapy (Cum Laude)¹

¹ University of Pretoria, South Africa.

KEY WORDS: PHYSIOTHERAPY, WHIPLASH INJURY, MOBILIZATION, THERAPEUTIC EXERCISE, NEURAL TISSUE MOBILIZATION, PATIENT EDUCATION.

INTRODUCTION

The Quebec Task Force on Whiplash Associated Disorders (WAD) defines whiplash as an acceleration-deceleration mechanism of energy transfer to the neck. It may result from a rear-end or side-impact motor vehicle accident (MVA), or other mishaps. After a MVA, 62% of vehicle occupants develop neck pain. The most common symptoms of whiplash injury include neck pain, headache, stiffness, shoulder/arm pain, muscle fatigue, paraesthesia, dysphagia, visual and auditory disturbances, dizziness, poor concentration and sleep disturbances. The Quebec Severity Classification of WAD is based on clinical presentation and graded 0-IV. WAD II classification is defined as a whiplash injury with neck symptoms and musculoskeletal sign(s). Inconsistencies in the literature exist regarding the prognosis of whiplash injury, ranging from favorable to non-favorable. Only 22% of whiplash patients resume usual activities within a month after the incident and up to 60% report pain and disability

at 6 months. Chronic whiplash disorders (symptoms or disabilities persisting for more than six months) have significant long-term economic implications. In patients with normal recovery a gradual improvement in physical and mental function, activities of daily living (ADL) and participation in work are expected. Contributing factors associated with delayed recovery include previous injury, headache, neck pain after the accident, employment status, type of collision, compensation, clinical findings, cultural differences, coping strategies and physical as well as psychosocial well-being.

METHODS

THE SUBJECTIVE EVALUATION

Background: The patient was a 29-year old male complaining of neck pain and tightness as well as low back pain following a MVA. He was referred to physiotherapy two weeks after the accident. The patient described his **main complaint** as an “ache and tightness” in his neck (left worse than right), extending towards his shoulder blades. **Behavior of symptoms** included neck pain of 4-5/10 on a Numeric Pain Rating Scale (NPRS), aggravated by movement, prolonged standing or sitting; fatigue when “holding his head up”, relieved with

rest; sleep interruption of 2-3 times per night and interscapular pain of 4-5/10. The patient considered the **nature of the disorder** as impairing to his work as a police officer. **Present history** included the onset of symptoms shortly after being rear-ended. He described the impact as unexpected and strong, forcing the back of his head into the head support. **Past history** was unremarkable with no previous injuries, neck or back pain. **Special Questions** revealed good general health and no neurological signs. The patient denied sub-occipital pain, headaches, nausea, vomiting, dizziness, diplopia, dysarthria, dysphagia or drop attacks. Cervical spine x-rays taken at the emergency room were unremarkable and he was discharged with a prescription for pain medicine. Since pain was increased to 6/10 by standing or sitting for periods longer than 15-minutes and subsiding to its prior level after only a few minutes of resting, the injury was considered to be none irritable. The total score of the **patient specific functional scale (PSFS)** was 3.3/10.

In the absence of contraindications, a physical examination focusing primarily on the cervical spine was planned. The physiotherapy clinical practice guideline for WAD advises that the physical examination should include general

Correspondence to:

Corné van Eck
Cell: 076 137 0084
Email: fcvanek@vodamail.co.za

observation, regional examination, range of motion, quality of movement, symptom provocation, muscle strength and cervical proprioception.

THE PHYSICAL EXAMINATION

Observation: The patient lacked spontaneous neck movement and appeared to be in discomfort. **Postural assessment** revealed decreased cervical lordosis, upper cervical extension and a kyphotic cervical-thoracic junction. **Neurological testing** was not indicated at this time. **Active physiological movement:** A CROM Instrument (product of Performance Attainment Association, 958 Lydia Drive, Roseville, Minnesota, 5513) was used to measure active cervical range of motion. The patient was instructed to report any symptoms and to stop moving at the first onset of pain (P1) or stiffness (R1). Active movement was restricted in all directions. The patient complained of muscle pulling on both sides of his neck during extension, left side bend (LSB) and left rotation (LR). Differentiation between the upper and lower cervical spine revealed the latter to be more involved. Alar and transverse ligament **stability testing** and provocation testing of the odontoid process were unremarkable. **Palpation** revealed a slight increase in skin temperature as well as tenderness of the musculature in the cervico-thoracic region and over facet capsules of C3/4-C5/6 bilaterally. **Passive physiological inter-vertebral movement (PPIVM)** was performed to further isolate the source of the disorder and to identify possible treatment techniques. The patient was instructed to communicate reproduction of symptoms while the therapist was palpating for a joint sign. Segmental extension at C3/4 - C5/6 (L) was limited and segmental side bend (SB) findings included painful levels at C3/4 - C5/6 bilaterally. Manual examination of inter-segmental mobility is widely used and accurate in identifying symptomatic levels. Relevant findings of **passive inter-vertebral accessory movements (PAIVM)** are described in table 2. **Cervical muscle testing** of the deep neck flexors (DNF) was tested with an inflatable biofeedback cuff, (Chattanooga Group, Chattanooga, TN) holding a 4-mmHg increase in pressure for 1 second x7. The patient expressed fatigue after performing the test. Mild substitution using sternocleidomastoid

muscles was palpated at the clavicle. **Neural tissue mobility** of the median nerve was restricted at -45° (R) elbow extension and -30° (L). Thoracic and lumbar neural tissue mobility was not assessed at this time. At the conclusion of the subjective and objective evaluation, no specific contraindications were identified.

COURSE OF TREATMENT

This case study provides a detailed account of physiotherapy intervention in a patient with WAD II presenting with articular, soft tissue, proprioceptive and postural dysfunction. Primary goals of physiotherapy intervention in WAD II are early mobilization, pain reduction, optimizing quality of life, patient education on behavior modification, quick return to ADL and reducing a patient's dependence on medicine. Positive outcomes were found with multi-model physiotherapy intervention, specifically Maitland/McKenzie mobilizations and exercises in the recovery from whiplash injury, prevention of chronic disorders and controlling social and economic costs. In patients with normal recovery, treatment goals are determined by functional impairments and in patients with delayed recovery, special emphasis is placed on coping strategies.

Table 1 is a detailed description of the plan of care used for the patient with WAD II, as described in this case study.

Special techniques used in proprioceptive and kinesthetic rehabilitation are based on studies described by Soderlund et al.

The patient was treated for six sessions over a 14-day period. **Table 2** is a summary of the outcome measures before and after physiotherapy intervention.

DISCUSSION

Clinical decision-making is guided by the patient's clinical presentation, the stage of the injury, goals and the provider's formal knowledge and experience. Following a rear-impact collision of only 5x gravitational force (gs), a significant increase in the inter-vertebral neutral zone and range of motion occurs, leaving the lower cervical spine, specifically C5/6 most at risk for injury. During an acceleration of 3.5gs and above, facet joint components such as the synovial fold, articular cartilage and capsular ligaments are at risk of injury, due to facet joint compression and excessive capsular ligament strain during impact. Facet joint compression that exceeds physiologic limits could injure articular cartilage when the upper facet collides with the lower facet. When the collision force is enough, irreversible damage to the cartilage matrix and chondrocytes occur. Mechanoreceptors in the facet capsule and synovial fold can be damaged during whiplash causing

Figure 1. The patient's proprioceptive progression from large to small circles.

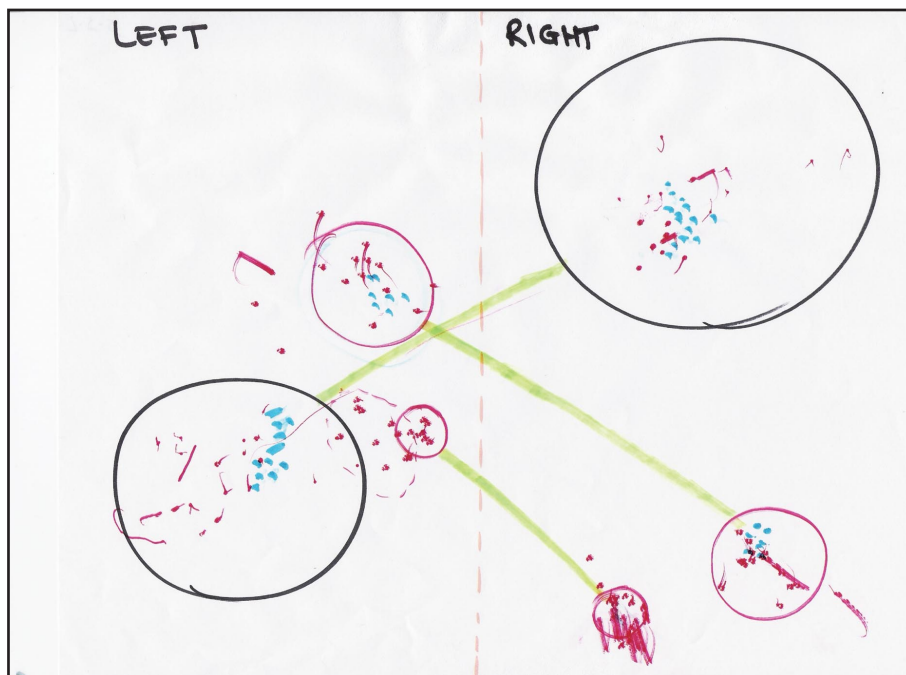

Table 1: Physiotherapy intervention and each sessions' outcome in session one through six.

SESSION 1 (DAY 1)	
TREATMENT	OUTCOME
<p>Soft tissue mobilization Mobilization with movement (MWM), preferred direction</p> <p>Joint mobilization Passive RSB grade III; Transverse (L) C4 grade II</p> <p>Patient Education Encouraged to continue working; Avoid inactivity leading to the development of chronic pain</p>	<p>Decreased pain and muscle guarding</p>
<p>SESSION 2 (DAY 2)</p> <p>Soft tissue mobilization Continued</p> <p>Joint mobilization Continued, added UPA (L) C3/4 grade III; Bilateral UPA C3/4, C4/5 grade III</p> <p>Therapeutic Exercise DNF (20mmHg 5x5sec) Scapular retraction (1x30 with 7kg)</p>	<p>SB (L/R) = 31° SB (L) decreased pain/stiffness Flexion/extension = 45°</p> <p>Improved neck posture</p>
<p>SESSION 3 (DAY 5)</p> <p>Soft tissue mobilization Continued, added muscle stretching to rhomboids, levator scapulae and upper trapezius (L)</p> <p>Joint mobilization Extension with bilateral UPA C4/5</p> <p>Therapeutic Exercise DNF (22mmHg 10x5sec) Scapular retraction (2x30 at 60% of 1RM) Scalene (SB (L), in side laying, 3 x 7 on each side)</p> <p>Patient Education Posture and pathology of whiplash injuries</p> <p>Neural Tissue mobilization Median nerve (L); Cervico-Thoracic neural tissue</p> <p>Home Program Trapezius/ levator scapulae stretching; Self-mobilization median nerve (B) adding wrist/elbow extension</p>	<p>Plastic response and change in collagen extensibility</p> <p>SB (L/R) = 75°. Flexion/extension = 95°</p> <p>Vascularization and opening capillary shunts/collaterals</p> <p>Stiffness and pain (B) UE decreased</p> <p>Plastic response and change in collagen extensibility</p>
<p>SESSION 4 (DAY 6)</p> <p>Soft tissue mobilization MWM (L) scapula; Active/passive pump (L) Trapezius</p> <p>Joint mobilization Transverse (R) C4-C6 grade III; Rotation (L) with UPA (R) C5/6 grade III</p> <p>Therapeutic Exercise DNF (22mmHg 10x10sec) Scalene (SB (B) on incline bench) Scapular retraction (3x30 60% of 1RM)</p> <p>Neural tissue mobilization Lumbar and thoracic in Slump position</p> <p>Home Program Neural tissue stretching using "sliders"</p>	<p>SB (L/R) = 62° Total rotation = 88°</p> <p>-30° knee ext (L); -20° knee ext (R)</p>

Table 1 continued on next page

Table 1: Physiotherapy intervention and each sessions' outcome in session one through six.

<p>Session 5 (Day 13)</p> <p>Joint mobilization UAP (R) C5/6 grade III+ ;Transverse (L) C6 grade III+</p> <p>Therapeutic Exercise DNF (24mmHg 5x10sec) Scalene (Combined SB and Rotation) Scapular retraction at wall pulley (2x11 at 80% 1RM)</p> <p>Neural tissue mobilization Sympathetic Slump in long sitting</p> <p>Kinesthetic awareness Square corner/diagonal squeezes (3x3sec hold each)</p> <p>Proprioception Black/red pen in mouth making dots in circles</p> <p>Home Program Slump "tensioners" Square corner/diagonal squeezes</p>	<p>Combined SB = 64°; Flexion/extension = 106° Total rotation = 106°</p> <p>Decreased stiffness in trunk and lower back</p> <p>Eyes open (black) 30 sec each Eyes closed (red) 30 sec each</p>
<p>Session 6 (Day 14)</p> <p>Joint mobilization UAP (R) C5/6; Combined RSB/ Transverse (L) C6</p> <p>Therapeutic Exercise DNF (24mmHg 10x10sec) Scapular retraction at wall pulley (3x7 at 85% 1RM) (L) Shoulder coordination exercises</p> <p>Neural tissue mobilizations Sympathetic Slump in long sitting with trunk rotation, adding ankle dorsiflexion as tolerated</p> <p>Kinesthetic awareness Square corner/diagonal squeezes (5x5sec hold each)</p> <p>Proprioception Same as fifth session</p>	<p>Combined SB=62° Total rotation=112° Flexion/extension=124°</p> <p>Improved joint motion around a normal physiological axis</p> <p>Decreased stiffness in CT-junction, trunk and lower back</p> <p>Improved neck posture Increased number of red dots in smaller circle</p>

Figure 2: Summary of cervical range of motion changes during physiotherapy sessions.

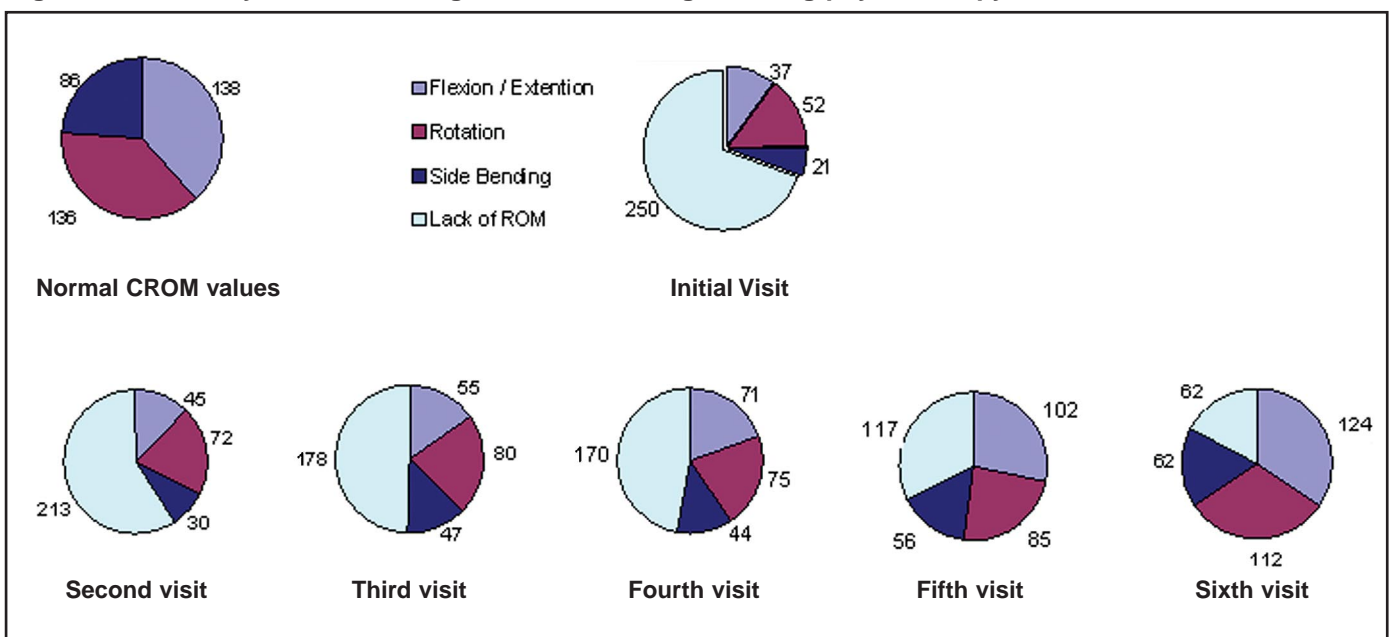


Table 2: A summary of the outcome measures before and after physiotherapy intervention.

Outcome Measures	Before Intervention	After Intervention
Main Complaint	Tight ache in neck, fatigue and soreness in back	Neck slight soreness LBP
Pain (NPRS)	Cervical = 4.5/10; Thoracic = 4.5/10 Lumbar = 4.5/10	Cervical = 1.5/10; Thoracic = 1.5/10 Lumbar = 3.5/10
Area of symptoms	Sides of neck, between shoulder blades, LBP	Slight tightness in neck Soreness in lower back.
PSFS	Turning neck = 7/10 Straightening up = 9/10 Standing > 15mins = 8/10 Total PSFS = 8/10	Turning neck = 3/10 Straightening up = 3/10 Standing > 15mins = 4/10 Total PSFS = 3.3/10
Patient Goals	Relief from back and neck pain	Relief from LBP
Cervical ROM	Deficit total range = 250°	Deficit total range = 62°
DNF	Pressure Increase: 4mmHg 1 second x7 Experienced fatigue	Pressure Increase: 15mmHg 10 seconds x15 Good endurance
PAIVM	CPA C3-C6, T2-T4 grade 1 UPA (R) C4/5, C5/6 grade 1 UPA (L) C3/4, C4/5 grade 1 *Transverse (R) and (L) C4 grade 1	UPA (R) C5/6 grade 2 *Transverse (R) C6 grade 2 *Transverse (L) C6 grade 2
Median nerve mobility	R: -45°elb extension L: -30°elb extension	R: WNL L: WNL

disruption of proprioceptive transmission, leading to dysfunction of the spinal stabilizing system and the potential for spinal instability or uncoordinated, painful muscle contraction, as well as inaccurate perception of head and neck position. Pain is generated from inflammation in the facet articular cartilage, synovial fold, ligaments, capsule and sensitized peripheral and central nociceptive neurons. Sensitization can lead to lowering nociceptive firing-thresholds, resulting in pain during normal motion. Excessive facet joint compression or capsular ligament strain is likely to lead to the chronic symptoms associated with whiplash injury. Decreased neural tissue mobility could indicate intra-neural or intra-dural inflammation, possibly explaining widespread symptoms into the thoracic and lumbar areas.

CONCLUSION

The results of this case report cannot be generalized for the WAD II population. A definite need for continued research in physiotherapy intervention for WAD exists. As far as the author’s knowledge, the intervention and clinical reasoning process was in accordance with current literature on physiotherapy for WAD II. It is also the author’s believe that 4-6 additional treatment sessions, spread out over the next six months would have addressed goals not yet fully accomplished.

REFERENCES

Barnsley L, Lord S, Bogduk N. Whiplash injury. *Pain*. 1994;58:283-307.

Bogduk N. Post whiplash syndrome. *Aust Fam Physician*. 1994;23:2303-7.

Butler DS. *The Sensitive Nervous System*. Unley, Australia: Noigroup Publications; 2001.

Crawford JR, Khan RJK, Varley GW. Early management and outcome following soft tissue injuries of the neck - a randomised controlled trial. *Injury, Int J. Care Injured*. 2004;35: 891-895.

Deans GT, Magalliard JN, Kerr M, Rutherford WH. Neck sprain-a major cause of disability following car accidents. *Injury*. 1987;18:10-2.

Ferrari R, Russell AS. Epidemiology of whiplash: an international dilemma. *Ann. Rheum. Dis*. 1999;58:1-5.

Jull G, Barrett C, Magee R, Ho P. Further clinical clarification of the muscle dysfunction in cervical headache. *Cephalalgia*. 1999;19:179-185.

Jull G, Zito G, Trott P; Potter H, Shirley D. Inter-examiner reliability to detect painful upper cervical joint dysfunction. *Aust J Physiother*. 1997;43:125-129.

Maitland Australian Physiotherapy Seminars. MT-2: Basic Spinal. Cutchogue, NY, 1999.

Maitland GD. *Vertebral Manipulation*. Oxford, England: Butterworth-Heinemann; 1986.

Ola Grimsby Institute. Residency Program in Orthopedic Manual Physical Therapy. Part I: Doctor of Physical Therapy Syllabus and Lecture Notes. San Diego, CA, 2004.

Panjabi MM, Ito S, Ivancic PC, Rubin W. Evaluation of the intervertebral neck injury criterion using simulated rear impacts. *Journal of Biomechanics* 2005;38:1694-1701.

Pearson AM, Ivancic PC, Ito S, Panjabi MM. *Facet Joint Kinematics and Injury Mechanisms*

During Simulated Whiplash. *Spine*. 2004; 29:390-397.

Peeters GGM, Verhagen AP, de Bie RA, Oostendorp RAB. The Efficacy of Conservative Treatment in Patients with Whiplash Injury. A Systematic Review of Clinical Trials. *Spine*. 2001;26:E64-E73.

Schnabel M, Ferrari R, Vassiliou T, Kaluza G. Randomised, controlled outcome study of active mobilization compared with collar therapy for whiplash injury. *Emerg Med J*. 2004; 21:306-310.

Scholten-Peeters GGM, Bekkering GE, Verhagen AP, et al. Clinical Practice Guideline for the Physiotherapy of Patients with Whiplash-Associated Disorders. *Spine*. 2002;27:412-422.

Soderlund A, Olerud C, Lindberg P. Acute whiplash-associated disorders (WAD): the effects of early mobilization and prognostic factors in long-term symptomatology. *Clin Rehabil*. 2000;14:457-467.

Spitzer WO, Skovron ML, Salmi LR, Cassidy JD, Duranceau J, Suissa S, Zeiss E. Scientific monograph of the Quebec Task Force on Whiplash-Associated Disorders: redefining “whiplash” and its management. *Spine*. 1995;20:1S-73S.

Stewart MJ, Maher CG, Refshauge KM, Herbert RD, Bogduk N, Nicholas M. Advice or exercise for chronic whiplash disorders? Design of a randomized controlled trial. *BMC Musculoskelet Disord*. 2003;4:18.

Westaway M, Stratford P, Binkly J. The PSFS: validation of its use in persons with neck dysfunction. *J Ortho Sports Phys Ther*. 1998;27:331-338.

Youdas JW, Garrett TR, Suman VJ, Bogard CL, Hallman HO, Carey JR. Normal range of motion of the cervical spine: an initial goniometric study. *Phys Ther*. 1992;72:770-780.