

Iatrogenic lumbar Pseudomeningocele: a case report and review of literature

S.V. Rege, Harshad Patil

Department of Neurosurgery, Sri Aurobindo Medical College and PG Institute, Indore, Madhya Pradesh, INDIA

Abstract: Lumbar pseudomeningocele is an uncommon complication of lumbar spine surgeries. This occurred due to extradural encapsulated cerebrospinal fluid collection after accidental durotomy or un-repairable dural tear. On review of literature only 58 cases have been reported so far. Magnetic resonance imaging is the investigation of choice for diagnosis of pseudomeningocele. Herein author has described a case of iatrogenic pseudomeningocele after lumbar spine surgery and its management.

Key words: pseudomeningocele, lumbar laminectomy, Complication, accidental durotomy

Introduction

Iatrogenic lumbar pseudomeningocele is an extradural cystic collections of cerebrospinal fluid (CSF) without dural covering which result from a breach in the dura. This is a rare complication mostly occurred due to accidental dural tear during laminectomy in lumbar spine surgery. It also occurred due to lumbar puncture, myelography and intrathecal catheter placement. Iatrogenic pseudomeningocele was first reported by Hyndman and Gerber in 1946[1] and since then only 58 cases have been reported so far. Herein we describe a case of iatrogenic pseudomeningocele which was occurred after lumbar spine surgery.

Case report

A 45 years old male admitted in our

institute with chief complaint of swelling and pain over operative site for last 15 days and right lower limb radiating pain since 10 days. The patient had undergone a L4-L5 laminectomy and discectomy one month back in another institution. After operation patient was asymptomatic for 15 days.

Patient developed backache and swelling over operative site. The intensity of pain and swelling increased progressively. Patient also experienced a severe radiating pain over the right lower limb. On examination there was swelling over operative site which increased on straining and standing (Figure 1).

Magnetic resonance imaging (MRI) lumbo-sacral (LS) spine was done which revealed 4x3 cm CSF intensity cystic collection at L4-5 region. The sac arising from L4-5 dura was hypointense on T1W and hyperintense on T2W images (Figures 2, 3).

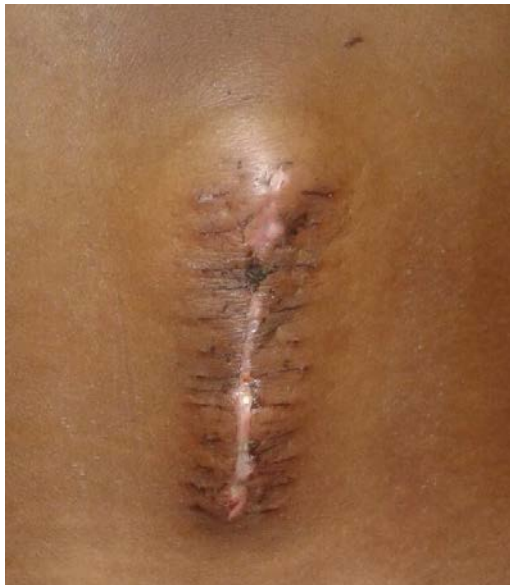

Figure 1 - Fluctuating swelling at operative site

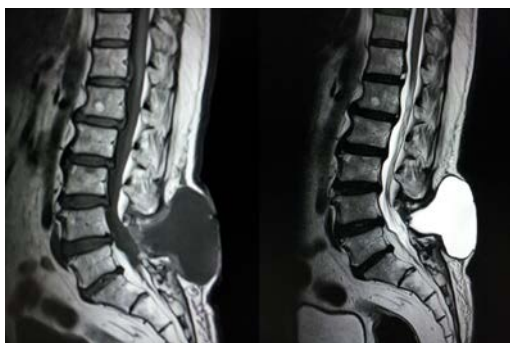

Figure 2 - T1W sagittal image showing a hypointense lesion and T2W sagittal image showing a hyperintense cystic lesion located posteriorly at L4-5 level

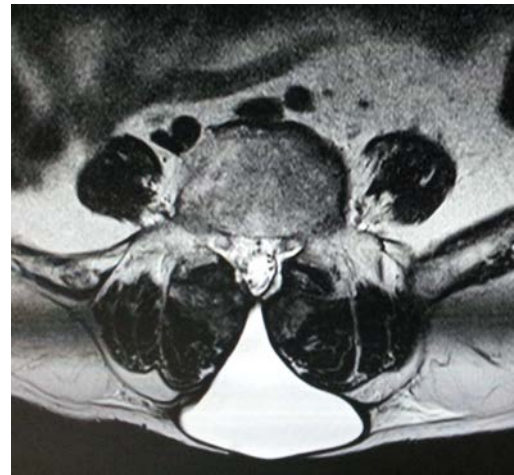

Figure 3 - T2W axial image of the cystic lesion

Based on clinical and radiological findings, diagnosis of pseudomeningocele was made. In view of symptoms patient was taken up for surgery.

Intraoperatively greyish white thick walled sac was found, arising from L4-5 dural defect.

On opening the sac, a root was seen entering the cavity through the dural defect. The root was adherent to the defect, adhenolysis was done and root was reduced into the thecal sac after enlargement of the dural defect. Excess sac was excised and dura was closed in watertight fashion with overlying fat graft (Figure 4).

Post-Operatively the patient's back pain, swelling and radicular symptoms subsided dramatically (Figure 5).

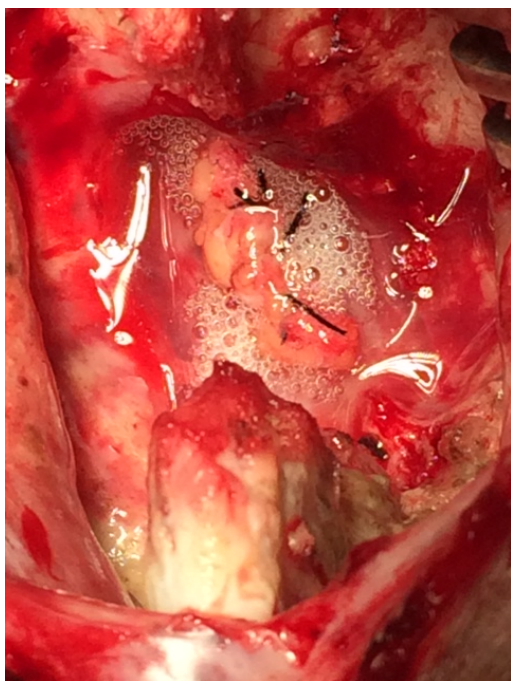


Figure 4 - Intraoperative image: after dural repair and overlying fat graft

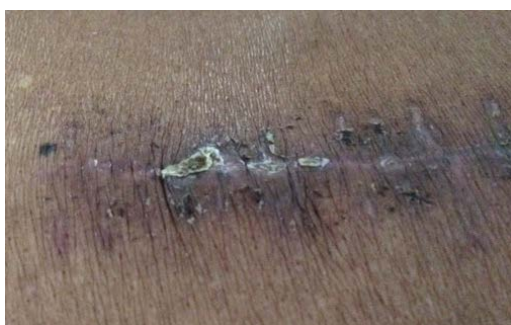

Figure 5 - Postoperative image after removal of sutures

Discussion

Postoperative pseudomeningocele was first reported by Hyndman and Gerber in 1946 [1].

Pseudomeningocele also called as “meningocele spurious”, “pseudocyst” or “false cyst” [2].

Miller et al. in 1968 reported three types of pseudomeningocele - congenital, iatrogenic and traumatic [2]. Most pseudomeningoceles are usually associated with neurofibromatosis and Marfan syndrome, and are congenital in origin. Congenital pseudomeningoceles tend to occur in the thoracic or thoracolumbar area [3].

Traumatic pseudomeningoceles are rare, and more common in the cervical region but it can also occur in the lumbosacral region after a severe distraction injury. The incidence of pseudomeningocele after laminectomy ranges from 0.068% to 2% [4].

Postoperative pseudomeningoceles may result from accidental tear in the dural mater and pia arachnoid which is left open during surgery. If the dural mater and pia arachnoid are torn, CSF extravasates into the paraspinal soft-tissue space. The CSF may be absorbed initially but, after progressive reactions in the connective tissue of the surrounding tissue, CSF is absorbed less readily, resulting in pseudomeningocele formation [2, 4].

Most of the patients are asymptomatic but some patients present with postural headache, localized back pain and radiculopathy. Nerve roots may subsequently herniate through the dural and arachnoid tears. Strangulation of the nerve roots within the cyst may lead to radicular pain and motor deficits. Some pseudomeningoceles may present as fluctuating mass, enlarging with valsalva maneuver [5]. Both these findings were present in our case.

MRI is the investigation of choice in pseudomeningocele. It can accurately assess the size and location of pseudomeningocele.

The cyst content is of low intensity in T1-weighted and with high signal intensity in T2-weighted images. This CSF-containing cyst is located posterior to the dural sac, although it might rarely grow into the intervertebral disc space [6].

The treatment of pseudomeningocele is controversial, particularly in case of asymptomatic patients. Small pseudomeningoceles associated with minimal symptoms can be managed conservatively. Early symptomatic pseudomeningoceles associated with a CSF fistula can be treated with spinal drainage [7].

Symptomatic pseudomeningoceles weeks-to-months after initial surgeries may be treated with surgical dural repair. Large dural defects may be closed with patch techniques using autologous tissue, dural allografts, or fibrin glue along the suture line. Release of cord or root is necessary if adherent to the dura [7].

Lumbar shunt or percutaneous subarachnoid drainage can be used in case of dural cutaneous fistulas and early pseudomeningoceles. This procedure can help to create a seal at the leakage site and promote healing by CSF diversion [8].

Conclusion

A pseudomeningocele should be considered as a diagnosis in patients with recurrent back pain, radicular pain, or a persistent headache with background of spinal surgery.

Wide opening of the cyst, identification of the dural breach and its repair are the key steps of pseudomeningocele surgery. Accidental

dural tear with CSF leakage during lumbar laminectomy and discectomy should be handled properly to prevent development of iatrogenic pseudomeningocele.

Correspondence

Dr. Harshad Patil

E-mail: dr.harshadpatil@gmail.com

Contact No.: +919893894242

Address: Department of Neurosurgery,

Sri Aurobindo medical College and PG Institute, Indore, Madhya Pradesh, India

References

1. HYNDMAN OR, GERBER WF. Spinal extradural cysts, congenital and acquired; report of cases. *J Neurosurg.* 1946 Nov; 3(6):474-86.
2. Miller PR, Elder FW Jr. Meningeal pseudocysts (meningocele spurium) following laminectomy. Report of ten cases. *J Bone Joint Surg Am.* 1968 Mar; 50(2):268-76.
3. Sutterlin CE, Grogan DP, Ogden JA. Diagnosis of developmental pathology of the neuraxis by magnetic resonance imaging. *J Pediatr Orthop.* 1987 May-Jun; 7(3):291-7.
4. Teplick JG, Peyster RG, Teplick SK, Goodman LR, Haskin ME. CT Identification of postlaminectomy pseudomeningocele. *AJR Am J Roentgenol.* 1983 Jun; 140(6):1203-6.
5. Hadani M, Findler G, Knoler N, Tadmor R, Sahar A, Shacked I. Entrapped lumbar nerve root in pseudomeningocele after laminectomy: report of three cases. *Neurosurgery.* 1986 Sep; 19(3):405-7.
6. Murayama S, Numaguchi Y, Whitecloud TS, Brent CR. Magnetic resonance imaging of post-surgical pseudomeningocele. *Comput Med Imaging Graph.* 1989 Jul-Aug; 13(4):335-9.
7. McCormack BM, Zide BM, Kalfas IH: Cerebrospinal fluid fistula and pseudomeningocele after spine surgery. *Spine Surgery, techniques, complication avoidance and management* Edward C, Benzel EC 2005, 2:2033-2042
8. Aoki N. Lumboperitoneal shunt for the treatment of postoperative persistent collection of subcutaneous cerebrospinal fluid (pseudomeningocele). *Acta Neurochir (Wien).* 1989; 98(1-2):32-4.