

## **Apply of WhatsApp: A quick, simple, smarty and cost competent method of communication in neurosurgery**

**Vivek Kumar Kankane, Gaurav Jaiswal, Tarun Kumar Gupta**

Department of Neurosurgery, R.N.T. Medical College & M.B. Hospital, Udaipur, Rajasthan, India

**Abstract:** *Objective:* Neurosurgeons habitually have to hinge on judgments of subordinate staffs to build an assessment on patients whom they cannot be present at immediately. WhatsApp is a no charge to use application for image transfer on Internet. We evaluated the use of WhatsApp in neurosurgical milieu, to show it is economical, quick, available, reliable and practicable. *Materials and methods:* We coordinate a prospective observational study from December 2014 to June 2015. Residents were skilled to take sharp pictures and upload them immediately using WhatsApp on Internet. Primary conclusion was difference between opinion of residents and consultants on WhatsApp images and time delay in decision-making. Conflict was evaluated significant if it changed management decision. *Results:* In the study period, 1356 (mean age: 35.53 years, 71.28% males) patients were included in study those admitted in after hospital hours. Internet packs of smart phone available in market in very economical cost. Judgment could be made on images received on WhatsApp at an average of 4.06 min. There was Conflict in 7.22% cases between residents' reports and images on WhatsApp. All Radiological imaging modalities, were associated with statistically Insignificant difference ( $P > 0.05$ ). *Conclusion:* This study suggests that apply of WhatsApp in neurosurgery can be a simple quick reliable and almost free mode of communicating images enabling a quick decision. Though this cost-effective method should be used with concern particularly with Radiological imaging modalities, which require dispensation and appraisal on console.

**Key words:** Multimedia messaging service, Communication, neurosurgery, WhatsApp, Smart phone

### **Introduction**

Radiological imaging (RI) Conflict has been often reported when junior doctors or residents report on imaging done during off hours. [1-5] This RI Conflict has been found

to have significant clinical impact. [1-5] To be capable to make an assessment on a neurosurgical patient as soon as his primary management is complete, will not only accelerate the definitive care but also improve

the final outcome. Such an approach will have an impact on the residency training program. Smart phones are broadly available. WhatsApp is a free of charge to use application, which can be used over an extensive number of mobile and enable one to talk as well as send pictures over Wi-Fi or 3G or 2G network. 3G or 2G Internet packs available in market in very economical rate. This study was coordinate to look at the option of using this free app in communicating information related to neurosurgical emergencies. The objective of this study was to observe if use of WhatsApp is economical, quick, easy to get to, reliable and realistic in neurosurgery mainly in reporting emergency cases in off hours of hospital.

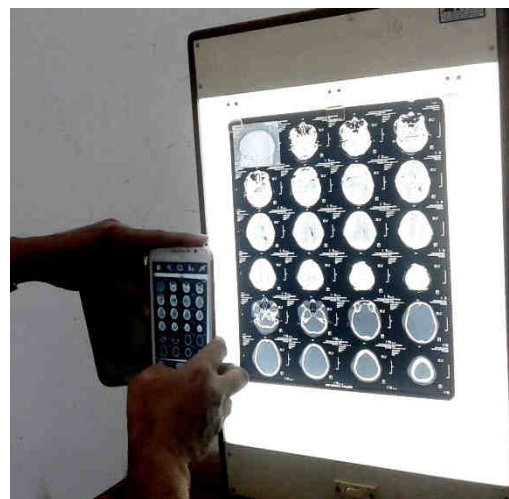
### Materials and Methods

A Prospective observational study was coordinate in the Department of Neurosurgery, R.N.T. Medical College & M.B. Hospital, Udaipur, and Rajasthan, India from December 2014 to June 2015. All patients observing emergency department in off hours of hospital and assessment by neurosurgical residents were included in the study. Personal smart phones with facility of camera (resolution at least 5 Megapixel) and WhatsApp installed were used in the study. Residents were trained to take clear pictures and upload them immediately using WhatsApp over Internet [Figure 1]. Images were taken in close and distant mode. There was no restriction on number of images however uploading big number of images took more time. Radiological Images transferred include those of X-rays, Computed tomography (CT) scans, magnetic resonance

imaging (MRI) scans; CT angiography scans [Figure 2]. These images were studied by consultant neurosurgeon and afterward compared with the reporting done by resident. RI reported by residents was considered as Group 1, by the consultant neurosurgeon on WhatsApp as Group 2, by residents' radiologist as Group 3, by the consultant neurosurgeon on actual images as Group 4 and by consultant radiologist as Group 5.

### Outcome variables

Primary endpoints were Conflict of opinion between Group 1 and 2, and compared to Group 2& 4 and Group 3 & 5 and time delay in decision-making on WhatsApp. Conflict was considered significant if it changed management decision. Afterward analysis involved which RI modality was difficult to study on WhatsApp using Chi-square test. Statistical software for Social sciences (SPSS) version 17 was used for analysis of data.



**Figure 1** - Resident capturing snapshot on Smart headset

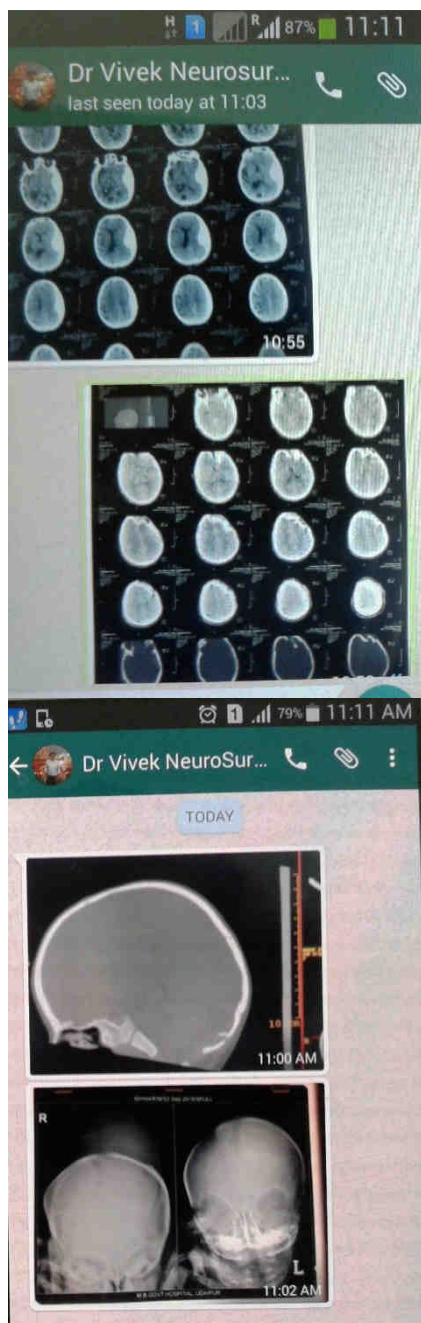


Figure 2 - dissimilar category of smart phones used in the study with WhatsApp on display

### Ethical issues

As this study instructed collecting data and did not entail direct intervention on patients, there were no ethical issues involved. Patients enrolled were not provided with economic incentives, as this study did not require any extra investigation.

### Results

A total of 1356 (mean age: 35.53 years, range 3 month days to 91 years, 71.28% males) patients were included in the study. All patients with accidents, 997 (73.52%) patients had road traffic accidents, 171 (12.61%) had fall and 188 (13.86%) had physical assault. 610 (44.98%) patients presented with headache, 132 (9.73%) with weakness, 680 (50.14%) with altered sensorium and 162 (11.94%) with seizure. Of the 1356 different types of RI transferred on WhatsApp included: 828 (61.06%) cranial CT scans, 155 (11.43%) X-rays, 13 (0.95%) CT angiography images, 360 (26.54%) MRI images and respectively. Decision could be made on images sent on WhatsApp after a mean delay of  $4.06 \pm 1.482$  min (range 3-12 min) from availability of images for upload. This delay involved taking pictures, uploading and communicating to consultant. Using WhatsApp, conflict between RI reporting by residents (Group 1) and consultant neurosurgeon (Group 2) was 7.22% (98 cases). In 58 cases (4.27%), residents could not comment due to confusion in diagnosis, in 14 cases (1.03%) they could not identify surgical indications, in 17 cases (1.25%) they missed critical findings and in the last 9 cases (0.66%) they missed surgical requirement as well as critical findings. Resident usually missed location as well as differentials in

hypodense lesions on CT scans. They frequently missed critical findings that had bearing on deciding time of surgery as well as approach. This Conflict was clinically significant in 80 cases out of 98 cases (81.63%) where management of patients changed. This change in management plan from medical to surgical intervention or adding osmotic diuretics Of all imaging modalities, Conflict between Group 1 and Group 2 was highest for CT angiography head (30.76%) followed by X-ray of cervical spine (21.93%) followed by MRI (8.33%) and CT head (3.623%). There was 100% Accord between Group 3 and 4 however there was 5.16% conflict between images seen on WhatsApp (Group 2) and actual image interpretation (Group 4) and there was 7.81% conflict between image seen on consultant radiologist (Group 3) and image seen by resident radiologist (Group 5). It was found

that of all the RI modalities, had statistically Insignificant difference between group 1 and group 2 Compare to group 2 and group 4 (P value > 0.05) and also all RI modalities, had statistically Insignificant difference between group 1 and group 2 Compare to group 3 and group 5 (P value > 0.05) [Table -1]. Of 1356 patients, 351 patients (25.88%) underwent surgery and rest 74.12% were managed conservatively. As this app is freely available on Internet and can be used on any mobile or pc platform, using this app and service was free of cost. Moreover due to very cost effective 3G or 2G internet packs available in market. Effect of time of day when images were sent for consultation was studied to know whether exhaustion induced during duty hours and consequent slowness during off hours has effect on delay in reporting or increase in difference between RI reporting.

TABLE I

**Comparison of conflict between group 1, 2 and group 2 & 4 and comparison of conflict between group 1 & 2 and group 2 & 4 according to different images sent on WhatsApp**

Comparison of Groups	X ray ( Skull & Cervical Spine)		NCCT Head		CT Angiogram		MRI (Brain & Spine)	
	Yes	No	Yes	No	Yes	No	Yes	No
<b>Conflict between group 1 &amp; 2</b>	34	121	30	798	4	9	30	330
<b>Conflict between group 2 &amp; 4</b>	25	130	20	808	3	10	22	338
<b>P Value</b>	0.193		0.07		0.658		0.249	
<b>Conflict between group 1 &amp; 2</b>	34	121	30	798	4	9	30	330
<b>Conflict between group 3 &amp; 5</b>	25	132	40	788	2	11	39	321
<b>P Value</b>	0.107		0.222		0.352		0.225	

**TABLE II**  
**Drawback and dealings to settle**

<b>Drawback</b>	<b>dealings to settle</b>
<b>deprived resolution</b>	When taking images with a smart phone camera, try to go as close as possible to the subject rather than zooming in when you take a shot. You will get better-resolution photos cropped, than zoomed in.
<b>Images of flash/ neighboring luminosity</b>	Camera flash you have on your phone is almost always too harsh and rarely helpful. Instead try increasing your camera's exposure and ISO levels. Alternatively you could use an external flash like iBlazer or Light strap so close flash light keep away from any direct luminosity over image while taking snap
<b>Missing fractures</b>	learn on bone windows of real images
<b>Under reporting angiography</b>	learn on console/3D
<b>Difficulty in Beginners to taking snaps</b>	Residents were skilled to take clear pictures & gave basic knowledge about focus, exposure, white balance and ISO.

## Discussion

Neurosurgical care is limited in many parts of the world to one or two hospitals serving a large geographic area. The quality of neurosurgical response to emergencies depends on the reliability and completeness of the information received from referral hospitals. First time Servadei F et.al conducted a study from January 1998 to December 2000, the aim of this study is to show how application of guidelines for head injury management in an entire area can be usefully combined with transmission of images from the peripheral to the central hospital. In conclusion of this study is unnecessary transfers can be avoided and the neurosurgeons can evaluate the images of a number of patients who have always been treated outside our Units. This results in more work for the neurosurgeons on duty, but also in a better quality service for the whole area [9].

During the last decade, there is an

increasing demand to discuss diagnostic images and reports of difficult cases with experienced staff. A possible solution besides physically transporting patients and material is to use high-speed communication networks to transfer images and reports electronically. With the web application PACS flow we have developed a solution to transfer images, reports, and messages as a single package in a one-step procedure. The PACS flow is an interoperable and standard compliant web-based application, which gives clinicians a user-friendly interface for their work on a daily basis, so clinicians have tried sending images using KIS, RIS and PACS after office hours in specialties such as radiology [6, 3], Medicine and cardiology[2,11,12,]. Patients archiving and communication system (PACS) which is time consuming and requires expensive hardware's or definite system. The advance of communicating images using WhatsApp only requires taking appropriate pictures and

uploading on Internet. This process is speedy as it takes only fractions of minutes to upload as well download on the recipient workstations. In this study it took a mean of 4.06 min. to decide on images. This was much faster than reported delay in actual image interpretation by radiologist in literature (8.6 h). [5]. Using other modes of communications like sending images by using Multimedia Messaging Service (MMS) is used by neurosurgical residents to transmit scan images to the attending neurosurgeon in conjunction with telephone consultation. This service has been well received by the attending neurosurgeons, who felt that after viewing scan images on their phones, they felt increased confidence in clinical decision making and that it reduced the need for recall to the hospital.

Bullard TB et al. Investigated whether head CT images captured using a mobile phone would be of sufficient quality for neurosurgeons at a level 1 trauma center to make decisions about whether to transfer patients from referring hospitals. Mobile-phone images of CT scans appear to provide adequate images for triaging patients and helping with transfer decisions of neurosurgical cases [4]. Pick j.et al introduce Image transfer by mobile phones into clinical practice to improve communication between neurosurgeons. Most images were transferred from the resident on call to the senior neurosurgeon backing him up. Overall, the system was extremely reliable, quick, and enabled immediate decisions in all emergency situations [8].

Thapa A et al [10] used Viber in neurosurgical scenario, to show it is cheap, fast, accessible, reliable and feasible. This study suggests that the use of Viber App in neurosurgery can be an easy fast reliable and almost free mode of communicating images enabling a quick decision. Our study is similar to this study, except number of patient and number of groups is more in our study and we used Different apps of smart phone. Conflict between resident and consultant (consultant neurosurgeon) was comparable to other studies, published particularly by emergency physicians [5, 1] and radiologist.[7,13] In our study, we found that in 81.63% cases where there was between resident report and image interpretation on WhatsApp, treatment was significantly altered. Medical imaging sent over mobile phones has been found to be constantly interpretable as in our study. In only 4.08% cases images reported on WhatsApp required further modification on actual image interpretation, which was found to be in cases of CT angiography and MRI spine. Our study shows that WhatsApp not only helped in early and proper decision making but also take required interventions. It was found that those Medical Imaging modalities, which required maneuvering on console especially CT angiography head, required careful analysis on WhatsApp and we recommend that it should not exclusively be reported on WhatsApp. Hence this study shows that use of WhatsApp in communicating neurosurgical emergencies is economical, speedy, handy, reliable and realistic; however there is drawback as noted in Table 2.

## Conclusion

This study, a first of its way recommends use of WhatsApp in neurosurgery; an easy fast reliable and almost free mode of communicating radiological images enabling a quick decision. However this cost effective method should be used with concern particularly with radiological imaging modalities, which necessitate dealing out, and evaluation on console. The mobile phone system is adequately useful for early diagnosis and start of treatment in emergent cases. This is attributable to its low cost and eases of handling for sending images to remote areas and between hospitals, despite the small dimensions of the monitor.

## Correspondence

*Vivek Kumar Kankane*

*M.Ch.Neurosurgery Resident, R.N.T. Medical College & M.B. Hospital, Udaipur, Rajasthan, India.*

*Email address: vivekkankane9@gmail.com*

*Address: C/O Dr. Khamesara 59 Sardarpura, Udaipur, Rajasthan, India, Pincode 313001*

*Mobile no. 8955337812*

## References

1. Alfaro D, Levitt MA, English DK, Williams V, Eisenberg R. Accuracy of interpretation of cranial computed tomography scans in an emergency medicine residency program. *Ann Emerg Med* 1995; 25:169-174
2. Balasingham I, Ihlen H, Leister W, Røe P, Samset E. Communication of medical Images, text, and messages in inter-enterprise systems: a case study in Norway *IEEE Trans Inf Technol Biomed.* 2007 Jan; 11(1):7-13
3. Boochever SS. HIS/RIS/PACS integration: getting to the gold standard. *Radiol Manage.* 2004 May-Jun; 26(3):16-24
4. Bullard TB, Rosenberg MS, Ladde J, Razack N, Villalobos HJ, Papa L. Digital images taken with a mobile phone can assist in the triage of neurosurgical patients to a level 1 trauma centre. *J Telemed Telecare.* 2013 Feb; 19(2):80-83
5. Friedman SM, Merman E, Chopra A. Clinical impact of diagnostic imaging discrepancy by radiology trainees in an urban teaching hospital emergency department. *Int J Emerg Med* 2013; 6:24-28
6. Klose KJ, Schäfer C, Kail S, Röthke M, Zhang L. [KIS-RIS-PACS integration: the Marburg approach]. *Radiologe.* 2005 Aug; 45(8):671-681
7. Le AH, Licurse A, Catanzano TM. Interpretation of head CT scans in the emergency department by fellows versus general staff non-neuroradiologists: A closer look at the effectiveness of a quality control program. *Emerg Radiol* 2007; 14:311-316
8. Piek J, Hebecker R, Schütze M, Sola S, Mann S, Buchholz K. Image transfer by mobile phones in neurosurgery. *Zentralbl Neurochir.* 2006 Nov;67(4):193-196
9. Servadei F, Antonelli V, Mastrilli A, Cultrera F, Giuffrida M, Staffa G. Integration of image transmission into a protocol for head injury management: a preliminary report. *Br J Neurosurg.* 2002 Feb; 16(1):36-42
10. Thapa A, Shrestha D, Shrestha D, Giri S. Use of viber app: a fast, easy and cost effective method of communication in neurosurgery. *Neurol India.* 2013 Nov-Dec; 61(6):610-613
11. Vogl R. [Teleradiology and PACS--strategy of the Innsbruck University Hospital]. *Radiologe.* 2005 Aug; 45(8):704-711
12. Wirth S, Treitl M, Villain S, Lucke A, Nissen-Meyer S, Mittermaier I, Pfeifer KJ, Reiser M. [PACS: storage and retrieval of digital radiological image data]. *Radiologe.* 2005 Aug; 45(8):690-697
13. Wysoki MG, Nassar CJ, Koenigsberg RA, Novelline RA, Faro SH, Faerber EN. Head trauma: CT scan interpretation by radiology residents versus staff radiologists. *Radiology* 1998; 208:125-8.