

Odontoid fracture that is not listed in the existing classifications

A new subtype of odontoid fracture: case report

D. Adam^{1,2}, R. Cergan^{1,2}, D. Iftimie², Cristiana Moisescu²

¹“Carol Davila” University of Medicine and Pharmacy, Bucharest

²“Saint Pantelimon” Clinical Emergency Hospital, Bucharest

Abstract: *Background:* There is a significant variety of odontoid fracture classifications along with corresponding treatment strategies. There are though cases which cannot be framed within the existing classifications. *Clinical presentation:* We report the case of a 91 years old female patient who suffered a cervical trauma secondary to a ground level fall. The cervical CT scan revealed a particular type of odontoid fracture, unframeable within existing classifications. The fracture line was at the base of the odontoid process and continued in an oblique trajectory through the right pedicle of the axis. As treatment strategy, we opted for external immobilization in a Minerva jacket and, after 3 months, the patient is symptom free, with partial bone fusion. *Conclusion:* We named this rare case of odontoid fracture type II B for which external immobilization seems sufficient.

Key words: odontoid fracture, classification types, external immobilization.

Introduction

Odontoid fractures have always aroused the interest of many researchers, given their high incidence, multiple classifications and treatment modalities. (1-9)

Odontoid fractures represent 10 – 15% of cervical fractures. Among people over 65 years old, they are the most common type of fracture, their incidence increasing with age (9).

The first classification of these types of fractures was proposed by Anderson and

D’Alonzo in 1974. According to these authors, there are three types of odontoid fractures: type I, an oblique fracture through the upper part of the odontoid process itself, type II, a fracture at the junction of the odontoid process with the vertebral body of the second cervical vertebra, type III, a fracture through the body of the atlas (1).

In 1988, Hadley describes a new subtype of odontoid fracture characterized by comminution at the base of the odontoid process, which he names type II A. It

represents 5 % of type II odontoid fractures, is highly unstable and usually associated with ligamentous injuries (4).

In 2005, Grauer & col. propose a new classification of odontoid fractures, bringing modifications to II and III fracture types proposed by Anderson and D'Alonzo. In type II fractures, with three subtypes, the trajectory of the fracture, although including the vertebral body of C2, it does not extend to the superior articular facets. In type III fractures, the trajectory includes the superior articular facets of C2 (2).

In 2006, Jea & col. describe type III A odontoid fractures characterized by a horizontal fracture line through the body of C2 extended through C1-C2 facet joints (6).

The treatment of patients with odontoid fractures is controversial. The multiple therapeutic strategies, conservatory versus surgical by anterior or posterior approach, must be adapted to the type of fracture.

We present the case of a patient with odontoid fracture that cannot be framed using the aforementioned classifications.

Case report

A 91 years old female patient suffered a cervical trauma secondary to a ground level fall.

At admission, the patient presented with intense upper cervical pain and restriction of neck movements.

The cervical radiograph was negative for cervical fractures.

The cervical CT scan showed a fracture at the level of C2, which includes the body/ dens junction as well as the right side of the

vertebral body of the axis, at the level of the right lateral pedicle. There is also a 4 mm anterior and caudal displacement of the cranial bone fragment (Figure 1, Figure 2).

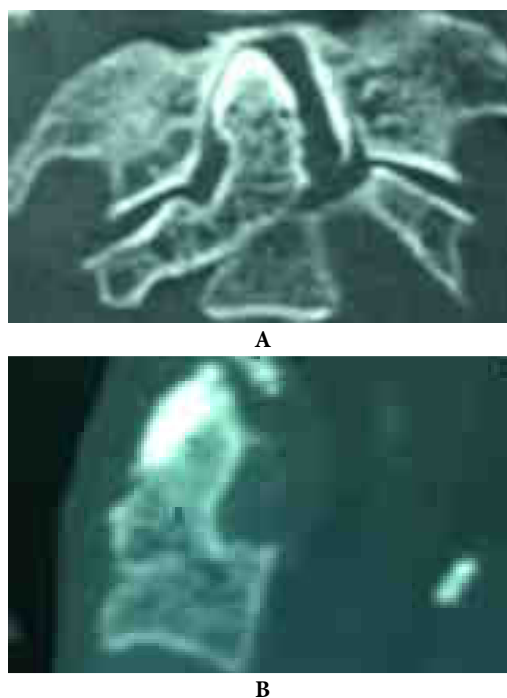


Figure 1 - Cervical CT scan at admission in (A) coronal and (B) sagittal plane showing fracture at the level of C2, which includes the body/ dens junction as well as the right side of the vertebral body of the axis, at the level of the right lateral mass

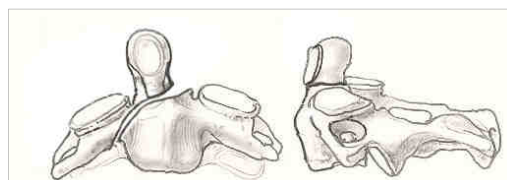


Figure 2 - Schematic representation in coronal and sagittal plane highlighting the fracture trajectory

Considering the age and the associated comorbidities (osteoporosis, high blood

pressure) as well as the patient and family members' preference, external immobilization of the fracture in a Minerva jacket was decided.

After 3 months of immobilization, a control CT scan showed minimal bone union, reason for which maintaining the external immobilization was decided (Figure 3).

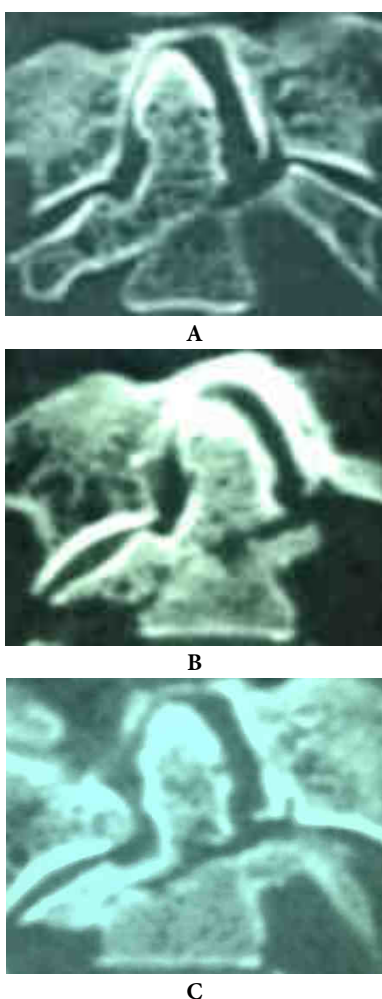


Figure 3 - Comparative coronal cervical CT scans at admission (A), after 2 (B) and 3 months of external immobilization (C) respectively showing an initially minimal, but progressive bone fusion

The patient continued to be without neurological deficits.

Discussion

There are different lines of fracture through the odontoid process which, in the last decades, many researchers tried to classify in order to recommend the optimal treatment in each case (Table I).

The fractures near the tip of the odontoid process, above the transverse ligament, are type I fractures (Figure 4) in all classifications and the recommended treatment is external immobilization using a hard cervical collar, as they are generally stable. There is a very low incidence of non-union and surgery is seldom indicated in these cases, mainly if the displacement is greater than 6 mm and the patient is over 60 years of age (1).

The fracture lines at the base of the odontoid process, between the level of the transverse ligament and the body of the axis, are known as type II fractures (Figure 5) in Anderson and D'Alonzo classification. They are highly unstable and, regarding their management, long-enduring controversies exist (1).

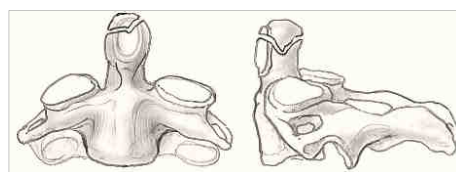


Figure 4 - Type I odontoid fractures

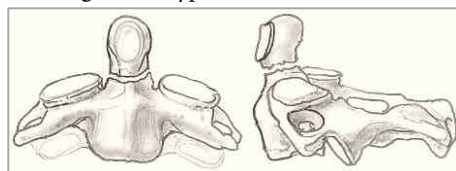


Figure 5 - Type II odontoid fractures

TABLE I
Classifications of odontoid fractures

Author	Year	Type of fracture	Treatment
Anderson – D’Alonzo (1)	1974	I: the tip of the dens; II: fracture of the odontoid base; III: broad-base fracture involving the C2 body;	cervical collar; halo immobilization/ odontoid screw fixation/ atlanto-axial arthrodesis if displacement > 6 mm or patient > 60 years old external immobilization;
Roy – Camille (8)	1981	I: oblique fracture with anterior displacement; II: oblique fracture with posterior displacement; III: horizontal fracture with anterior or posterior displacement;	wiring and polyethylene spacer anterior screw fixation posterior fusion and C2-C1 screw fixation
Levine – Edwards (7)	1985	I: fracture with less than 3.0 mm antero-posterior displacement, without angular deviation; II: fracture with more than 3.0 mm antero-posterior displacement, with significant angular deviation; transverse ligament dislocation; IIA: oblique or horizontal fracture with significant angular deviation, without anterior or posterior displacement; III: a variety of type I fracture with bilateral dislocation;	external immobilization anterior screw fixation

Author	Year	Type of fracture	Treatment
Hadley (3,4)	1988	<p>I: through tip, above the transverse ligament – rare;</p> <p>II: through base of neck - the most common dens fracture;</p> <p>IIA: similar to type II but with large bone chips at fracture site – represents ~ 5% of type II fractures;</p> <p>III: through body of C2 (usually involves narrow space);</p>	<p>cervical collar, halo-vest;</p> <p>anterior or posterior fixation/ halo-vest for 12 weeks;</p> <p>early posterior fixation and C1-C2 fusion;</p> <p>cervical collar, halo-vest;</p>
Grauer (2)	2005	<p>-he redefined types II and III of Anderson – D'Alonzo classification:</p> <p>II: the fracture line involves the body of C2 but it does not affect de superior articular facets:</p> <p>IIA: transverse fracture without comminution and less than 1.0 mm displacement;</p> <p>IIB: fracture that passes from antero-superior to postero-inferior or a transverse fracture with displacement greater than 1.0 mm;</p> <p>IIC: fracture that passes from antero-inferior to postero-superior or a fracture with significant comminution of the dens</p> <p>III: the line of fracture involves the superior C2 articular facets;</p>	<p>external immobilization</p> <p>anterior screw fixation</p> <p>posterior atlantoaxial fixation</p>
Jea (6)	2006	<p>IIIA: horizontal fracture through the body of C2 extending into the C1-C2 facet joints;</p>	
Adam - Cergan	2016	<p>fracture at the base of the odontoid process, with oblique inferior right trajectory, passing through the C2 pedicle extending to the right transverse process, determining in coronal plane a 10° angulation and ventral displacement of the bone fragment to the odontoid of ~ 5 mm in sagittal plane;</p>	<p>external immobilization (???)</p>

The fractures at the base of the odontoid process which extend into the vertebral body are known as type III fractures (Figure 6). They are relatively stable unless significantly displaced and usually external immobilization is a successful treatment option (1).

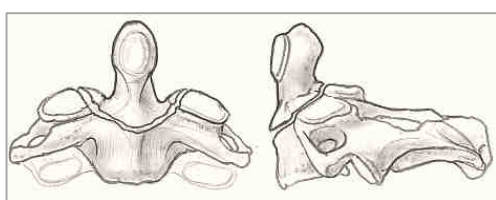


Figure 6 - Type III odontoid

Although this is the most widely accepted classification, two limitations of this classification have been highlighted. First is the difficulty in precise differentiation between a low type II and a high type III fractures; the second is the lack of distinction between fractures in terms of fracture line obliquity, displacement and comminution which has an impact on subsequent management (5).

To address the first limitation, in 1988, Hadley introduced a type IIA fracture subclass to the classification, defined as a type II fracture complicated by an additional chip-fracture fragment at the anterior or posterior aspect of the base of the odontoid (Figure 7). It is highly unstable and represents 5% of type II odontoid fractures (3).

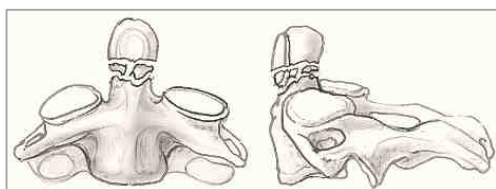
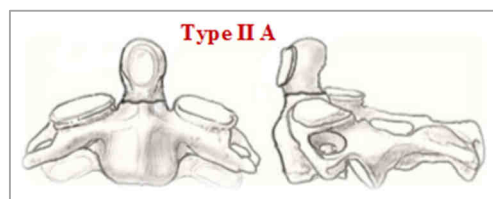
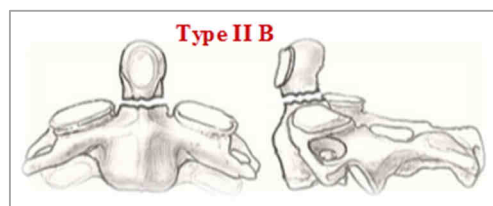


Figure 7 - Type IIA odontoid

In order to address the second limitation of the Anderson and D'Alonzo classification, in 2005 Grauer further classified types II and III, highlighting the fact that in type II fractures the superior facet joints of the axis are not interested, while in type III fractures they are affected. He also classified type II fractures into three subtypes: type IIA was defined as a transversal line of fracture, with no comminution and a displacement of the dens < 1mm; type IIB was a displaced fracture extending from anterior-superior to posterior-inferior, or a transverse fracture with a displacement > 1mm; type IIC was a fracture extending from anterior-inferior to posterior superior or a fracture with significant comminution (Figure 8) (2,5).

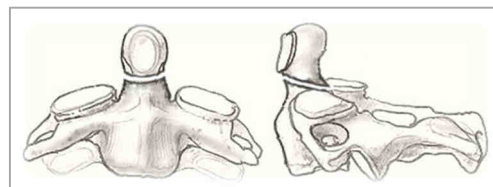


no comminution and displacement of dens < 1mm



transverse fracture with displacement of dens > 1 mm

or



displaced fracture extending from antero-superior to postero-inferior

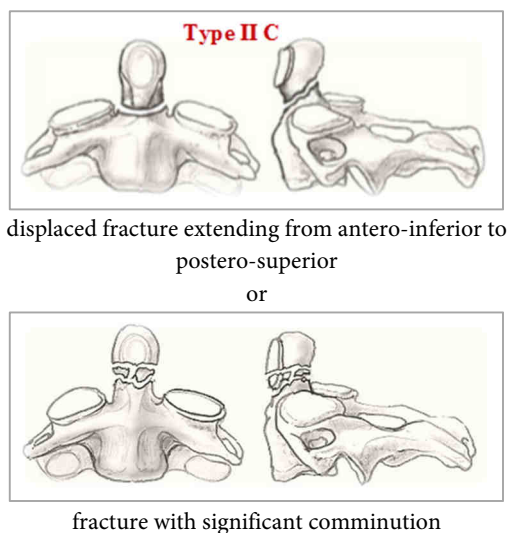


Figure 8 - The Grauer modifications of type II fractures

In 2006, Jea described type III A as a horizontal fracture through the body of C2 extending into the C1–C2 facet joints (6).

In the presented case, the fracture line passes at the base of the odontoid process and it descends on one side only, separating the body of the axis of the lateral mass. This fracture cannot be framed in the aforementioned classifications because:

- it is not a simple transverse fracture at the base of the odontoid process to be considered type II fracture (Anderson and D'Alonzo);
- it is not accompanied by comminution to be considered type II A fracture (Hadley);
- it does not pass through both superior articular facets (in fact, none of the facets are interested) to be classified as type III fracture (Grauer);
- on the coronal section, it does not affect the body of the axis on both sides for it to be classified as type III fracture (Anderson and

D'Alonzo);

- the transversal fracture continues on only one side, separating the body of the axis and the lateral mass, so it cannot be considered type II A fracture (Grauer);

- it does not have an oblique trajectory through the dens to be considered type II B or C (Grauer);

In Roy – Camille classification, the level of the odontoid fracture trajectory is not specified (8).

None of the described fracture types include the body of C2, pedicle (as in the presented case) or lateral mass.

Also, we can affirm that the presented fracture trajectory cannot be framed in any of the fracture types proposed by Levine–Edwards classification (7).

We can conclude that the described fracture is rarely seen, not found in cases that we treated and also not described in the literature.

Conclusions

The presented case shows a new subtype of odontoid fracture, undefined using the aforementioned classifications. We name this type II B odontoid fracture, for which an external immobilization was the treatment of choice.

References

1. Anderson LD, D'Alonzo RT: Fractures of the odontoid process of the axis. *The Journal of Bone and Joint Surgery* 1974; 56(8): 1663 – 1674.
2. Grauer JN., Shafi B., Hilibrand AS., et al.: Proposal of a modified, treatment-oriented classification of odontoid fractures. *Spine Journal* 2005; 5(2): 123 – 129.
3. Hadley MN, Browner C, Sonntag VKH: Axis fractures:

a comprehensive review of management and treatment in 107 cases. *Neurosurgery* 1985; 17: 281 – 290.

4.Hadley MN, Browner C, Liu SS, Sonntag VKH: New subtype of acute odontoid fractures (type IIA). *Neurosurgery* 1988; 22: 67 – 71.

5.Jaiswal AK., Sharma MS., Behari S., et al.: Current management of odontoid fractures. *Indian Journal of Neurotrauma* 2005; 2(1): 3 – 6.

6.Jea A., Levi AD.: Vertically unstable type III odontoid fractures: case report. *Neurosurgery* 2006; 59 (5): E1152.

7.Levine AM, Edwards CC: The management of

traumatic spondylolisthesis of the axis. *J Bone Joint Surg Am.* 1985; 67(2): 217 – 226.

8.Roy-Camille R, Saillant G, Judet T et-al. Factors of severity in the fractures of the odontoid process (author's transl). *Rev Chir Orthop Reparatrice Appar Mot.* 1981;66 (3): 183-6. Pubmed citation.

9.Pal D., Sell P., Grevitt M.: Type II odontoid fractures in the elderly: an evidence-based narrative review of management. *European Spine Journal* 2011; 20(2): 195–204.