

## **A rare type of tumor: orbital schwannoma. Case report and literature review**

**R.M. Gorgan, Angela Neacsu, Silvia Mara Baez Rodriguez, G. Popescu, Catioara Cristescu, A. Giovani**

Clinic of Neurosurgery, "Bagdasar – Arseni" Emergency Clinical Hospital, "Carol Davila" University of Medicine and Pharmacy, Bucharest

**Abstract:** Schwannomas arise in the cells responsible for the myelinating the neurons distal to the Obersteiner-Redlich zone. Most of the intracranial Schwannomas are in the posterior fossa, developed from the VIII<sup>th</sup> or V<sup>th</sup> nerve sheath. The location on other cranial nerves is quite rare, only 6% of the orbital tumors being Schwannomas. We review the case of a 52 years old male patient, presenting for right eye exophthalmia and visual field deficit, diplopia due to VI<sup>th</sup> nerve paresis, and stabbing pain in the right eye, the MRI showing a tumor, located in the orbital apex displaced the globe forward and superiorly, and the optic nerve medially and superiorly. A modified lateral orbital approach was preferred. The choice of the orbitotomy allowed us to maintain the integrity of the lateral rim of the orbit without the need of a bony reconstruction at the end of the intervention, as it faced the anterior margin of the temporal muscle, covering it and not the skin over the zygomatic bone. The technical approach for orbital schwannomas should be tailored to reach the lesion through an esthetic incision and orbitotomy, immediately under the resected bone, with no need retracting the ocular globe or the vasculonervous elements in the orbit.

**Key words:** Schwannoma; lateral orbital approach

### **Introduction**

Schwannomas arise in the cells responsible for the myelinating the neurons distal to the Obersteiner-Redlich zone. Most of the intracranial Schwannomas are in the posterior fossa, developed from the VIII<sup>th</sup> or V<sup>th</sup> nerve sheath. The location on other cranial nerves is quite rare, only 6% of the

orbital tumors being Schwannomas. These tumors become symptomatic through the mass effect and usually the symptoms progress slowly over a few years mirroring the slow rate of growth.

In a large series of 308 orbital tumors published in 1984 by J. Maroon, the authors counted only 5 neurofibromas, the most often encountered orbital tumors being in order

metastasis, dermoid tumors, meningiomas and cavernomas.

Most patients with orbital tumors present with slowly progressive proptosis. A partial field cut, Blurred vision and Diplopia and papillary edema with or without optic atrophy can also be present though less frequent.

Differential diagnosis with other tumors or tumor like lesions should be obtained. The most common possible lesions resembling neurinomas are meningiomas, cavernomas and dermoid tumors, each presenting characteristic features on MRI which should be sought with attention.

The relation of the tumor with the optic nerve and the oculomotor muscles must be understood from the MRI images before proceeding to resection.

The tumor may be inside or outside the muscles cone, in the orbital apex or more excentrically situated. It may encircle the optic nerve or just displace it. The relation of the tumor with the orbit walls is very important in choosing the approach as the shortest way with the minimal risk of collateral damage should be chosen. In 1941 Dandy introduced the subfrontal approach and Nafzinger used the pterional Transcranial approach for orbital tumors.

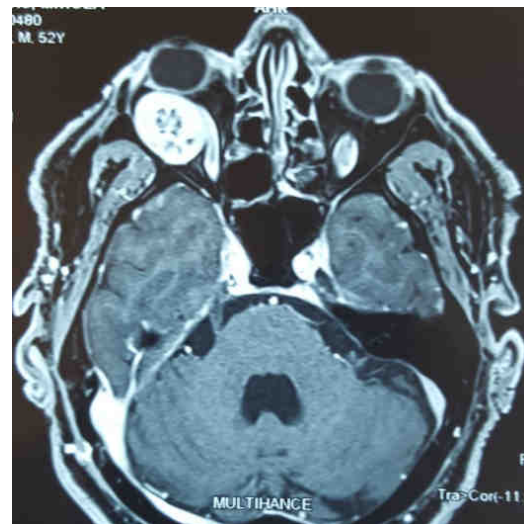
Over time with the tendency towards minimal invasiveness the extracranial approaches became more and more favored to Transcranial approaches. These include lateral orbitotomy for tumors located lateral and basal to the optic nerve and in the orbital apex, transetmoidal for the extraconal tumors located medial to the, transmaxillary for basal

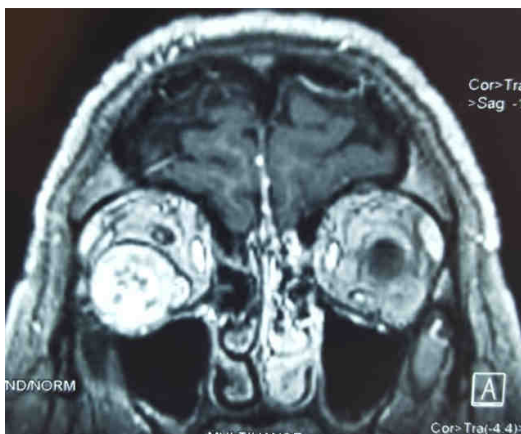
lesions sitting on the maxillary sinus, or transconjunctival for basal intraconal tumors.

The transcranial approaches remain in use nowadays for tumors developed both intracranial and intraorbital or for Tumors involving the optic canal.

#### Case report

We review the case of a 52 years old male patient, presenting for right eye exophthalmia and visual field deficit, diplopia due to VI<sup>th</sup> nerve paresis, and stabbing pain in the right eye. These symptoms evolved progressively during a few years. No signs and symptoms of Recklinghausen disease were recognized. MRI scan performed on admission showed a large inhomogeneous orbital tumor with central round areas of hypo intensity in both T1 and T2 and peripheral Gadolinium enhancement. The tumor, located in the orbital apex displaced the globe forward and superiorly, and the optic nerve medially and superiorly.



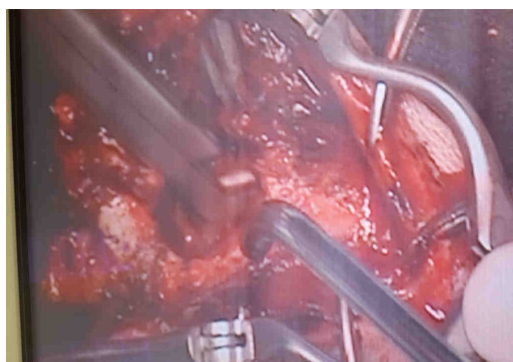


**Figure 1** - Preop MRI showing a mix signal inferolateral orbital tumor that displaces superolaterally the optic nerve

We preferred a modified lateral orbital approach. Using an s shaped incision starting in the eyebrow and continued over the zygoma, we retracted the temporal muscle posteriorly and used a burr hole medial to the frontal process of the zygoma in the angle between the lateral and the inferior orbital walls. As this burr hole was performed over the tumor, only little enlargement of it with rongeurs was needed to mobilize the lesion circumferentially. Using a small dissector, an extracapsular resection was performed detaching the tumor from the right lateral muscle displaced superiorly and from the optic nerve, displaced superomedially. The tumor was encapsulated, of a firm consistency and a pale white color. Fortunately it was not attached to the surrounding structures and the capsule was easily dissected using a blunt instrument followed by a single piece excision of the lesion.

The choice of the orbitotomy allowed us to maintain the integrity of the lateral rim of the orbit without the need of a bony

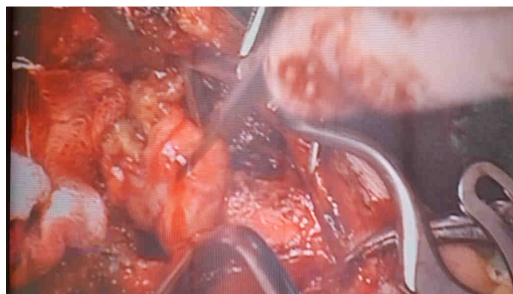reconstruction at the end of the intervention, as it faced the anterior margin of the temporal muscle, covering it and not the skin over the zygomatic bone.



**Figure 2** - Enlarging the lateral orbital wall orbitotomy with a rongeur



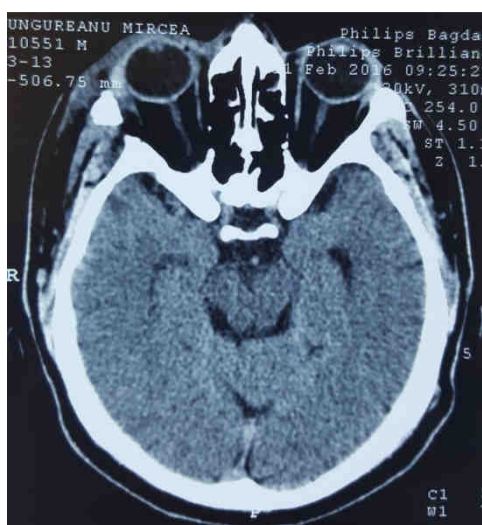
**Figure 3** - Extracapsular dissection of the tumor with a blunt instrument



**Figure 4** - Total resection in a single piece

Following an intradermal suture an ointment dressing was applied on the operated eye.

The postoperative course was uneventful, the exophthalmos resolved almost completely as demonstrated on the postop. CT. and the visual field deficit improved.



**Figure 5** - Postop CT showing complete tumor resection and lack of exophthalmos

## Discussion

The pathology diagnosis came much as a surprise as we expected a more frequent type of tumor like a metastasis, a meningioma or even a cavernoma yet the initial diagnosis was confirmed by the classic palisading pattern of tumor nuclei showed both on Hematoxylin-eosine and S100 stain at the final exam.

Most of the orbital Schwannomas develop from branches of the ophthalmic division of the trigeminal nerve thus being located superior and laterally or superior and medially to the optic nerve as described in an 18 years

span study on 49 orbital Schwannomas. The inferolateral location of the presented Schwannoma indicates the abducens nerve as the site of origin.

As the optic nerve is myelinated in a central like fashion from oligodendrocytes and not from schwann cells, it has been hypothesized that they arise from the sympathetic plexus innervating the vessels feeding the optic nerve. (9, 10, 13)

We described a modified Krohline approach with incomplete resection of the frontozigomatic arcade and an orbitotomy in the angle between the lateral and the inferior wall of the orbit after a good Posterior retraction of the temporalis muscle. A classic lateral orbital approach would have been centered not on the tumor but on the superiorly displaced lateral rectus muscle. (2, 5, 6)

Most of the extracranial approaches to the orbit are based on the classical lateral orbitotomy described by Kronlein in 1889. Depending on the extension of the orbitotomy the lateral approach can open an extended though narrow surgical corridor from the lateral orbit to the superior orbital fissure, the optic canal and the cavernous sinus. (11, 12, 14) Since the use of the CT scan and MRI this tumors are diagnosed while they are confined to the orbit compared to the past when most of the orbital tumors presented an intracranial extension, henceforth the need for a transcranial approach either subfrontal preferred by Dandy or pterional preferred by Nafzinger. (3, 7, 8)

The relation of the tumor with the optic nerve is the main thing to decide the approach

as one should avoid an approach that crosses the ON in its way to the tumor. In the presented case the tumor was behind the globe, under and lateral to the optic nerve.

In 1993 a neurosurgical-ophthalmological team from Duisburg described a transconjunctival approach for an intraconal orbitobasal large cavernoma. This technique allows tumor resection without bone or muscle resection.

A transconjunctival approach could be taken into consideration in our case had the tumor been larger and bulging anteriorly from under the globe.

The superior transcranial, transorbital roof approach and the endoscopic transtentorial approach were not considered at all as the tumor was inferior and lateral to the optic nerve. As the tumor was intraconal with no intracranial or cavernous sinus extension there was no need for a transcranial approach. (1, 4)

Another combined approach with the help of an ENT surgeon is the transmaxillary one, well suited for our case as the tumor was seated on the roof of the maxillary sinus.

#### Conclusion

Even if very rare, orbital Schwannomas are well encapsulated tumors, which makes the resection simple and safe. The technical approach used should be tailored to reach the lesion through an esthetic incision and orbitotomy, immediately under the resected bone, with no need retracting the ocular globe or the vasculonervous elements in the orbit.

#### References

1. Abuzayed B, Tanriover N, Gazioglu N, Eraslan BS, Akar Z: Endoscopic endonasal approach to the orbital apex and medial orbital wall: anatomic study and clinical applications. *J Craniofac Surg.* 2009; 20:1594-1600.
2. Al-Mefty O, Anand VK. Zygomatic approach to skull-base lesion. *J Neurosurg.* 1990;73(5):668-673.
3. Arai H, Sato K, Katsuta T, Rhoton AL Jr. Lateral approach to intraorbital lesions: anatomic and surgical considerations. *Neurosurgery.* 1996;39(6):1157-1162; discussion 1162-1163.
4. Cappabianca P, Cavallo LM, de Divitiis E: Endoscopic endonasal transsphenoidal surgery. *Neurosurgery* 55:933-941, 2004
5. Ducic Y: Orbitozygomatic resection of meningiomas of the orbit. *Laryngoscope* 114:164-170, 2004
6. Fujitsu K, Kuwabara T. Zygomatic approach for lesions in the interpeduncular cistern. *J Neurosurg.* 1985;62(3):340-343.
7. Hakuba A, Tanaka K, Suzuki T, Nishimura S. A combined orbitozygomatic infratemporal epidural and subdural approach for lesions involving the entire cavernous sinus. *J Neurosurg.* 1989;71(5 pt 1):699-704.
8. Maroon JC, Kennerdell JS. Surgical approaches to the orbit. Indications and techniques. *J Neurosurg.* 1984;60(6):1226-1235.
9. Nakayama K: Studies on the myelination of the human optic nerve. *Jpn J Ophthalmol.* 1967, 11:18-26.
10. Natori Y, Rhoton AL Jr. Microsurgical anatomy of the superior orbital fissure. *Neurosurgery.* 1995;36(4):762-775.
11. Natori Y, Rhoton AL Jr. Transcranial approach to the orbit: microsurgical anatomy. *J Neurosurg.* 1994;81(1):78-86.
12. Paluzzi A, Gardner PA, Fernandez-Miranda JC, et al. "Round-the-clock" surgical access to the orbit. *J Neurol Surg B Skull Base.* 2015;76(1):12-24.
13. Pushker N, Khurana S, Kashyap S, Sen S, Shrey D, Meel R, Chawla B, Bajaj MS: Orbital schwannoma: a clinicopathologic study. *Int Ophthalmol.* 2014, 1-6. Accessed: 4/10/2015:
14. Sekhar LN, Schramm VL Jr, Jones NF. Subtemporal-preauricular infratemporal fossa approach to large lateral and posterior cranial base neoplasms. *J Neurosurg.* 1987;67(4):488-499.