

Extensive spinal epidural abscess complicated with hydrocephalus

Corneliu Balan, Ovidiu Carp, Corina Iordache

Department of Neurosurgery, Emergency Clinical County Hospital, Constanta

Abstract: Spinal epidural abscess is a rare but severe infection requiring prompt recognition in order to have a favorable outcome and appropriate treatment, mainly surgical. We present one of the largest extensions of such abscess in literature, involving the whole spine. No surgical treatment was tempted due to the involvement of 19 levels but antibiotics. The evolution of the lesion was complicated with hydrocephalus, by mechanism of cervical block of CSF flow, and needed first external derivation and later ventriculo-peritoneal drainage.

Introduction

Spinal epidural abscess (SEA) is a relatively rare pathology with an incidence of 1-2 cases per 10000 hospital admissions, however on the rise in the latest 10 years. Classic teaching has generally maintained that SEA represents a neurosurgical emergency, in which early diagnosis and urgent intervention are critical to prevent a neurologic catastrophe. However, over the past decade, there is a trend toward nonoperative management of SEA in carefully selected patients with good outcomes.

We present such a patient with an extensive SEA involving the whole spine, treated with antibiotics due to poor general condition and extension of the lesion, complicated with hydrocephalus which required a ventriculo-peritoneal drainage and good vital and functional results.

Case presentation

Mrs. G. SM, 61 years old, was admitted in the Department of Neurosurgery of the Emergency Clinical County Hospital of Constanta presenting pain irradiated to the whole spine, fever (38.2 C) lasting for two days and slight motor deficit of the lower limbs, mainly on the right side. Non-insulin dependent diabetes mellitus was noticed as comorbid association, improper controlled, usually to 150-180mg/dl. However, on admittance, she presented 300 mg/dl glucose, with WBC = 20.3 k, anemia, ESR = 99 mm/h suggesting an infectious process. Later the same day, on thorough anamnesis from her family, we found that she had received an infiltration with corticoids for her chronic low back pain 10 days ago by a non neurosurgeon colleague.

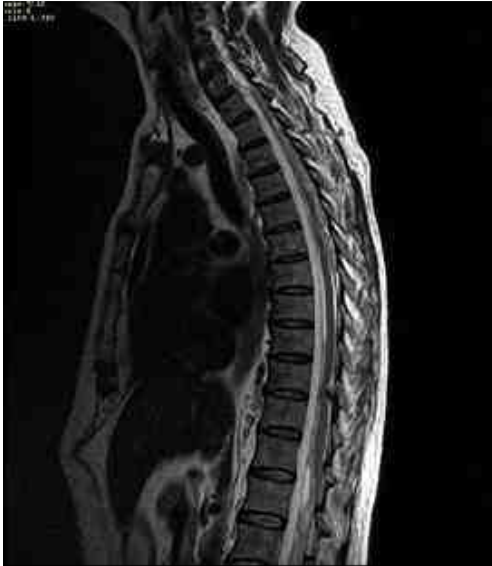

Figure 1

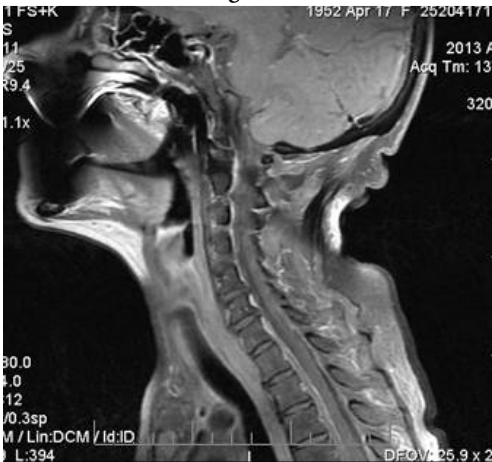

Figure 2

The MRI performed initially for the lumbar segment then for the thoracic and cervical spine presented an epidural mass, located anterior from the dural sac, extending from L5 to C6 level (19 levels), hypo-intense on T1, high intensity in T2 and enhancing peripheral with gadolinium (Figure 1, Figure 2, Figure 3). The same MRI revealed an abscess

situated deep in the lumbar muscles at L4 level, corresponding to the infiltration (Figure 4).

The germ was soon identified from blood cultures and direct puncture under ultrasound control of the paravertebral abscess as a *Staphylococcus aureus* multi-sensible to antibiotics (non MRSA), which confirmed the hypothesis of an inoculation from the skin via the infiltration.

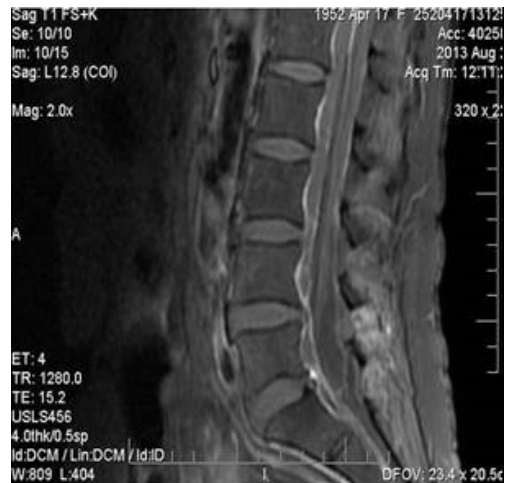

Figure 3

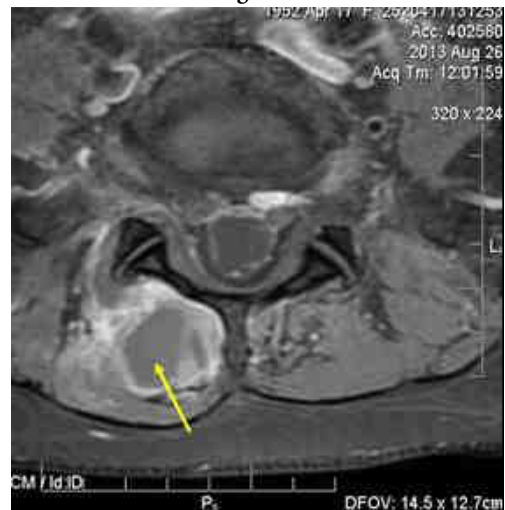


Figure 4

No surgical decision was taken in this case due to the extent of the SEA and the patients' general status, together with the absence of an important motor deficit. She received antibiotics, Ceftriaxone + Cyprofloxacin iv, according to antibiogram, with Insulin to correct the hyperglycemia and she remained for the treatment in the neurosurgical department for better surveillance.

The patient slowly improved clinical and biological for the first 3 weeks, followed later by a sudden alteration of conscience and confusion. We repeated her MRI which surprised us by the augmentation of the volume of the collection in the cervical region (Figure 5), despite proper antibiotics. However, the cerebral CT scan showed signs of active hydrocephalus by mechanisms of impaired flow of the CSF and resorption by cervical block (Figure 6).

Confronted with the clinical deterioration of the patient (GCS 12, WBC = 12k, ESR = 86 mm/h), we tried to gain time with an external derivation of the CSF, despite the high infectious risk. She first improved during the EVD (CSF clear, low opening pressure, 11 elem/mm³) but deteriorated again three days after the removal of the external derivation at 12 days since its introduction.

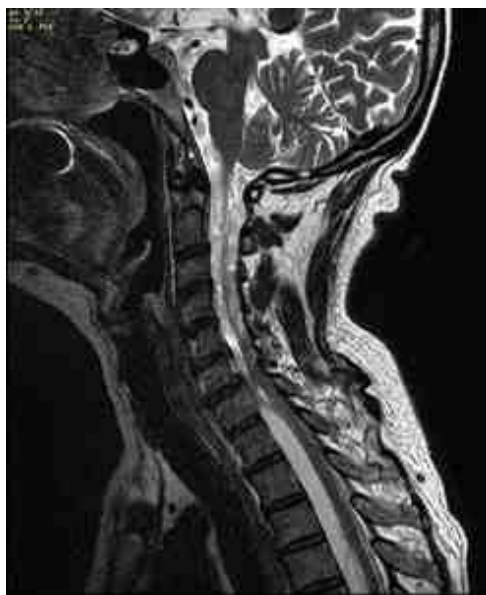

Figure 5

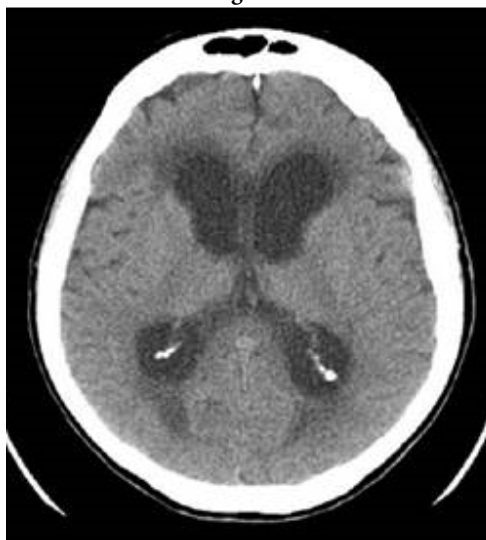


Figure 6

At 6 weeks since the patients admission, after several debates with the neurosurgical /ICU/ infectionists staff and after explaining the risk to the family we decided to perform a ventriculo-peritoneal drainage due to the fact

that the CSF was still sterile and to treat the patient like a potential shunt infection (Meropenem 3 g/d as the patient had 52 kg). The surgical procedure went without complications as a unishunt with larger diameter tube than normally (1.2 mm) for the low pressure hydrocephalus. The patient improved slowly during the following month, both neurological, imagistic and biological, to GCS = 14, with no motor deficit excepting some bladder voiding difficulties which disappeared at the 6 months control). She was then discharged with Bisepitol for 3 weeks at home to a total of 13 weeks of antibiotherapy.

Control MRI realized at 5 months from the onset revealed no collection in the cervical or dorsal region of the spine (Figure 7) and little cicatriceal tissue in the lumbar region (Figure 8). Her cerebral CT scan reveals a functioning drain with no sign of hydrocephalus.

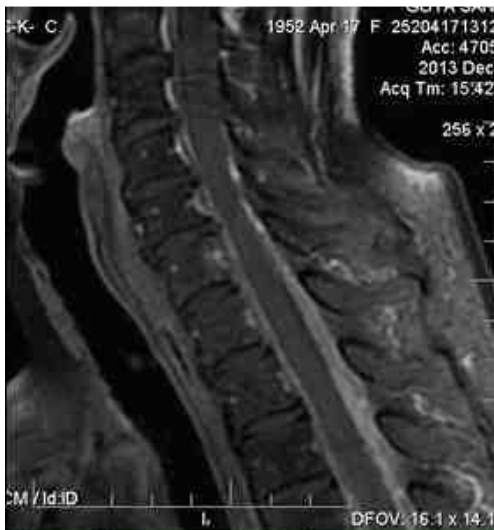

Figure 7

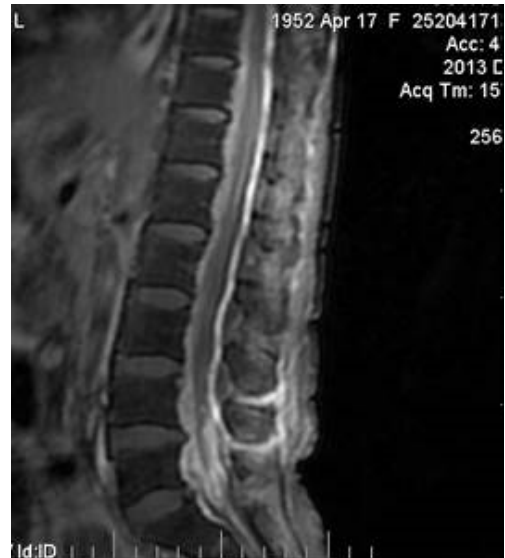

Figure 8

Discussion

Reports of SEA, as a rare but severe infection, have two common threads - poor outcome and appeals for earlier recognition and treatment to avoid this outcome. However, the diagnosis of spinal abscess can be tricky because of its rarity and the insidious presentation, time to a correct treatment being a key factor. The major prognostic factor for a favorable outcome is early diagnosis. [1, 2, 3, 4, 5, 6]

The gold standard treatment, well supported by multiple published reports, consists of prompt surgical debridement and drainage in combination with systemic antibiotic therapy [7, 8, 9]. Final outcomes have been strongly and significantly correlated to both duration of the deficit and severity immediately prior to decompression, with morbidity of 33-46% and up to 22% definitive paralysis, even in 2013 papers [11].

Confronted with such statistics, there are few neurosurgeons who dare to try a conservative approach when surgery is possible and papers who present the results of non-surgical treatment are scarce or against such treatment.

Regarding the case presented, it has the particularities of the inoculation of the germ via infiltration with corticoids, seldom described in literature; even rare are the abscesses extended on such length (2 of 65 cases in the series presented by Velissaris in 2009[12] and none in 77 cases reviewed by Connor in 2013[11]). The onset of hydrocephalus as complication determined by such spinal epidural abscess was not found on Pubmed.

There were several key moments in the treatment of the patient when a risky decision had to be taken:

- after the first diagnosis of SEA: most neurosurgical papers recommend surgical intervention with the evacuation of the purulent collection. We declined this option due to the extension of the SEA which couldn't allow multiple resections, the fact that staphylococccic pus is dense and not fluid to allow multiple level fenestrations for evacuation and the patient's still good neurological status despite poor control of the diabetes. We preferred to keep the patient in a neurosurgical department (although with a long hospitalization) and not infectious diseases for better clinical surveillance in such patient.

- after the diagnosis of hydrocephalus – a trial with Acetazolamide was initiated for a few days to lower the production of CSF but the patient deteriorated and necessitated an EVD.

Once again the infectious risk was high in a diabetic patient with a purulent collection and intraventricular implant.

- after removing the first EVD – there was a choice between a second EVD contralateral and a permanent VP drainage. Our option was for the last, assuming it would better control the hydrocephalus and allow a quicker recovery than those of a patient connected to a temporary EVD, immobilized in bed.

Conclusion

Spinal subdural abscess is a very rare but well described entity and associated with high morbidity and mortality. It is a neurosurgical emergency and as soon as diagnosis is established surgical treatment in collaboration to antibiotic therapy should be performed. The risks taken in our case proved worthy of the results, however, whenever an SEA was admitted again in our neurosurgical department we would prefer the gold surgical standard than to wait and see for 3 months with medical treatment and all the complications which could happen. Medical management of SEA remains just for very selected cases, with no/slight neurological deficit, when anasthetical and surgical risks are too high to be assumed.

References

1. Darouiche RO : Spinal epidural abscess. *N Engl J Med* 355: 2012–2020, 2006
2. Pereira CE, Lynch JC . Spinal epidural abscess: An analysis of 24 cases. *Surg Neurol* 63 [Suppl 1]: S26–S29, 2005
3. Kumar K, Hunter G : Spinal epidural abscess. *Neurocrit Care* 2: 245–251, 2005

4. Sendi P, Bregenzer T, Zimmerli W: Spinal epidural abscess in clinical practice. *QJM* 101: 1–12, 2008
5. Tunkel AR. Subdural empyema, epidural abscess, and suppurative intracranial thrombophlebitis. In: Mandell GL, Bennett JE, Dolin R, eds. *Principles and Practice of Infectious Diseases*. 7th ed. Philadelphia, Pa: Elsevier Churchill Livingstone; 2009:chap 89.
6. Rigamonti D, Liem L, Sampath P, et al. Spinal epidural abscess: contemporary trends in etiology, evaluation, and management. *Surg Neurol*. Aug 1999;52(2):189-96
7. Joshi SM, Hatfield RH, Martin J, Taylor W. Spinal epidural abscess: a diagnostic challenge. *Br J Neurosurg*. Apr 2003;17(2):160-3
8. Davis DP, Salazar A, Chan TC, Vilke GM. Prospective evaluation of a clinical decision guideline to diagnose spinal epidural abscess in patients who present to the emergency department with spine pain. *J Neurosurg Spine*. Jun 2011;14(6):765-770
9. Hooten WM, Kinney MO, Huntoon MA. Epidural abscess and meningitis after epidural corticosteroid injection. *Mayo Clin Proc*. May 2004;79(5):682-6
10. P Harrington, P A Millner, D Veale - Inappropriate medical management of spinal epidural abscess, *Ann Rheum Dis* 2001;60:218–222
11. David E. Connor Jr, Prashant Chittiboyna, Gloria Caldito, Anil Nanda - Comparison of operative and nonoperative management of spinal epidural abscess: a retrospective review of clinical and laboratory predictors of neurological outcome, *J Neurosurg Spine* 19:119–127, 2013
12. Dimitris Velissaris, Diamanto Aretha*, Fotini Fligou - Spinal Subdural Staphylococcus Aureus Abscess: case report and review of the literature, *World Journal of Emergency Surgery* 2009, 4:31